

## Technical Note

# Arthroscopic Bone Grafting of Anterior Cruciate Ligament and Posterior Cruciate Ligament Tibial and Femoral Tunnels as a First-Stage Procedure

Evan P. Shoemaker, B.A., Luke V. Tollefson, B.S., Nathan J. Jacobson, M.D., Erik L. Slette, M.D., and Robert F. LaPrade, M.D., Ph.D.

**Abstract:** Recurrent multiligament knee injuries present unique challenges when performing revision ligament reconstructions. Bone tunnel widening is relatively common and considered a multifactorial condition that involves both biomechanical and biologic factors. When indicated, two-stage procedures ensure optimal revision reconstruction tunnel sizes and locations before ligament reconstruction and promote improved outcomes. Staged bone grafting is required when addressing significant tunnel widening and improper tunnel placement that puts graft incorporation at increased risk in ligament reconstructions of the knee. In this Technical Note, we describe the first stage of a two-stage procedure to address meniscus/chondral conditions, tunnel osteolysis from previous reconstructions, and tibial and femoral bone grafting for the anterior cruciate ligament and posterior cruciate ligament.

When presented with a failed multiligament knee reconstruction, it is essential to understand and optimize the outcomes for the revision reconstruction. This includes understanding the mechanisms of previous failures, current limitations, and potential obstacles that must be mitigated to promote long-term procedural success. Tunnel widening from osteolysis can contribute to anterior cruciate ligament (ACL) and posterior cruciate ligament (PCL) reconstruction failure through compromised graft fixation as a result of osteodegenerative changes.<sup>1</sup> Malpositioning is a known contributor to the osteolytic defects of graft tunnels during primary reconstructions.<sup>2</sup>

Tunnel osteolysis, or bone tunnel widening, is a multifactorial condition that is believed to have both biomechanical and biologic factors.<sup>3</sup> It is hypothesized that biologic factors can result from an immune response to foreign allograft tissue, aggravated inflammation from

bioabsorbable fixation, and excessive synovial fluid retention. Biomechanically related issues result from nonanatomic tunnel position, causing increased stress on the reconstruction graft, pre-emptive aggressive rehabilitation resulting in graft elongation, and drill-related osteonecrosis.<sup>4</sup> Osteolytic changes in the tunnels initiate within the first 6 weeks to 3 months postoperatively.<sup>5</sup> The incidence of tunnel widening can vary, and reports range from 25% to 100% and 29% to 100% in both tibial and femoral tunnels, respectively.<sup>5</sup> With variability in tunnel size and bone quality, addressing these issues in a one- or two-stage procedure is crucial to avoid increased rates of revision reconstruction failure.<sup>6</sup> Indications for a two-stage revision procedure are listed in Table 1. This Technical Note describes the first stage of a two-stage procedure to address meniscus/chondral conditions and bone grafting for tunnel osteolysis of the tibial and femoral tunnels from ACL and PCL reconstruction graft failures.

From the Twin Cities Orthopedics, Edina, Minnesota, U.S.A.

Received April 25, 2024; accepted June 30, 2024.

Address correspondence to Robert F. LaPrade, M.D., Ph.D., Complex Knee Surgeon, Twin Cities Orthopedics, 4010 W. 65th St., Edina, Minnesota, 55435, U.S.A. E-mail: [laprademdphd@gmail.com](mailto:laprademdphd@gmail.com)

© 2024 THE AUTHORS. Published by Elsevier Inc. on behalf of the Arthroscopy Association of North America. This is an open access article under the CC BY-NC-ND license (<http://creativecommons.org/licenses/by-nc-nd/4.0/>).

2212-6287/24692

<https://doi.org/10.1016/j.eats.2024.103201>

## Surgical Technique

A detailed video of the assessment, debridement, and tunnel preparation with bone grafting is shown in Video 1. The step-by-step guide and surgical pearls are included in Table 2.

## Patient Evaluation

Patients who are suspected of having multiligament knee reconstruction failure are evaluated using

**Table 1.** Indications for Two-Stage Revision Ligament Reconstruction

1. Previous reconstruction graft failure
2. Significant tunnel osteolysis (widening)
3. Nonanatomic tunnel positioning that would overlap with an anatomic placed tunnel
4. Significant coronal (varus/valgus) or sagittal (posterior tibial slope) malalignment

radiographs, magnetic resonance imaging, and computed tomography (CT). Long-leg radiographs are used to determine coronal alignment (Fig 1), lateral radiographs are used to determine sagittal alignment, and appropriate stress radiographs are used to assess ligament stability (Figs 2 and 3). If significant coronal or sagittal malalignment is present, a corrective osteotomy can be performed concomitantly with the bone grafting procedure. Magnetic resonance imaging is used to determine the extent of the injury, including grafts affected, new ligaments affected, meniscus injuries, and chondral injuries. A CT scan is used to determine the position and size of the tibial and femoral tunnels from the previous failed reconstructions (Figs 4 and 5).

### Anesthesia and Positioning

The patient is placed in the supine position on the operating table and induced under general anesthesia. An examination under anesthesia is performed to

confirm the clinical examination. A high thigh tourniquet is placed on the surgical leg. The surgical leg is placed in an extremity holder (Mizho OSI, Union City, CA) and the contralateral leg is placed into an abduction stirrup (Birkova Product LLC, Gothenburg, NE). The patient's lower extremity is prepped and draped in the usual sterile manner. The patient is given perioperative cefazolin for prophylaxis against infection.

### External Hardware Removal

The previous external hardware from the ACL and PCL reconstructions are removed. The external fixation for the ACL can include a staple, screw, or post and washer, a staple on the tibia and a screw or button on the femur (Fig 6). The external fixation for the PCL can include a post and washer on the tibia and a button on the femur.

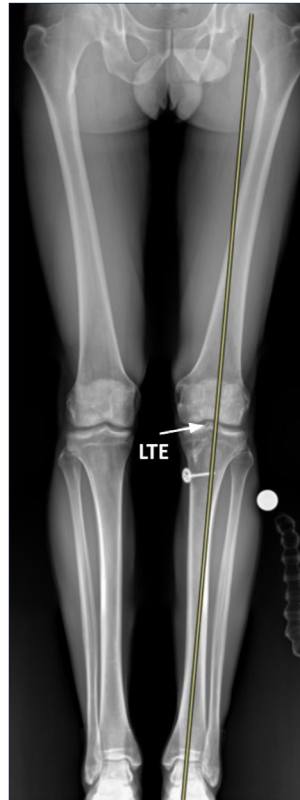### Arthroscopy

Medial and lateral arthroscopic parapatellar portals are made. The camera is inserted into the joint, and the joint is insufflated with normal saline. An assessment of the suprapatellar pouch and both medial and lateral gutters is made. Assessment of the anterior compartment follows. A lysis of adhesions is performed to restore the contour of the suprapatellar pouch and improve patellar mobility. If any patellar chondromalacia is present, perform a chondroplasty to

**Table 2.** Step-by-Step Guide and Surgical Pearls for Arthroscopic Bone Grafting of Anterior Cruciate Ligament (ACL) and Posterior Cruciate Ligament (PCL) Tibial and Femoral Tunnels in First-Stage Procedure

Step-by-Step Guide	Pearls
Perform preoperative diagnostic assessment with magnetic resonance imaging, radiographic, and computed tomography imaging to determine the extent of injury, bony alignment, previous hardware, and tunnel widening.	Determine whether a one-stage reconstruction is viable; if not, a two-stage procedure is indicated to address tunnel widening first with bone grafting than revision ligament reconstruction in the second stage.
Previous fixation hardware of the ACL and PCL should be removed first.	A rongeur can be used to remove superficial tissue and ossification to isolate the external fixation hardware.
Medial and lateral parapatellar arthroscopic portals are created.	Incisions may be expanded to optimize joint visualization if necessitated.
Chondroplasty and lysis of adhesions are performed in the compartment and suprapatellar pouch.	Significant fissures or flaps of the articular cartilage of the patella and/or condyles should be removed.
The decision to address existing meniscus pathology is made. Ramp and root attachments should be thoroughly probed.	Use of probe to palpate meniscocapsular junction both superior and inferior for ramp lesions. The transnotch approach allows for increased posterior visualization.
The failed reconstruction grafts are debrided.	The trochlear notch should have clear anterior to posterior visualization. Excessive scar tissue and loose bodies should be excised.
The intra-articular tunnels are isolated of superficial tissue and prepped for reaming.	Use shaver, curette, and/or rasp to clear scarred tissue on both the femur and tibia for ACL and PCL insertions.
The femoral and tibial tunnels are isolated, debrided, and prepped for bone grafting.	Intraoperative radiographs should be taken to ensure complete clearance and proper anatomic alignment.
Opteform DBM is thoroughly packed in both the femoral and tibial tunnels.	Use a curette at tunnel apertures to ensure scar tissue is sufficiently packed into intra-articular tunnels.
The deep and superficial tissues are closed with sutures.	The closure of deep tissues prevents hematoma buildup once the tourniquet is let released.

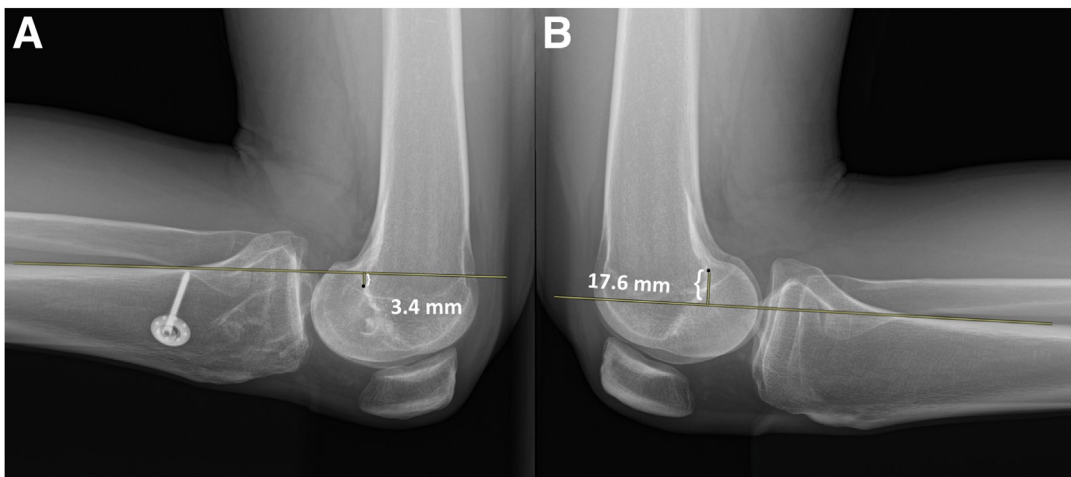
ACL, anterior cruciate ligament; PCL, posterior cruciate ligament.



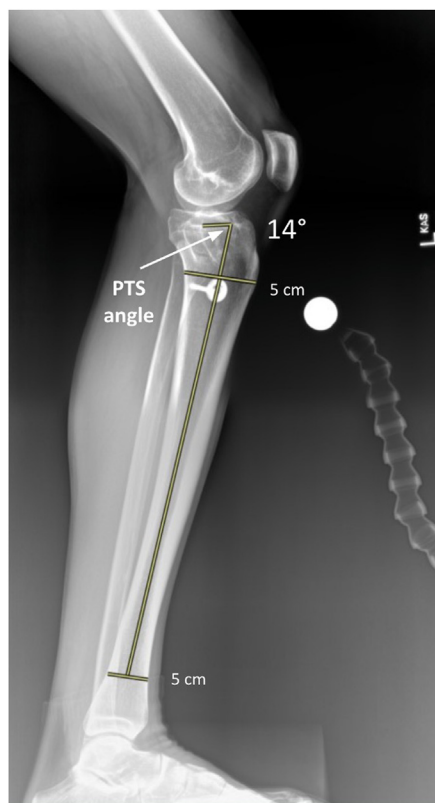
**Fig 1.** Anteroposterior long-leg standing radiograph of the left knee to assess for coronal plane malalignment. A line is drawn from the center of the talus proximally to the center of the femoral head (indicated via a yellow line). Varus alignment is indicated if the line crosses medial to the medial tibial eminence and valgus if it crosses lateral to the lateral tibial eminence (LTE). This radiograph demonstrates the left knee in slight valgus alignment.

remove any lesions and loose bodies. Then, attention is shifted to the assessment in the lateral and medial compartments. A probe is used to palpate both the

meniscotibial and meniscofemoral attachments of the medial meniscus meniscocapsular junction. In combination with diagnostic imaging, tears in the hidden area



**Fig 2.** Bilateral knee posterior cruciate ligament (PCL) kneeling stress radiographs used to objectively assess for posterior tibial translation side-to-side differences. Increased posterior tibial translation in comparison with the contralateral knee may be indicative of injury to the PCL and/or concomitant ligaments in the posterolateral corner. A line is drawn from a point 15 mm distal of the joint line along the posterior tibial cortex proximally through the femoral condyles. A second line is marked perpendicularly from the most posterior aspect of the Blumensaat line, and the distance is recorded for both injured and uninjured knees. Bilateral PCL stress radiographs demonstrate a 21-mm increase in posterior tibial translation of the left knee (A) is indicative of PCL reconstruction graft failure.



**Fig 3.** Posterior tibial slope (PTS) of the left knee on full-length lateral tibial standing radiographs, assessed through the anatomic axis of the tibia. A line is drawn each at the 5 cm distal to the knee joint line and 5 cm proximal from the tibiotalar joint, in between the anterior and posterior tibial cortices. A line is drawn vertically from their midpoint on the sagittal axis. A horizontal line is then made on the lateral tibial plateau and the angle is representative of the tibial slope. The left knee posterior tibial slope is 14 degrees. Increased slope ( $>12^\circ$ ) produces excessive force loading on anterior cruciate ligament grafts and predisposes individuals to recurrent graft failure following reconstruction. Conversely, decreased PTS ( $<6^\circ$ ) puts excessive axial load on the bundles of posterior cruciate ligament reconstruction grafts. A slope range between 7 and  $9^\circ$  provides an optimal environment to combat against excessive tibial translation both posterior and anteriorly and improved overall graft survival rates.

of the medial meniscus are identified, if present. Assessment of meniscal root insertions and intra-articular cartilage follows. The choice to address these pathologies in the primary or secondary stages are made.

### Intra-articular Tunnel Preparation

The failure of the ACL and PCL grafts is confirmed (Fig 7). Proceed to extensively debride both of the femoral tunnels using a series of a curette, rasp, and various sizes of shavers (Fig 8). Take significant time if there is extensive scarring within the tunnels to remove all intra-tunnel soft tissues and residual hardware.

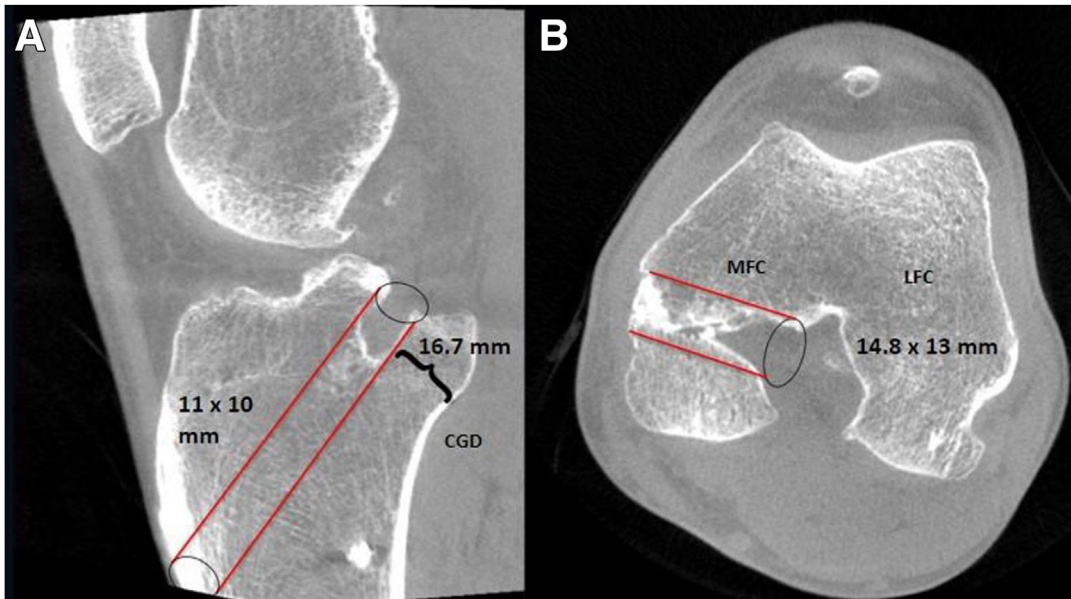
### Tunnel Debridement and Bone Grafting

The location of the tunnels is identified intra-articularly. The femoral tunnels are addressed first to optimize intra-articular visualization without losing fluid; they are then extensively debrided using a rasp, curette, and shavers with visual assistance from the arthroscope in the contralateral parapatellar tunnel

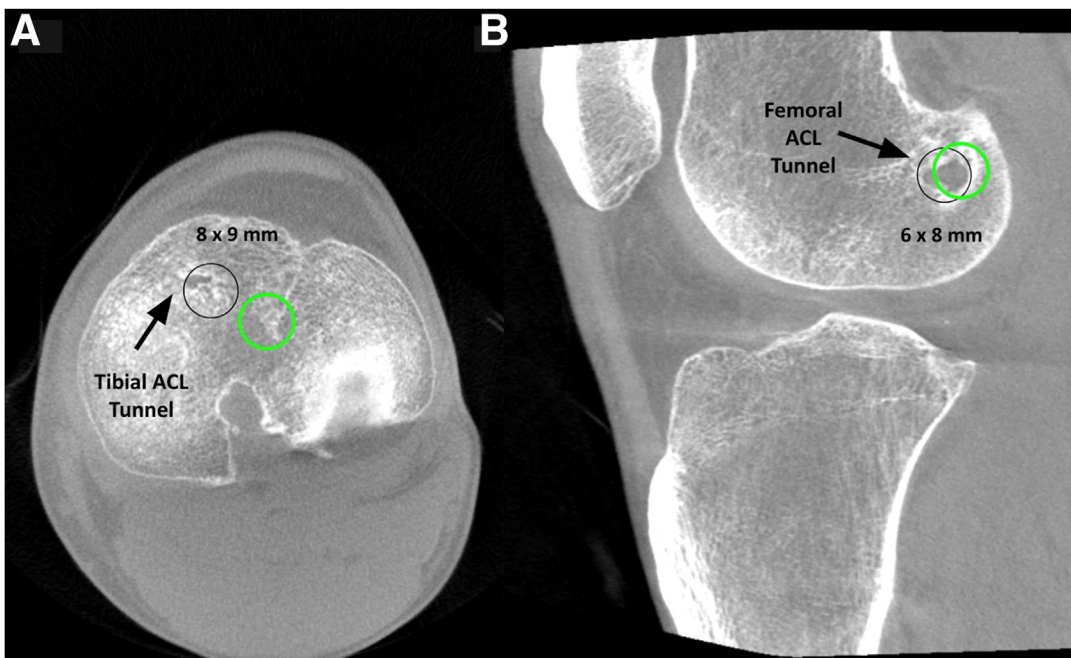
until there are clean bleeding bony margins. A guide pin is then drilled intra-articularly using a tibial guide (Arthrex, Naples, FL) and a Kocher forceps is used to hold the ACL guide pin and a large curette over the PCL tibial tunnel pin and individually reamed over both the ACL and the PCL tibial guide pins. The tunnels are thoroughly cleaned following the reaming and visualized with the arthroscope to validate bleeding margins throughout. Autograft and/or allograft bone may be used with the assistance of a curette to firmly impact the bone graft to fill the debrided tunnels (Figs 9 and 10). The deep tissues and superficial tissues are then closed. A sterile dressing and knee immobilizer are applied in full extension.

### Postoperative Protocol

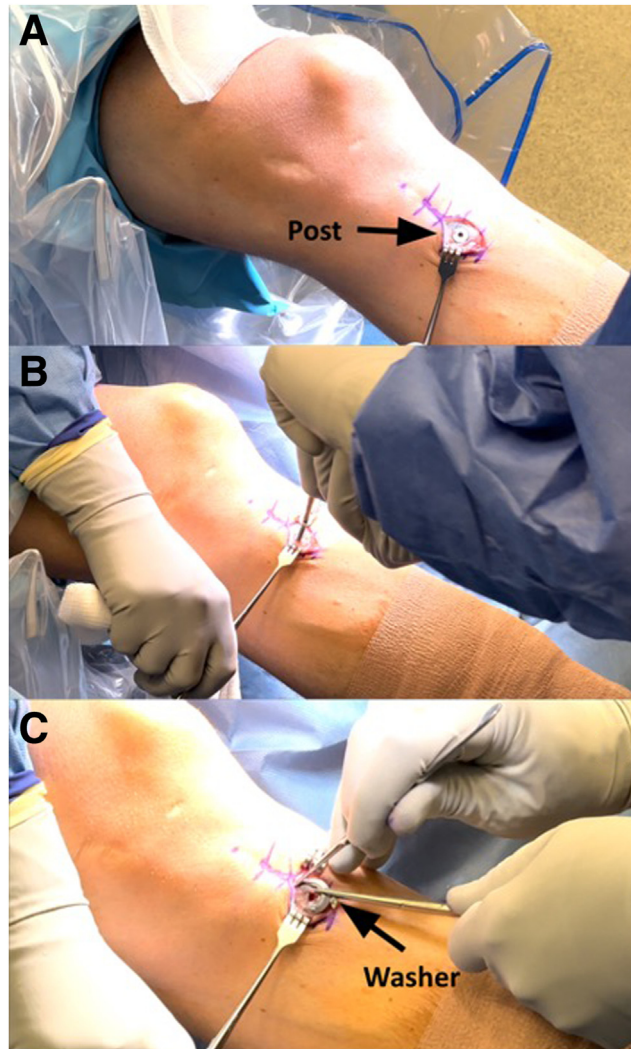
After the procedure, the patient is allowed to weight bear as tolerated but should use crutches for a minimum of 2 weeks. Physical therapy starts day 1 postoperatively with a focus on quadriceps activation, edema control, and knee motion.



**Fig 4.** Computed tomography scan of the left knee demonstrating sagittal (A) and axial (B) views of single-bundle posterior cruciate ligament (PCL) reconstruction tunnels. The alignment of the tibial tunnel sits in a non-anatomical position that over-extends anterior and proximal. At a 45° angle from the mechanical axis, a 1- to 2-mm back wall between the tibial tunnel and the champagne glass drop-off (CGD) should be maintained. The entry diameter of the femoral tunnel measures 14.8 mm. Placement of the femoral PCL tunnels in nonanatomic positions facilitate graft stretching over time and reconstruction graft failure. Placement of this femoral tunnel is too proximal and posterior on the medial femoral condyle (MFC). (LFC, lateral femoral condyle.)



**Fig 5.** Computed tomography scan of the left knee demonstrating axial (A) and sagittal (B) view of anterior cruciate ligament (ACL) tibial and femoral reconstruction tunnel locations and diameters. The anatomic malposition of both tibial and femoral tunnels is demonstrated with current position (black circle) compared with proper anatomic position (green circle). Superior aspect of the tibial bone tunnel measures 8 × 9 mm. The medial inferior entry of the ACL femoral bone tunnel measures 6 × 8 mm.



**Fig 6.** The left knee isolated for operation with the patient in the supine position and removal of retained hardware (post and washer) from the anteromedial tibia from previous failed reconstruction surgery (A). Once isolated and the superficial tissue is resected, the post and washer are removed using a rongeur, screwdriver, and various retractors (B and C). Removal of hardware allows for unimpaird access to the tibial tunnels of previous failed reconstructed grafts.

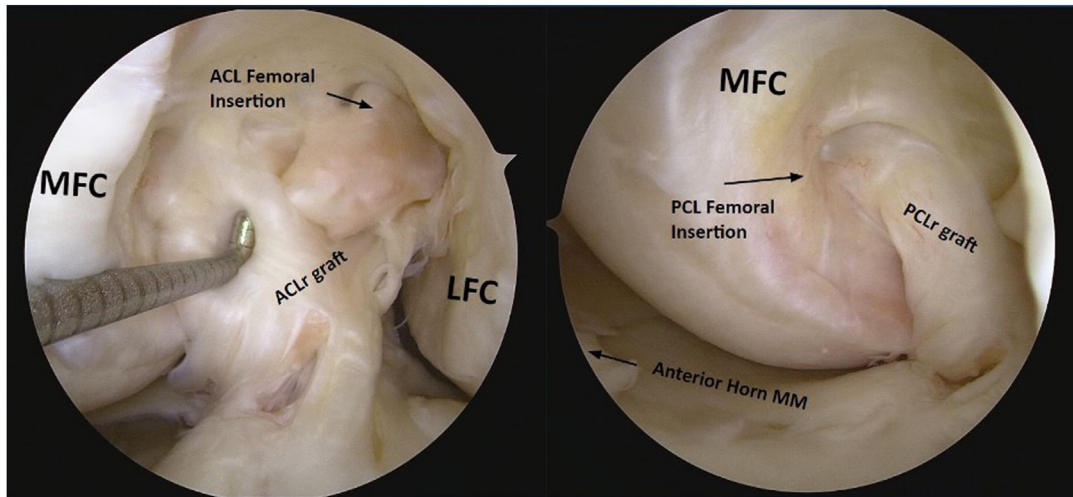
Baseline anteroposterior and lateral radiographs are obtained postoperatively on day 1 following physical therapy. Plain radiographs are obtained 3 months postoperatively to assess bone healing. It is anticipated that bone healing will take 6 months, because of the width of the tibial tunnels, before the second stage revision surgery.

### Discussion

Addressing tunnel widening necessitates CT analysis when planning for revision procedures to assess the original degree of osteoincorporation and tunnel alignment.<sup>7</sup> Biologic incorporation after ligament reconstruction is dependent on the initial fixation technique and location.<sup>8</sup> For ACL grafts, fixation can be established extra-articularly (via cortical fixation devices—femoral loops and tibial cortical fixation) or at the

aperture (via cross pins and interference screws). Tibial tunnel bioabsorbable screw fixation was associated with a greater initial increase in tunnel widening, although it demonstrated the greatest ingrowth change after 5 years.<sup>9</sup> Femoral tunnel widening was less variable and showed a nonsignificant difference between aperture versus extra-articular fixation methods. Confounding variables, including the patient's body mass index, should be considered.<sup>10</sup>

Graft type is an additional consideration for tunnel widening when evaluating the prospective success of the reconstruction. Tunnel widening has been significantly correlated with the use of non-bony grafts (i.e., hamstring tendons).<sup>11</sup> In a systematic review, Bhullar et al.<sup>12</sup> aimed to identify modifiable risk factors for tunnel widening associated with graft choice. Analyzing results from 103 studies, they found that

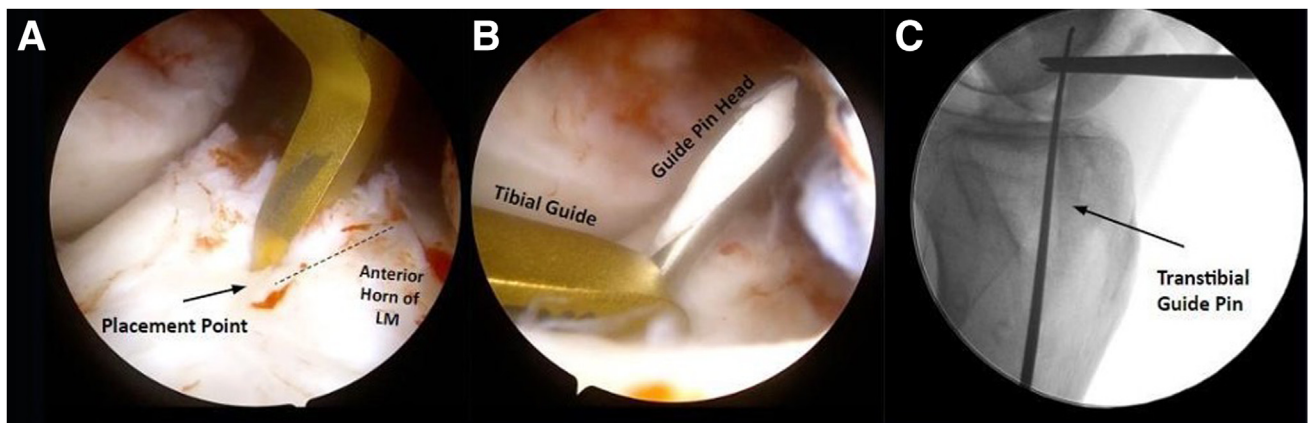


**Fig 7.** Arthroscopic view of the left knee shows, via probing, confirmed failed anterior cruciate ligament reconstruction (ACLR) and posterior cruciate ligament reconstruction (PCLR) grafts. Significant scarring and adhesion encompass the ACLR and PCLR grafts. Current placement of this PCL tunnel is both too proximal and posterior for a single bundle PCLR contributed to graft failure. Palpation with a probe displays significant increase in graft laxity that is consistent with increased posterior tibial translation preoperative stress radiographs and a 3+ Lachman and pivot shift examination. Resection of posterior graft tissues must be completed with heightened awareness to the medial and lateral meniscus roots to avoid further intervention necessitating additional transtibial tunnel drilling. (LFC, lateral femoral condyle; MFC, medial femoral condyle; MM, medial meniscus.)

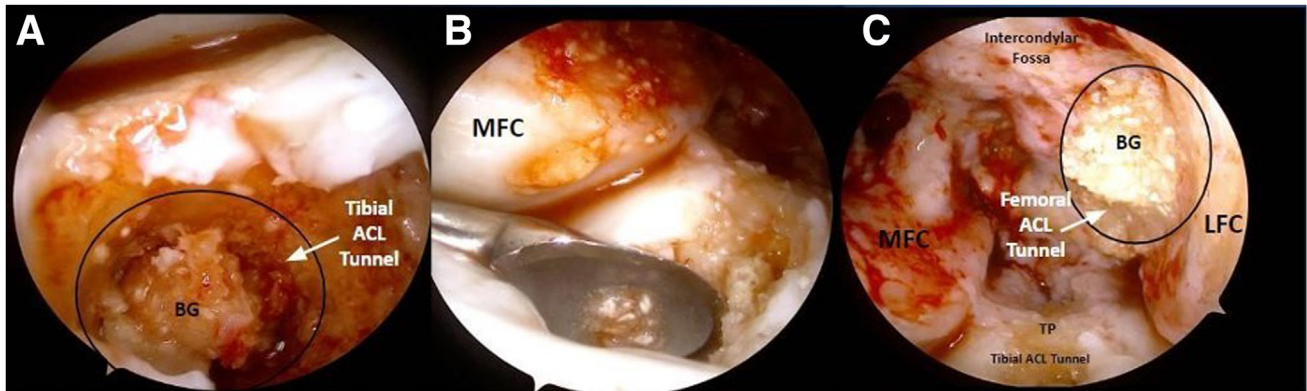
double-bundle hamstring autografts reported lower average tunnel widening than single-bundle hamstring autografts. Bone–patellar tendon–bone autografts reported the lowest average tunnel widening, and bone–patellar tendon–bone allografts had the greatest incidence of tunnel widening.<sup>12</sup> Sauer and Lind<sup>5</sup> hypothesized mechanical and anatomic explanations for the inconsistent incidence of femoral versus tibial tunnel widening. Drill-related bone necrosis may unevenly affect the tibial tunnel, as it is not irrigated with

saline when reamed in contrast to the femoral tunnel. Anatomically, greater bone mineral density within the femoral condyles compared with the proximal tibia could contribute to femoral resistance to tunnel osteolysis.

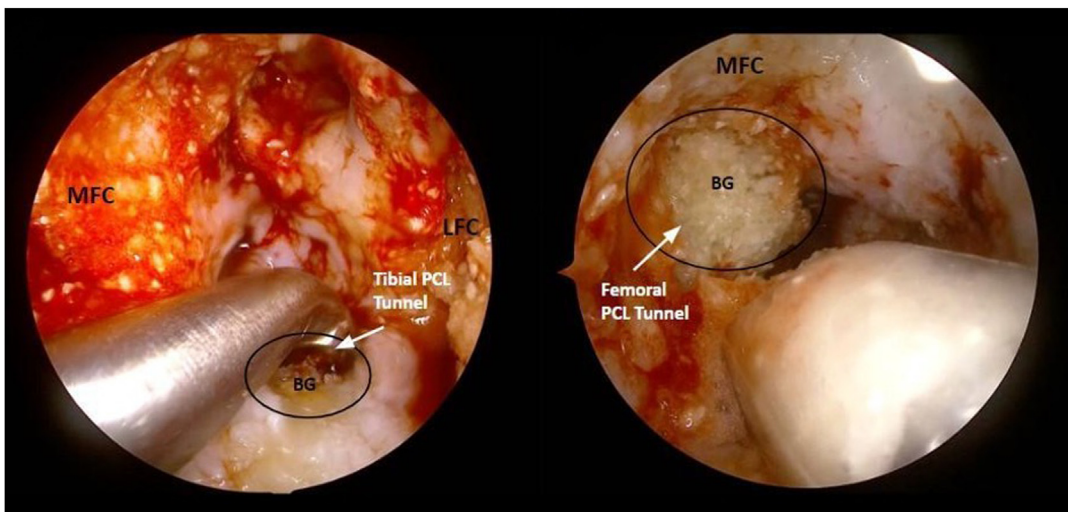
Variability exists in the technique of bone grafting; autologous bone dowels, synthetic bone matrix/chips, and osteochondral allograft transfer systems are used.<sup>13</sup> Autologous mediums are considered the superior option because of their osteogenic properties.<sup>14</sup> Among



**Fig 8.** Arthroscopic view of the left knee shows the tibial guide used to drill the guide pin to correctly position anterior cruciate ligament (ACL) tunnel reaming (B). Intraoperative lateral radiographs of the left knee are obtained to assess the tunnel position (C). Desired location is confirmed in order to effectively remove all osteolysis before bone grafting. Any corrective changes to alignment of tunnels from previous reconstructions are calculated and optimized before reaming. The most accurate landmark to avoid tunnel malpositioning is the native ACL attachments, although this is unavailable for revision reconstructions. In this case, placing the guide medial to the midportion of the anterior insertion of the lateral meniscus (LM) (A).



**Fig 9.** Bone grafting of debrided anterior cruciate ligament (ACL) reconstruction tunnels in the left knee. An Opteform DBM allograft bone graft (BG) was thoroughly packed into both the tibial and femoral tunnels of the left knee. The bone graft is dispensed superiorly through the tibial tunnel until visualized (A). The back end of a curette was used to impact the bone firmly to ensure equal density throughout the tunnel (B). A femoral bone graft is dispensed through a cannula into the lateral femoral tunnel. Protrusion of bone matrix from tunnels is leveled and lateral radiographs are obtained to document baseline position and density of tunnels (C). (LFC, lateral femoral condyle; MFC, medial femoral condyle; TP, tibial plateau.)



**Fig 10.** Bone grafting of debrided posterior cruciate ligament (PCL) reconstruction tunnels in the left knee. Opteform DBM allograft bone graft (BG) was thoroughly packed into both the tibial and femoral tunnels of the left knee. Using a curette prevents excessive protrusion of bone graft matrix into intra articular joint space (A). The bone graft is dispensed through the tibial tunnel until visualized arthroscopically. A femoral bone graft is dispensed through a cannula until impacted and even margins are maintained (B). Protrusion of bone graft matrix from tunnels is leveled. (LFC, lateral femoral condyle; MFC, medial femoral condyle.)

**Table 3.** Advantages and Disadvantages of Bone Grafting of Previous Tibial and Femoral Anterior Cruciate Ligament (ACL) and Posterior Cruciate Ligament (PCL) Reconstruction Tunnels for the First Stage of a Two-Stage Procedure

Advantages	Disadvantages
More precise assessment of anatomic tunnel alignment and previous reconstructive shortcomings	Two-stage procedure amplifies inherent risks of surgical intervention (multiple procedures)
Optimizes potential for biologic healing	Autograft bone is not always viable and readily available in first stage procedure
Ability to address meniscal or chondral pathologies in the first stage	Prolonged time for recovery with physical limitations
	Greater associated cost



the existing literature for bone grafting, there is no standard procedure that provides superior outcomes. However, it is agreed that thorough debridement of tunnels is essential for the promotion of a maximized healing environment.<sup>15</sup>

There are known advantages and disadvantages (listed in Table 3) to performing a two-stage reconstruction surgery. The ability to extend preoperative planning, address meniscal pathology, any osteochondral defects, and remove previous reconstructive hardware components all aid in the prospective success and longevity of the knee joint holistically.

### Disclosures

The authors declare the following financial interests/personal relationships which may be considered as potential competing interests: R.F.L. reports consulting or advisory and funding grants from Ossur; consulting or advisory, funding grants, and travel reimbursement from Smith & Nephew; consulting or advisory with Responsive Arthroscopy; funding grants from the Arthroscopy Association of North America and American Orthopaedic Society for Sports Medicine; speaking and lecture fees from Foundation Medical; and a patent with royalties paid to Ossur. All other authors (E.P.S., L.V.T., N.J.J., E.L.S., R.F.L.) declare that they have no known competing financial interests or personal relationships that could have appeared to influence the work reported in this paper.

### References

1. Ernat JJ, Rakowski DR, Millett PJ. Single-stage anterior cruciate ligament revision reconstruction using an allograft bone dowel for a malpositioned and widened femoral tunnel. *Arthrosc Tech* 2021;10:e1793-e1797.
2. Atsumi S, Hara K, Arai Y, et al. Posteromedial portal technique with bone-patellar tendon-bone graft for inside-out revision of anterior cruciate ligament reconstruction. *Arthrosc Tech* 2023;12:e1789-e1796.
3. de Beus A, Koch JE, Hirschmann A, Hirschmann MT. How to evaluate bone tunnel widening after ACL reconstruction—a critical review. *Muscles Ligaments Tendons J* 2017;7:230-239.
4. Stolarz M, Ficek K, Binkowski M, Wrobel Z. Bone tunnel enlargement following hamstring anterior cruciate ligament reconstruction: A comprehensive review. *Phys Sportsmed* 2017;45:31-40.
5. Sauer S, Lind M. Bone tunnel enlargement after ACL reconstruction with hamstring autograft is dependent on original bone tunnel diameter. *Surg J (N Y)* 2017;3:e96-e100.
6. Kraeutler MJ, Welton KL, McCarty EC, Bravman JT. Revision anterior cruciate ligament reconstruction. *J Bone Joint Surg Am* 2017;99:1689-1696.
7. Crespo B, Aga C, Wilson KJ, et al. Measurements of bone tunnel size in anterior cruciate ligament reconstruction: 2D versus 3D computed tomography model. *J Exp Orthop* 2014;1:2.
8. Mitchell JJ, Chahla J, Dean CS, Cinque M, Matheny LM, LaPrade RF. Outcomes after 1-stage versus 2-stage revision anterior cruciate ligament reconstruction. *Am J Sports Med* 2017;45:1790-1798.
9. Eichinger M, Ploner M, Degenhart G, et al. Tunnel widening after ACL reconstruction with different fixation techniques: Aperture fixation with biodegradable interference screws versus all-inside technique with suspensory cortical buttons. 5-year data from a prospective randomized trial. *Arch Orthop Trauma Surg* 2023;143:6707-6718.
10. Liu D, Cai ZJ, Lu WH, et al. Eccentrically widened bone tunnels after all-inside anterior cruciate ligament reconstruction: A computed tomography and three-dimensional model-based analysis. *Knee Surg Sports Traumatol Arthrosc* 2023;31:2374-2385.
11. Clatworthy MG, Annear P, Bulow JU, Bartlett RJ. Tunnel widening in anterior cruciate ligament reconstruction: A prospective evaluation of hamstring and patella tendon grafts. *Knee Surg Sports Traumatol Arthrosc* 1999;7:138-145.
12. Bhullar R, Habib A, Zhang K, et al. Tunnel osteolysis post-ACL reconstruction: A systematic review examining select diagnostic modalities, treatment options and rehabilitation protocols. *Knee Surg Sports Traumatol Arthrosc* 2019;27:524-533.
13. Welder E, Magnussen RA, Fitzpatrick S, Duerr RA, Kaeding CC, Flanigan DC. Arthroscopic bone graft technique for two-stage revision anterior cruciate ligament reconstruction. *Arthrosc Tech* 2022;11:e1667-e1674.
14. Leafblad ND, Maak TG. Bone grafting technique in revision ACL reconstruction: Coring reamer and dowel trick. *Arthrosc Tech* 2022;11:e1367-e1372.
15. Kelly SR, Mustafa L, Al-Kharabsheh Y, DeFroda SF, Nuelle CW. All-arthroscopic bone grafting and primary fixation of a medial femoral condyle osteochondritis dissecans lesion. *Arthrosc Tech* 2023;12:e1721-e1725.