Infographic

Combined Anterior Cruciate Ligament and Lateral Extra-Articular Reconstruction

Andrew G. Geeslin, M.D., Jorge Chahla, M.D., Ph.D., and Robert F. LaPrade, M.D., Ph.D.

Abstract: The anterolateral complex (ALC) of the knee has received renewed research interest because of the potential role of this anatomic region in anterior cruciate ligament (ACL) tear biomechanics and surgical treatment outcomes. The primary structures of the ALC include the iliotibial band deep (Kaplan) fibers, the anterolateral ligament (ALL), and the capsulo-osseous layer (COL) of the iliotibial band, although there remains disagreement on the precise anatomic locations and biomechanical relevance of these structures. Sectioning studies in the ACL-deficient knee have revealed a contribution of the ALC in restraining tibial internal rotation and anterior translation. Biomechanical studies have revealed a potential role for lateral extra-articular reconstruction as an augmentation to ACL reconstruction in knees with combined ACL and ALC sectioning. Clinical studies have reported a reduced ACL reconstruction failure rate with both ALL reconstruction and lateral extra-articular tenodesis procedures.

Bibliography

DePhillipo NN, Cinque ME, Chahla J, Geeslin AG, LaPrade RF. Anterolateral ligament reconstruction techniques, biomechanics, and clinical outcomes: A systematic review. *Arthroscopy* 2017;33:1575-1583.

Geeslin AG, Chahla J, Moatshe G, et al. Anterolateral knee extra-articular stabilizers: A robotic sectioning study of the anterolateral ligament and distal iliotibial band Kaplan fibers. *Am J Sports Med* 2018;46:1352-1361.

Geeslin AG, Moatshe G, Chahla J, et al. Anterolateral knee extra-articular stabilizers: A robotic study comparing anterolateral ligament reconstruction and modified Lemaire lateral extra-articular tenodesis. *Am J Sports Med* 2018;46:607-616.

Getgood A, Brown C, Lording T, et al. The anterolateral complex of the knee: Results from the International ALC Consensus Group Meeting. *Knee Surg Sports Traumatol Arthrosc* 2019;27:166-176.

Getgood AMJ, Bryant DM, Litchfield R, et al. Lateral extra-articular tenodesis reduces failure of hamstring tendon autograft anterior cruciate ligament reconstruction: 2-Year outcomes from the STABILITY study randomized clinical trial. *Am J Sports Med* 2020;48:285-297.

Godin JA, Chahla J, Moatshe G, et al. A comprehensive reanalysis of the distal iliotibial band: Quantitative anatomy, radiographic markers, and biomechanical properties. *Am J Sports Med* 2017;45:2595-2603.

Kennedy MI, Claes S, Fuso FA, et al. The anterolateral ligament: An anatomic, radiographic, and biomechanical analysis. *Am J Sports Med* 2015;43:1606-1615.

Mahmoud A, Torbey S, Honeywill C, Myers P. Lateral extra-articular tenodesis combined with anterior cruciate ligament reconstruction is effective in knees with additional features of lateral, hyperextension, or increased rotational laxity: A matched cohort study. *Arthroscopy* 2022;38:119-124.

Slette EL, Mikula JD, Schon JM, et al. Biomechanical results of lateral extra-articular tenodesis procedures of the knee: A systematic review. *Arthroscopy* 2016;32:2592-2611.

From the Department of Orthopaedics and Rehabilitation, Larner College of Medicine, University of Vermont, Burlington, Vermont, U.S.A. (A.G.G.); Rush University Medical Center, Midwest Orthopaedics at Rush, Chicago, Illinois, U.S.A. (J.C.); and Twin Cities Orthopedics, Edina, Minnesota, U.S.A. (R.F.L.).

The authors report the following potential conflicts of interest or sources of funding: A.G.G. is on the editorial or governing board of Arthroscopy*; is Infographics Editor for* Arthroscopy*; is a paid consultant for Smith & Nephew; and paid presenter or speaker for Smith & Nephew and Ossur. J.C. is a paid consultant for Arthrex, ConMed Linvatec, Ossur, and Smith & Nephew and is a board or committee member of American Orthopaedic Society for Sports Medicine, Arthroscopy Association of North America, and International Society of Arthroscopy, Knee Surgery and Orthopaedic Sports Medicine. R.F.L. is a consultant for Arthrex, Ossur, and Smith & Nephew; receives royalties from Arthrex, Ossur, Smith & Nephew, and Elsevier; and is on the editorial board of American Journal of Sports Medicine, Knee Surgery Sports Traumatology Arthroscopy, Journal of Experimental Orthopaedics, Journal of Orthopaedic and Sports Physical Therapy, and Operative Techniques in Sports Medicine. Full ICMJE author disclosure forms are available for this article online, as supplementary material.*

Received March 24, 2022; accepted July 1, 2022.

Address correspondence to Andrew G. Geeslin, M.D., Department of Orthopaedics and Rehabilitation, Larner College of Medicine, University of Vermont, 95 Carrigan Dr, Stafford Hall, Fourth Floor, Burlington, Vermont 05405, U.S.A. E-mail: andrewgeeslinmd@gmail.com

0749-8063/22847/$36.00

https://doi.org/10.1016/j.arthro.2022.07.001

Combined ACL and Lateral Extra-Articular Reconstruction

Arthroscopy
The Journal of Arthroscopic and Related Surgery

ANTEROLATERAL COMPLEX (ALC) OF THE KNEE

- ALC structures include the anterolateral ligament/capsule (ALL), iliotibial band (ITB), Kaplan fibers, and capsuloosseous layer (COL) of the ITB
- The ALC is a secondary stabilizer to the ACL
- ALC injury may occur with ACL tears

LATERAL EXTRA-ARTICULAR RECONSTRUCTION

- Common procedures include ALL reconstruction and lateral extra-articular tenodesis (LET)

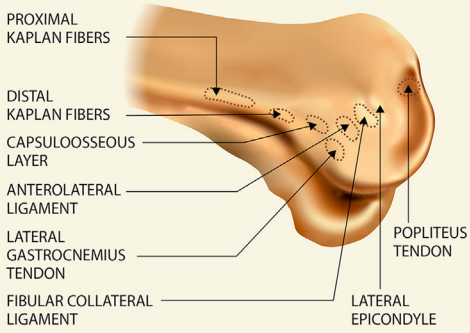

Right femur, lateral view, ALC and adjacent structure attachment

CLINICAL RELEVANCE

ACL Reconstruction (ACLR) augmented with lateral extra-articular reconstruction has been shown to reduce ACLR failure rate

POTENTIAL INDICATIONS FOR LATERAL EXTRA-ARTICULAR RECONSTRUCTION

Patient Factors

- Generalized laxity
- High-grade pivot shift
- Knee hyperextension
- Increased posterior tibial slope

Clinical Scenarios

- Young athletes returning to a pivoting sport
- Soft-tissue ACLR grafts
- Revision ACLR

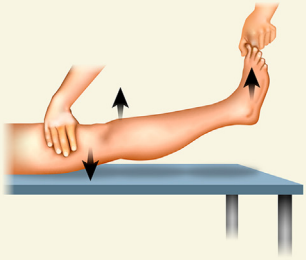

Right leg heel height test to assess knee hyperextension (recurvatum)

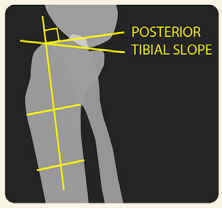

Right knee lateral X-Ray, measurement of posterior tibial slope

ALL RECONSTRUCTION

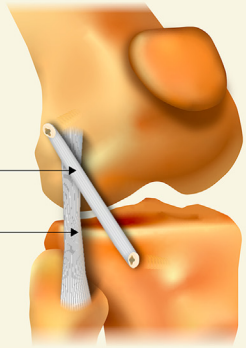

LET (MODIFIED LEMAIRE)

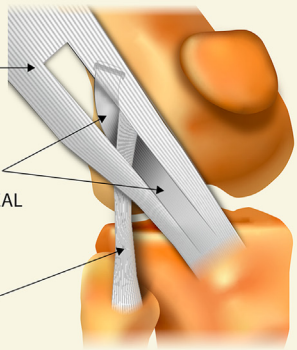

Andrew G. Geeslin, MD; Jorge Chahla, MD, PhD; Robert F. LaPrade, MD, PhD

Abstract and disclosure of potential author conflicts of interest are available at https://www.arthroscopyjournal.org/infographiclibrary