Infographic

Combined Meniscus Repair and Anterior Cruciate Ligament Reconstruction

Ariel N. Rodriguez, M.S., Robert F. LaPrade, M.D., Ph.D., and Andrew G. Geeslin, M.D.

Abstract: Meniscal tear patterns associated with anterior cruciate ligament (ACL) tears, such as root tears and ramp lesions are common but less easily recognized on magnetic resonance imaging (MRI) compared with a complete radial tear or a locked bucket-handle tear. Timely treatment of these tears improves outcomes in the setting of ACL reconstruction. While physical examination does not enable a definitive diagnosis of meniscal root tears and ramp lesions, high-grade laxity, including a 3+ Lachman and 3+ pivot shift, should raise suspicions for these tear patterns. MRI allows visualization of both root tears and ramp lesions, although the gold standard for diagnosis is probing at the time of arthroscopy due to a high false-negative rate on MRI. Up to 17% of patients with an ACL tear have a lateral meniscal root tear; a contact mechanism and increased posterior slope are both associated with a greater incidence of lateral meniscal root tears and these are repaired with a tunnel technique. Meniscal ramp lesions occur in up to 41% of patients with ACL tears due to a contact mechanism, and we prefer repair with an inside-out technique. More than 60% of complete radial meniscal tears occur in the setting of ACL tears and are preferentially repaired with a hashtag technique for minimally separated tears and a 2-tunnel technique combined with an inside-out repair for more severe tears. Bucket-handle tears are more common in the setting of chronic ACL deficiency; concurrent with ACL reconstruction urgent meniscal repair with an inside-out technique is the gold standard, which allows for precise approximation of the tear with multiple points of fixation for improved biomechanical performance. It is critical to identify and treat these tears during ACL reconstruction because of their role as secondary stabilizers and for long-term chondral protection.

Bibliography

Bollen SR. Posteromedial meniscocapsular injury associated with rupture of the anterior cruciate ligament: A previously unrecognised association. *J Bone Joint Surg Br* 2010;92:222-223.

Chahla J, Dean CS, Moatshe G, et al. Meniscal ramp lesions: Anatomy, incidence, diagnosis, and treatment. *Orthop J Sports Med* 2016;4:2325967116657815.

Cinque ME, Geeslin AG, Chahla J, Dornan GJ, LaPrade RF. Two-tunnel transtibial repair of radial meniscus tears produces comparable results to inside-out repair of vertical meniscus tears. *Am J Sports Med* 2017;45:2253-2259.

DePhillipo NN, Cinque ME, Chahla J, Geeslin AG, Engebretsen L, LaPrade RF. Incidence and detection of meniscal ramp lesions on magnetic resonance imaging in patients with anterior cruciate ligament reconstruction. *Am J Sports Med* 2017;45:2233-2237.

DePhillipo NN, Cinque ME, Kennedy NI, et al. Inside-out repair of meniscal ramp lesions. *Arthrosc Tech* 2017;6:e1315-e1320.

DePhillipo NN, Dornan GJ, Dekker TJ, Aman ZS, Engebretsen L, LaPrade RF. Clinical characteristics and outcomes after primary ACL reconstruction and meniscus ramp repair. *Orthop J Sports Med* 2020;8:2325967120912427.

From Twin Cities Orthopaedics, Edina, Minnesota (A.N.R., R.F.L.); and University of Vermont, Larner College of Medicine, Orthopaedics and Rehabilitation, Burlington, Vermont (A.G.G.), U.S.A.

The authors report the following potential conflicts of interest or sources of funding: R.F.L. reports personal fees from Arthrex, grants and personal fees from Ossur, grants and personal fees from Smith & Nephew, and personal fees from Linvatec, outside the submitted work; editorial boards for American Orthopaedic Society for Sports Medicine (AOSSM), Journal of Experimental Orthopaedics, Knee Surgery, Sports Traumatology, Arthroscopy*; and committees of AOSSM, AANA, and International Society of Arthroscopy, Knee Surgery and Orthopaedic Sports Medicine. Full ICMJE author disclosure forms are available for this article online, as supplementary material.*

Address correspondence to Andrew G. Geeslin, M.D., University of Vermont Larner College of Medicine, Department of Orthopaedics and Rehabilitation, 95 Carrigan Dr, Burlington, VT, 05405. E-mail: andrewgeeslinmd@gmail.com

0749-8063/211861/$36.00
https://doi.org/10.1016/j.arthro.2022.01.003

DePhillipo NN, Moatshe G, Chahla J, et al. Quantitative and qualitative assessment of the posterior medial meniscus anatomy: Defining meniscal ramp lesions. *Am J Sports Med* 2019;47:372-378.

Frank JM, Moatshe G, Brady AW, et al. Lateral meniscus posterior root and meniscofemoral ligaments as stabilizing structures in the ACL-deficient knee: A biomechanical study. *Orthop J Sports Med* 2017;5:2325967117695756.

Kunze KN, Wright-Chisem J, Polce EM, DePhillipo NN, LaPrade RF, Chahla J. Risk factors for ramp lesions of the medial meniscus: A systematic review and meta-analysis. *Am J Sports Med* 2021;49:3749-3757.

LaPrade CM, James EW, LaPrade RF. A modified transtibial pull-out repair for posterior root avulsions of the lateral meniscus with concomitant anterior cruciate ligament reconstruction: A Report of two cases. *JBJS Case Connect* 2014;4:e96.

LaPrade CM, Jansson KS, Dornan G, Smith SD, Wijdicks CA, LaPrade RF. Altered tibiofemoral contact mechanics due to lateral meniscus posterior horn root avulsions and radial tears can be restored with in situ pull-out suture repairs. *J Bone Joint Surg Am* 2014;96:471-479.

LaPrade RF, Floyd ER, Carlson GB, Moatshe G, Chahla J, Monson JK. Meniscal root tears: Solving the silent epidemic. *J Arthrosc Surg Sports Med* 2021;2:47-57.

Liu X, Feng H, Zhang H, Hong L, Wang XS, Zhang J. Arthroscopic prevalence of ramp lesion in 868 patients with anterior cruciate ligament injury. *Am J Sports Med* 2011;39:832-837.

Magosch A, Mouton C, Nührenbörger C, Seil R. Medial meniscus ramp and lateral meniscus posterior root lesions are present in more than a third of primary and revision ACL reconstructions. *Knee Surg Sports Traumatol Arthrosc* 2021;29:3059-3067.

Seil R, Mouton C, Coquay J, et al. Ramp lesions associated with ACL injuries are more likely to be present in contact injuries and complete ACL tears. *Knee Surg Sports Traumatol Arthrosc* 2018;26:1080-1085.

Sonnery-Cottet B, Praz C, Rosenstiel N, et al. Epidemiological evaluation of meniscal ramp lesions in 3214 anterior cruciate ligament-injured knees from the SANTI study group database: A risk factor analysis and study of secondary meniscectomy rates following 769 ramp repairs. *Am J Sports Med* 2018;46:3189-3197.

Combined Meniscus Repair and ACL Reconstruction

Arthroscopy
The Journal of Arthroscopic and Related Surgery

ROOT TEAR

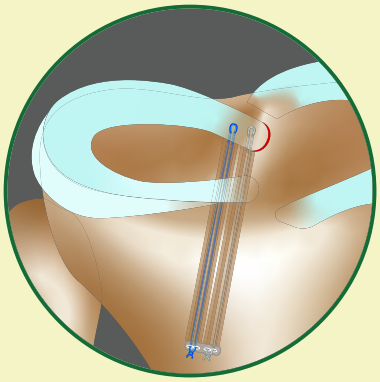

- Up to 17% incidence with ACL tears
- Increased frequency with contact mechanism and increased posterior tibial slope

RAMP LESION

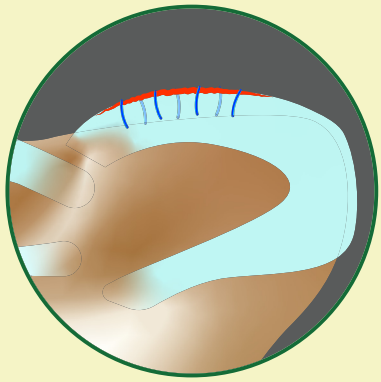

- Up to 41% incidence in contact mechanism ACL tears
- Repair improves knee stability

RADIAL TEAR

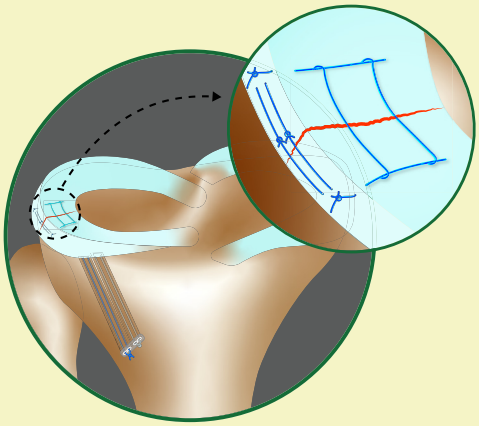

- 63% are combined with an ACL tear
- Repair results are clinically equivalent to those of vertical longitudinal tears

BUCKET-HANDLE TEAR

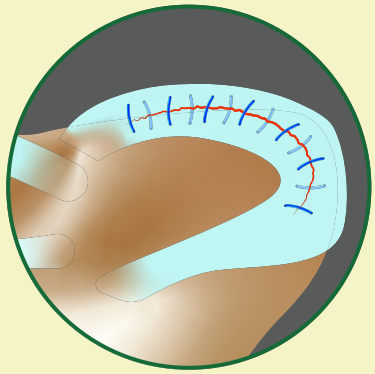

- Common in setting of chronic ACL deficiency
- Inside-out repair allows multiple fixation points with small meniscal penetration

SUMMARY

- MRI and arthroscopy facilitate diagnosis
- Concomitant ACL reconstruction results in the highest rates of meniscal healing
- Repaired meniscus improves biomechanical stability and reduces risk of ACL graft failure

Ariel N. Rodriguez, MS; Robert F. LaPrade, MD, PhD; Andrew G. Geeslin, MD

Abstract and disclosure of potential author conflicts of interest are available at https://www.arthroscopyjournal.org/infographiclibrary