

Technical Note

Posterior Approach for the Treatment of an Osteochondral Defect on the Posterior Lateral Femoral Condyle

Ariel N. Rodriguez, M.S., Lindsay C. Roethke, B.S., Daniel J. Liechti, M.D., and Robert F. LaPrade, M.D., Ph.D.

Abstract: Osteochondral defects of the knee often occur as a result of traumatic injury, repetitive microtrauma, or genetic predisposition. Smaller lesions can be treated nonoperatively in younger patient populations; however, large symptomatic lesions require surgical intervention using a fresh osteochondral allograft transplant. Although osteochondral defects classically appear on the lateral aspect of the medial femoral condyle, there have been cases in which the lesion is located on the posterior aspect of the lateral femoral condyle. To access these posteriorly located lesions, the surgeon must utilize a complex posterior approach in order to successfully manage these lesions. While care must be taken to protect the neurovascular bundle in this area, this technique allows for excellent exposure and optimal graft placement.

Introduction

Osteochondral defects of the knee commonly develop in young active patients after sustaining traumatic injury, such as an acute lateral patellar dislocation or a cruciate ligament tear.¹⁻⁴ Other causes have also been attributed to repetitive microtrauma, vascular abnormalities, and genetic predispositions, with the classic location being on the lateral aspect of the medial femoral condyle.⁵ Some focal osteochondral lesions may remain asymptomatic for a period of time and can be managed nonoperatively, especially in

young patients with open physes.⁶ However, in the case of symptomatic lesions refractory to nonoperative management, surgical intervention is indicated.^{7,8}

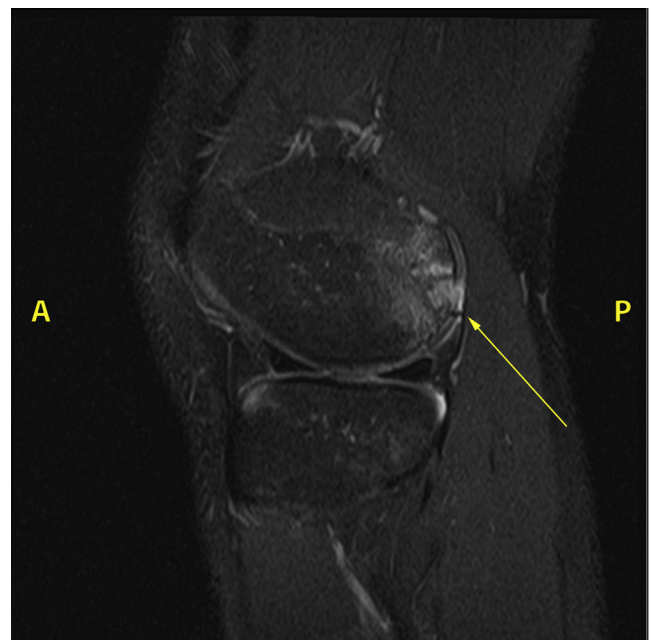

Fig 1. Sagittal view of a proton density fat suppressed magnetic resonance image of the left knee. The large osteochondral defect with a cystic component is visible on the posterior aspect of the lateral femoral condyle (yellow arrow). This location is difficult to access, making a posterior approach the preferred method of accessing this lesion. A, anterior; B, posterior.

Twin Cities Orthopedics, Edina-Crosstown, Edina, Minnesota, U.S.A. (A.N.R., L.C.R., D.J.L., R.F.L.); Georgetown University School of Medicine, Washington, D.C., U.S.A. (A.N.R.); and University of Minnesota Medical School, Minneapolis, Minnesota, U.S.A. (L.C.R.).

The authors report the following potential conflicts of interest or sources of funding: R.F.L. reports personal fees from Arthrex, Ossur, and Linvatec, as well as grants and personal fees from Ossur and Smith & Nephew, outside the submitted work. He reports being a board member of AOSSM, JEO, and KSSTA, and being a committee member of AOSSM, AANA, and ISAKOS. Full ICMJE author disclosure forms are available for this article online, as [supplementary material](#).

Received August 20, 2021; accepted November 10, 2021.

Address correspondence to Robert F. LaPrade, M.D., Ph.D., Twin Cities Orthopedics, Edina-Crosstown, 4010 W 65th St., Edina, MN, 55435 U.S.A.

© 2021 THE AUTHORS. Published by Elsevier Inc. on behalf of the Arthroscopy Association of North America. This is an open access article under the CC BY-NC-ND license (<http://creativecommons.org/licenses/by-nc-nd/4.0/>).

2212-6287/211220

<https://doi.org/10.1016/j.eats.2021.11.008>

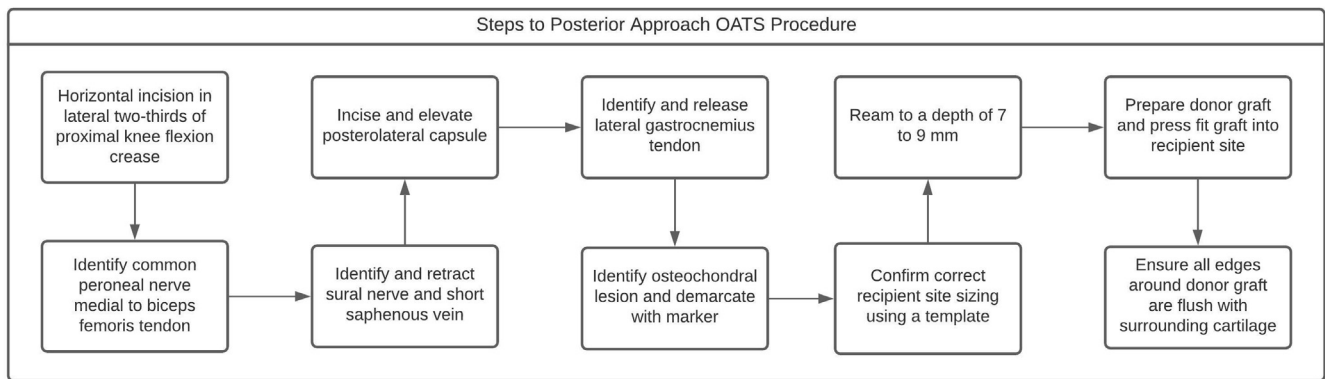


Fig 2. Flowchart illustrating the steps for a posterior approach Osteochondral Allograft Transplant System (OAT) procedure. This complex procedure must be carried out with extreme caution while protecting the neurovascular structures found posterior to the knee.

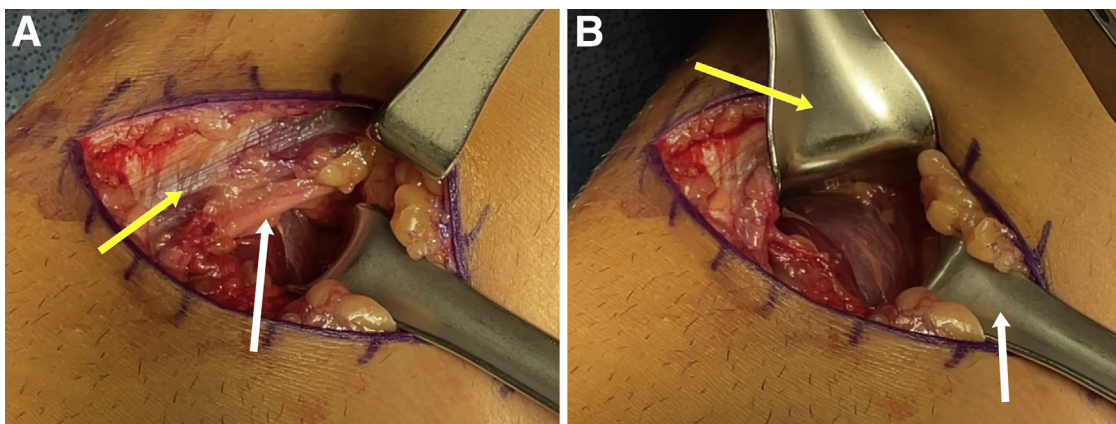


Fig 3. Intraoperative image illustrating the neurovascular structures that must be identified and protected during the posterior approach Osteochondral Allograft Transplant System (OATS) procedure. (A) The common peroneal nerve (white arrow) is identified just medial to the biceps femoris tendon (yellow arrow). (B) Retractors are used to protect the common peroneal nerve (yellow arrow) and sural nerve (white arrow). It is important to protect these structures to avoid iatrogenic injury, resulting in sensory or motor loss to the regions of the lower extremity supplied by them.

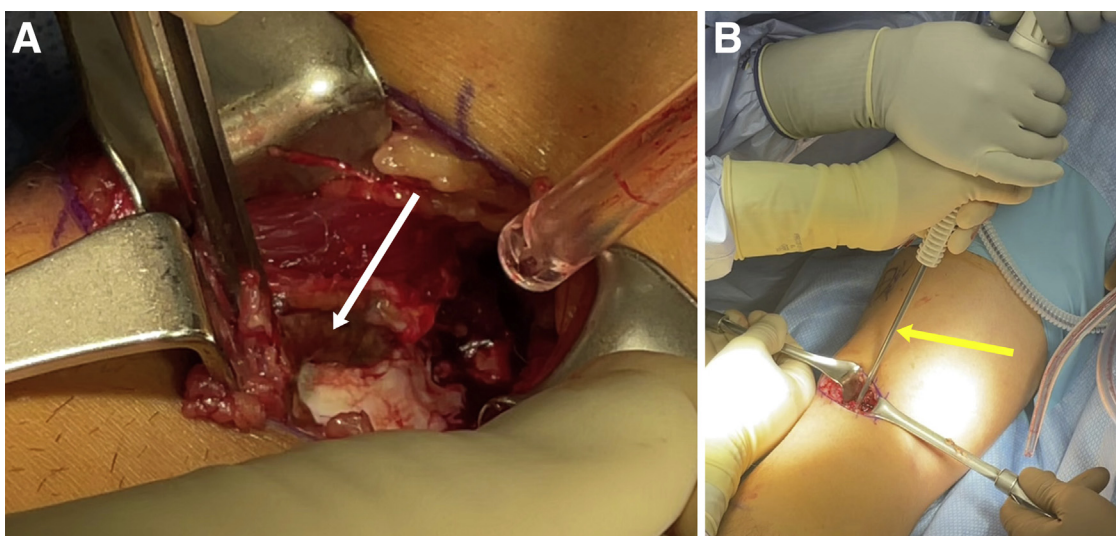


Fig 4. (A) Intraoperative photo showing elevation of the posterolateral capsule (white arrow) in order to expose the posterior aspect of the lateral femoral condyle of the femur. (B) Intraoperative photo illustrating placement of a suture anchor that will later be used to repair the lateral gastrocnemius, which was released to improve access. Proper exposure of the osteochondral lesion is critical for proper measurement and fitting of the donor graft.

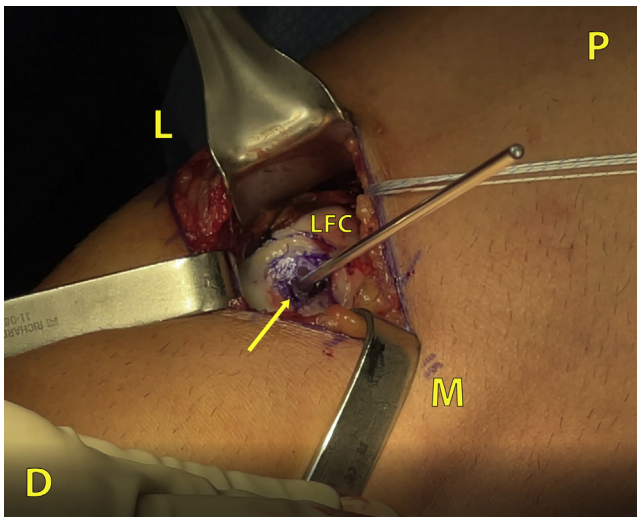


Fig 5. Intraoperative photograph of the osteochondral lesion on the posterior aspect of the lateral femoral condyle labeled with a methylene blue marker (yellow arrow). The damaged tissue absorbs the methylene blue ink, clearly demarcating the extent of the lesion. Demarcating the extent of the lesion is critical for proper sizing of the donor graft. A guide pin is placed in the center of the lesion in preparation for scoring and reaming of the recipient site. D, distal; L, lateral; LFC, lateral femoral condyle; M, medial; P, proximal.

Other characteristics of osteochondral defects that further complicate their treatment include extensive size, significant amounts of subchondral bone damage, and involvement of weight-bearing areas of the knee joint.^{7,9} Several procedures involving autograft harvesting and matrix-induced autologous chondrocyte implantation have been used to restore chondral

surface integrity, but most of these are limited to addressing smaller lesions through an anterior approach.^{4,8,10} Fresh allografts are typically reserved for lesions larger than (greater than 3 cm²) or those that may also have a cystic component.¹¹

Fresh osteochondral allograft transplantation has emerged as a safe and effective treatment option for large, symptomatic osteochondral lesions of the knee refractive to nonoperative management.^{8,12-15} This method has reported graft survival rates of 87% and 82% at 5 years and 10 years after procedure, respectively.^{12,13,16} Fresh allograft implants have also demonstrated significantly improved patient-reported knee function and clinical outcomes.^{11-13,17}

Osteochondral lesions located in the posterior aspect of the femur are uncommon, but from a surgical standpoint, they pose additional difficulty in accessing them.¹⁸ In order to allow for anatomic allograft placement, a technically challenging posterior approach may be required.^{7,19,20}

In this Technical Note, we describe placement of fresh osteochondral allograft to the posterior surface of the lateral femoral condyle of the knee (Fig 1). Specifically, we describe an updated, in-depth surgical technique for a knee arthrotomy using a posterior approach, which optimizes access and visualization for treating posterior lesions (Fig 2).

Surgical Technique

The patient is brought to the operating room and induced under general endotracheal anesthesia. A knee exam, including range of motion, is performed under anesthesia. A well-padded high left thigh tourniquet is

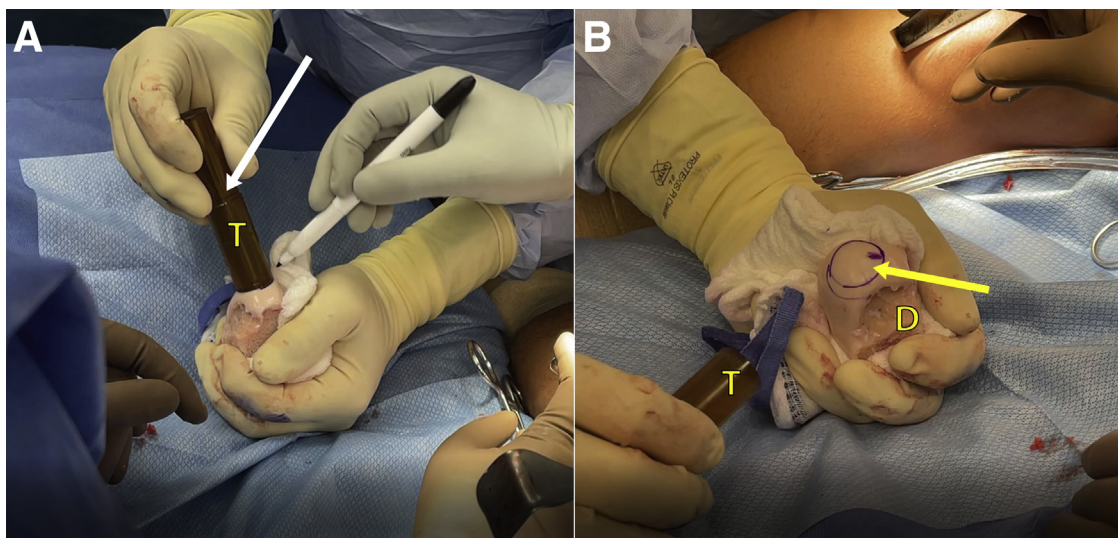


Fig 6. (A) Intraoperative photograph illustrating how the surgeon marks the area on the donor graft using the 20-mm template (white arrow). (B) Intraoperative image illustrating the final markings on the donor graft prior to preparation (yellow arrow). An extra mark is added to denote the north pole of the donor graft. Correct sizing must be achieved, so that the donor graft can be press fit into the recipient site. D, donor graft; T, template.

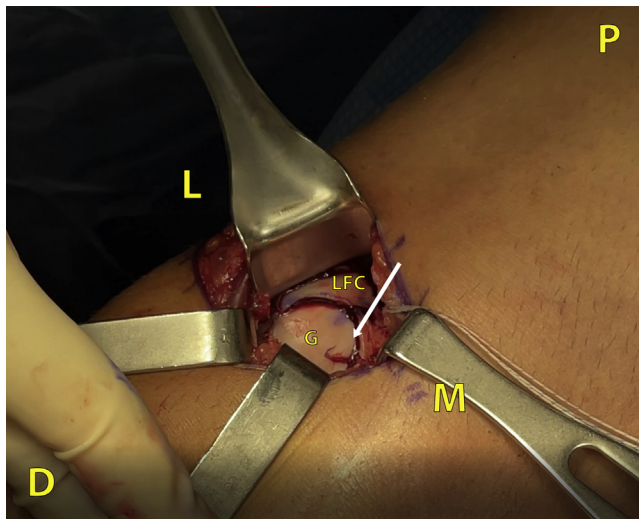


Fig 7. Intraoperative photograph illustrating the donor graft placed within the recipient site in that lateral femoral condyle (white arrow). It is critical for the graft to fit flush with the surrounding area to avoid a proud graft, which can result in a “kissing” lesion on the tibial articular surface. The graft is press fit into the recipient site, eliminating the need for any hardware to keep it in place. D, distal; G, graft; L, lateral; LFC, lateral femoral condyle; M, medial; P, proximal.

placed. The patient is intubated and then placed in the prone position, with care being taken to ensure that the torso and extremities and face are well padded. The arms are left out to allow for additional anesthesia access to the patient.

A horizontal incision is made along the lateral two-thirds of the of the proximal knee flexion crease. Dissection is carried out through the subcutaneous tissue down to the superficial fascia, which is incised. The common peroneal nerve is identified deep to the superficial fascia coursing just medial to the biceps femoris tendon. At the midline, the sural nerve, accompanied by the short saphenous vein, should be protected throughout the case (Fig 3). The surgeon then proceeds to dissect down and identify the lateral gastrocnemius tendon. Two small Richardson retractors are used to gently retract the nerves and dissect down to the lateral capsule. A spinal needle may be used to ensure that the lateral margin of the posterior aspect of the intercondylar notch was identified. A #15 blade is used to incise the posterolateral joint capsule at the intercondylar notch, which is then elevated in a full-thickness manner off the posterior aspect of the

lateral femoral condyle. A Q-fix fix anchor (Smith and Nephew, London, UK) is placed where the lateral gastrocnemius tendon was released to perform a repair later in the procedure. (Fig 4).

Two Z-retractors are placed along the distal aspect of the condyle, and two Richardson's retractors are placed proximally. The osteochondral defect is now identified. A methylene blue marker is used to outline the defect. The dye of the methylene blue marker is absorbed where the tissue is damaged at the site of the prior failed microfracture and matrix-induced autologous chondrocyte implantation (MACI) procedures, and no dye is absorbed by the normal articular cartilage (Fig 5). The lesion is now templated. In this case, the surgeon confirms that a 20-mm graft is required. A guide pin is now placed in the center of the defect, and the 20-mm template is placed over the guide pin. Measurements are obtained to confirm that this is the desired location for placement of the graft. The recipient site is now scored by the surgeon. This is followed by reaming with copious irrigation to a depth of ~7 to 9 mm of total depth. The depth of the lesion is measured at the north, east, south, and west poles of the reamed area. The surgeon then proceeds to dilate the recipient site.

The fresh osteoarticular femur donor graft is then brought to the table and templated with the 20-mm template. A blue methylene marker is used to label the 20-mm donor area, and the donor site is confirmed to reproduce the recipient site appropriately (Fig 6). The donor graft is now brought to the back table and harvested using a saw blade and an Arthrex Osteochondral Allograft Transplant System (OATS) harvesting kit (Naples, FL). Measurements are taken to match the depth of all four poles of the recipient site after harvesting the graft. The donor graft is cut to the appropriate depth using a saw blade (Stryker, Kalamazoo, MI). The subchondral bone of the donor graft is now thoroughly washed using a pulse lavage. The donor graft is now press fitted into the recipient site until an anatomic fit is achieved. The surgeon ensures that all edges of the donor graft are flush with the surrounding area (Fig 7).

Following satisfactory placement of the graft, attention is turned to repairing the lateral gastrocnemius tendon and the lateral capsule. The biceps and the common peroneal nerve are gently retracted laterally, and the sural nerve is gently retracted medially. A free

Table 1. Pearls and Pitfalls

Pearls	Pitfalls
Identify associated neurovascular bundles and gently retract them while dissecting. Occasionally relax retraction on the peroneal nerve.	Failure to isolate and mobilize the peroneal nerve can result in injury.
The gastrocnemius tendon can be partially or completely released to improve exposure of the posterior lateral femoral condyle.	A proud graft can increase joint reactive forces and result in a kissing lesion on the contralateral articular surface

Table 2. Surgical Advantages and Disadvantages

Advantages	Disadvantages
Optimal exposure of posterior aspect of lateral femoral condyle Allows for anatomic placement of donor graft	Prone Position Risk of damaging posterior neurovascular structures Lateral gastrocnemius tendon must be temporarily released with lateral capsule

needle is used to thread each of the previously placed suture anchors in order to perform the lateral gastrocnemius tendon and capsular repair. The tourniquet is let down, the deep tissue is closed with 2-0 Vicryl, and the skin is closed with a running Monocryl. The technique described is demonstrated and summarized in the supplemental video (Video 1).

The patient is admitted to the observation area for pain control. The patient is non-weightbearing on the affected extremity for 8 weeks. Flexion is limited to 90° for the first 2 weeks, and range of motion may be increased, as tolerated, from that point onward. Physical therapy on postoperative day 1 focuses on quadriceps activation, edema control, and knee motion. Patients are placed on Lovenox for deep vein thrombosis prophylaxis for 2 weeks and then transitioned to aspirin and thromboembolism-deterrent hose are worn until weight bearing is initiated. At 8 weeks, patients undergo anterior-posterior and lateral radiographs to assess for early evidence of creeping substitution at the graft-donor site. At this point, a protected weight-bearing program may be initiated, advancing at 25% of body weight per week. Follow-up radiographs are obtained at the 3-month mark to assess for further evidence of healing. If bone healing is present at 3 months, patients undergo follow-up radiographs at 6 months, 1 year, and 2 years, to verify that the donor graft has fully healed into place, with no evidence of any subchondral cystic changes.

Discussion

This Technical Note describes a complex approach that requires extreme care but allows for the benefit of excellent exposure of the posterior aspect of the lateral femoral condyle. In addition to gaining improved exposure, this approach allows the surgeon an optimal angle to implant the donor graft to achieve an anatomic press fit.

The posterior approach has been labeled as “no man’s land” in the past due to the relatively high risk and complex nature that is associated with it.⁷ Extreme care should be taken to identify and protect the neurovascular structures throughout this approach. Particular attention should be paid to retraction of the common peroneal nerve with regular intervals of relaxation from retraction. Care should also be taken to ensure that the donor graft is flush with the surrounding articular tissue. Failure to achieve a congruent lesion due to an

excessively large graft is referred to as a proud graft and can create abnormal joint reactive forces, resulting in a “kissing lesion” on the tibial articular surface.²⁰ Pearls and pitfalls associated with this technique are summarized in Table 1.

Overall, advantages and disadvantages for the posterior approach are described in Table 2. While the posterior approach to the knee is complex and has inherent risks, a successful technique allows for excellent visualization and optimal graft placement in large posterior lesions.

References

1. Seeley MA, Knesek M, Vanderhave KL. Osteochondral injury after acute patellar dislocation in children and adolescents. *J Pediatr Orthop* 2013;33:511-518.
2. Noyes FR, Bassett RW, Grood ES, Butler DL. Arthroscopy in acute traumatic hemarthrosis of the knee. Incidence of anterior cruciate tears and other injuries. *J Bone Joint Surg Am* 1980;62:687-695, 757.
3. Brophy RH, Zeltser D, Wright RW, Flanigan D. Anterior cruciate ligament reconstruction and concomitant articular cartilage injury: Incidence and treatment. *Arthroscopy* 2010;26:112-220.
4. Bauer KL. Osteochondral injuries of the knee in pediatric patients. *J Knee Surg* 2018;31:382-391.
5. Maglio M, Brogini S, Pagani S, Giavaresi G, Tschon M. Current trends in the evaluation of osteochondral lesion treatments: Histology, histomorphometry, and biomechanics in preclinical models. *Biomed Res Int* 2019;2019:4040236.
6. Kao YJ, Ho J, Allen CR. Evaluation and management of osteochondral lesions of the knee. *Phys Sportsmed* 2011;39:60-69.
7. LaPrade RF, Devitt BM, Huleatt JB, Nepple JJ. A novel posterior arthrotomy approach for the treatment of a large osteochondral defect of the posterior aspect of the lateral femoral condyle of the knee: A case report and technical note. *JBJS Case Connect* 2013;3(4 Suppl 3):1-5.
8. Pisanu G, Cottino U, Rosso F, Blonna D, Marmotti AG, Bertolo C, et al. Large osteochondral allografts of the knee: Surgical technique and indications. *Joints* 2018;6:42-53.
9. Karataglis D, Learmonth DJ. Management of big osteochondral defects of the knee using osteochondral allografts with the MEGA-OATS technique. *Knee* 2005;12:389-393.
10. Cain EL, Clancy WG. Treatment algorithm for osteochondral injuries of the knee. *Clin Sports Med* 2001;20:321-342.
11. LaPrade RF, Botker J, Herzog M, Agel J. Refrigerated osteoarticular allografts to treat articular cartilage defects of the femoral condyles. A prospective outcomes study. *J Bone Joint Surg Am* 2009;91:805-811.

12. Levy YD, Görtz S, Pulido PA, McCauley JC, Bugbee WD. Do fresh osteochondral allografts successfully treat femoral condyle lesions? *Clin Orthop Relat Res* 2013;471:231-237.
13. Gilat R, Haunschild ED, Huddleston HP, Tauro TM, Patel S, Wolfson TS, et al. Osteochondral allograft transplant for focal cartilage defects of the femoral condyles: Clinically significant outcomes, failures, and survival at a minimum 5-year follow-up. *Am J Sports Med* 2021;49:467-475.
14. Frank RM, Cotter EJ, Lee S, Poland S, Cole BJ. Do outcomes of osteochondral allograft transplantation differ based on age and sex? A comparative matched group analysis. *Am J Sports Med* 2018;46:181-191.
15. Chahal J, Gross AE, Gross C, et al. Outcomes of osteochondral allograft transplantation in the knee. *Arthroscopy* 2013;29:575-588.
16. Frank RM, Lee S, Levy D, et al. Osteochondral allograft transplantation of the knee: analysis of failures at 5 years. *Am J Sports Med* 2017;45:864-874.
17. Familiari F, Cinque ME, Chahla J, et al. Clinical outcomes and failure rates of osteochondral allograft transplantation in the knee: A systematic review. *Am J Sports Med* 2018;46:3541-3549.
18. Outerbridge RE. Osteochondritis dissecans of the posterior femoral condyle. *Clin Orthop Relat Res* 1983;175:121-129.
19. Faucett SC, Gannon J, Chahla J, Ferrari MB, LaPrade RF. Posterior surgical approach to the knee. *Arthrosc Tech* 2017;6:e391-e395.
20. Johnson MR, LaPrade RF. Tibial plateau "kissing lesion" from a proud osteochondral autograft. *Am J Orthop* 2011;40:359-361.