Technical Note

Proximal Tibial Opening Wedge Osteotomy for the Treatment of Posterior Knee Instability and Genu Recurvatum Secondary to Increased Anterior Tibial Slope

Ariel N. Rodriguez, M.S., Foley Schreier, B.S., Gregory B. Carlson, M.D., and Robert F. LaPrade, M.D., Ph.D.

Abstract: Decreased posterior tibial slope has been associated with increased risk of graft failure and knee instability after posterior cruciate ligament (PCL) reconstruction. Premature physeal arrest at the tibial tubercle is a common cause of osseous genu recurvatum. Surgical management is recommended to correct the tibial slope and prolong the integrity of the PCL graft. This article discusses our preferred treatment using a proximal tibial opening wedge osteotomy for surgical management of posterior knee instability and genu recurvatum secondary to significant anterior tibial slope.

Proximal tibial opening wedge osteotomies are indicated for cases of symptomatic genu recurvatum or increased anterior slope. A systematic review supported surgical management of symptomatic genu recurvatum using an anterior opening-wedge PTO to increase the tibial slope. Correcting the anterior slope to a more anatomic, posterior orientation would allow the ligaments to return to their normal tension and restore the native biomechanics of the knee.[1] Symptomatic genu recurvatum is defined as symptomatic hyperextension of the knee >5°.[1] The most common symptoms of genu recurvatum include pain, weakness, instability, decreased range of motion, leg length discrepancy, and stretching of the posterior capsuloligamentous structures of the knee.[1,2] Genu recurvatum can be categorized as osseous, ligamentous, or combined. Premature physeal arrest, which in many cases occurs at the tibial tubercle growth plate, is a major cause of osseous genu recurvatum.[1,2] Flattening of the tibial slope has been shown to correlate with higher remaining posterior tibial translation (PTT) and less reduction of PTT after posterior cruciate ligament (PCL) reconstruction.[3-6] Decreased posterior slope has also been shown to be associated with greater hyperextension of the knee.[6,7] Because of the effect of tibial slope on PTT, patients with PCL reconstruction are at increased risk of postoperative instability.[3]

From Twin Cities Orthopedics, Edina-Crosstown, Edina, Minnesota, U.S.A. (A.N.R., F.S., G.B.C., R.F.L.); Georgetown University School of Medicine, Washington, District of Columbia, U.S.A. (A.N.R.); and the University of North Dakota School of Medicine and Health Sciences, Grand Forks, North Dakota, U.S.A. (F.S.).

The authors report the following potential conflicts of interest or sources of funding: R.F.L. reports personal fees, Arthrex, Linvatec; grants and personal fees, Ossur, Smith & Nephew; editorial board, AOSSM, JEO, KSSTA committees, AANA, ISAKOS. Full ICMJE author disclosure forms are available for this article online, as supplementary material.

Received June 29, 2021; accepted August 10, 2021.

Address correspondence to Robert F. LaPrade, M.D., Ph.D., Twin Cities Orthopedics, Edina-Crosstown, 4010 W 65th St, Edina, MN, 55435 U.S.A. E-mail: laprademdphd@gmail.com

2212-6287/21973

https://doi.org/10.1016/j.eats.2021.08.018

Operative Technique

Patient Evaluation

The patient in our case had undergone a prior PCL reconstruction 4 years prior, but the anterior tibial slope was not recognized at that time. As a result of unrecognized anterior tibial slope, the PCL reconstruction graft failed over time.

Imaging

The magnetic resonance imaging scan showed no tunnel osteolysis, so bone grafting was not necessary. Lateral radiograph of the right knee showed 13° anterior tibial slope (Figs 1 and 2).

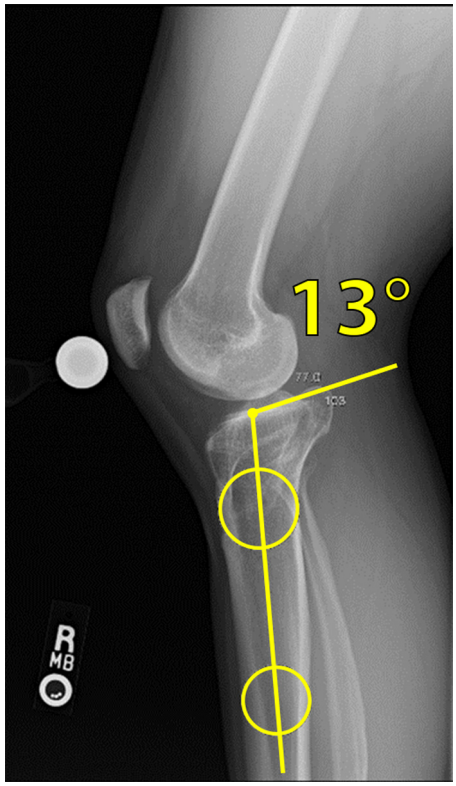

Fig 1. Lateral view radiograph of a right knee with the patient standing upright, showing anterior tibial slope of 13°. This figure illustrates the extent of anterior tibial slope and how it can affect tibial translation and forces on posterior cruciate ligament grafts.

Indications

The intact PCL graft was left in place to see whether it would provide stability. Here we describe a proximal tibial opening wedge osteotomy technique with allograft bone graft as a treatment for grade 3 PCL instability and genu recurvatum with 13° anterior tibial slope.

The patient is brought into the operating room and placed in the supine position and induced under general anesthesia without any complications. A well-padded high right thigh tourniquet is placed. Range of motion is assessed under general anesthesia along with Lachman's, pivot, posterior drawer, varus, and valgus stress, dial, and posterolateral drawer tests. Cefazolin (2 g) is given before incision.

The surgical technique is demonstrated in the Video 1. Intraarticular pathology is addressed before the

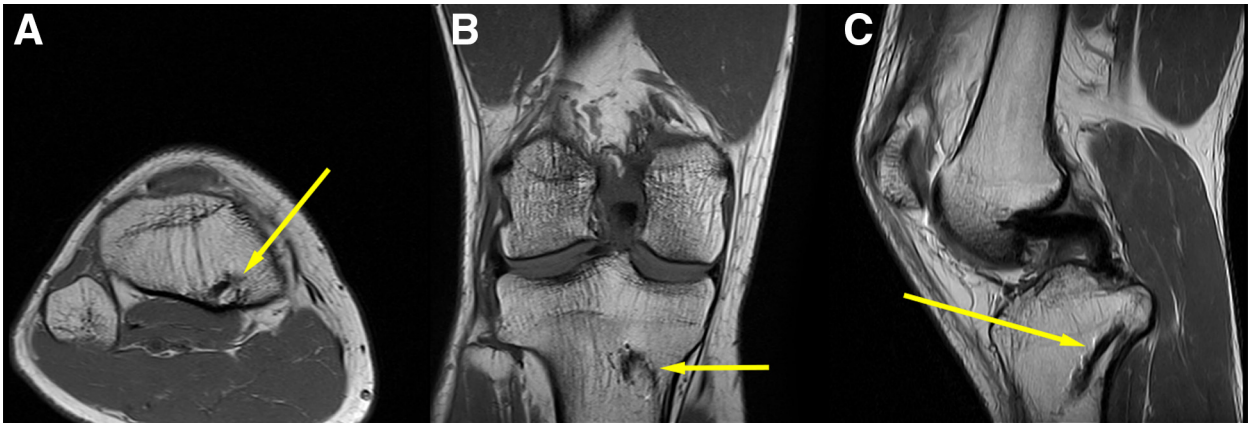

Fig 2. (A) Transverse magnetic resonance imaging (MRI) view of the proximal tibia and fibula of the right tibia, showing a posterior cruciate ligament (PCL) bone tunnel without osteolysis. (B) Coronal MRI view of the right knee, showing a PCL bone tunnel without osteolysis. (C) Sagittal MRI view of the right knee, showing a PCL bone tunnel without osteolysis. These images illustrate why bone grafting was not necessary and partially explain why the PCL graft can be left intact after the osteotomy procedure.

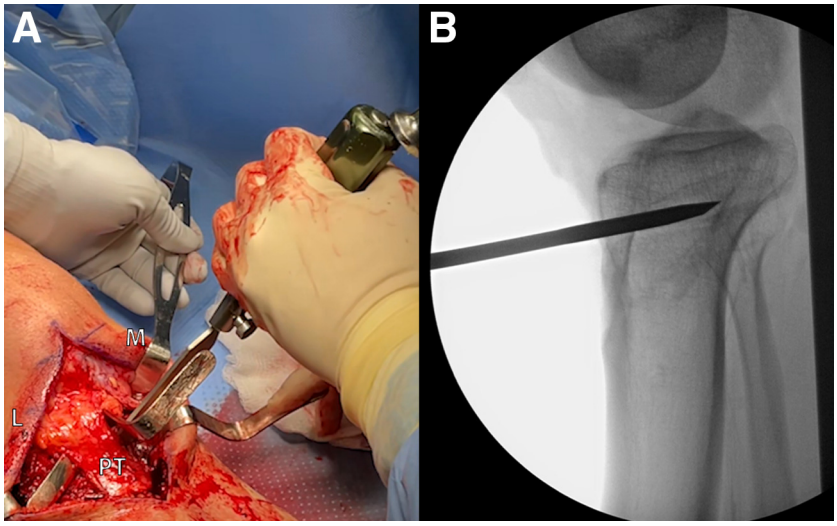

Fig 3. (A) Intraoperative photo of an osteotome being used to create the opening wedge in the right tibia. (B) Intraoperative fluoroscopic imaging, confirming that osteotome placement is within 1 cm of the posterior cortex. This portion of the procedure is performed to ensure that the osteotomy is the correct depth while taking extreme care to leave the posterior tibial cortex intact. L, lateral; M, medial; PT, patellar tendon.

osteotomy. An incision is made from the midportion of the patella and extended down distally to the tibial tubercle, raising full-thickness subcutaneous flaps. Medial dissection is performed, and the periosteum under the MCL is elevated to the posteromedial corner of the tibia. The patellar tendon is isolated, and the tibial tuberosity is exposed. A retractor is placed to protect the extensor mechanism. Laterally, the anterior compartment musculature is elevated 1 cm along the area over Gerdy's tubercle. Lateral dissection is carried out until the anterior aspect of the proximal tibiofibular joint is exposed.

Two guide pins are place parallel to the joint line of the knee, just proximal to the tibial tubercle. The pins are inserted until they hit the posterior cortex of the tibia, and their position is confirmed by fluoroscopy. These pins are used as guides for performing the osteotomy.

A small saw blade (Stryker, Kalamazoo, MI) is used to make anterior, anteromedial, and anterolateral cortical cuts, taking care to protect the extensor mechanism. After correct placement is confirmed by fluoroscopy, an osteotome is used until it is within 1 cm of the posterior

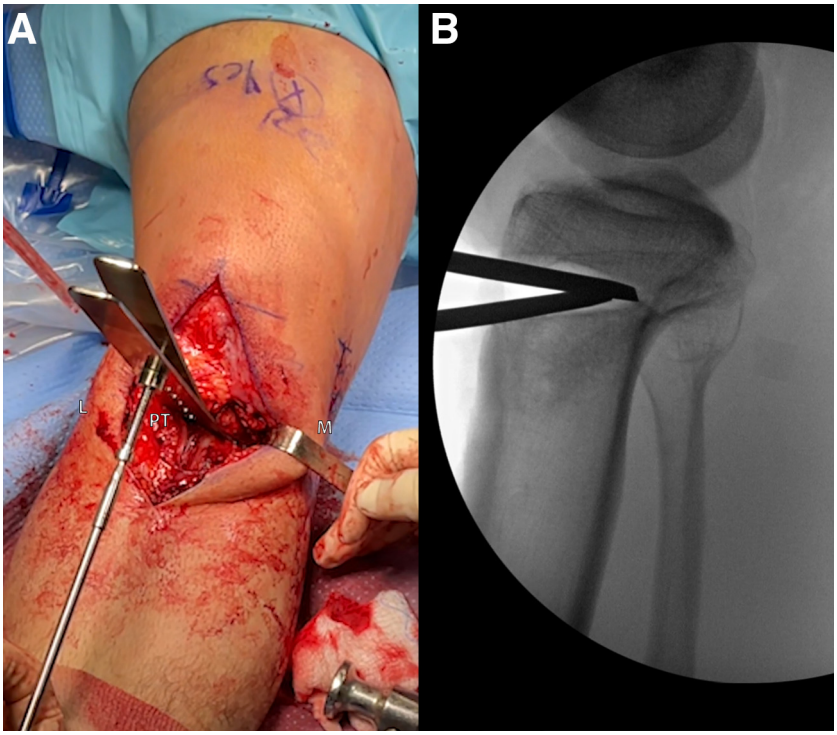

Fig 4. (A) Intraoperative photo of a spreader device being opened gradually and continuously until the desired tibial slope is achieved on fluoroscopic imaging. (B) Fluoroscopic imaging is used to confirm that the desired slope has been achieved and that the posterior cortex has not been violated. This portion of the procedure is performed to gradually open the wedge while preventing excessive stress on the posterior cortex of the tibia.

Table 1. Pearls and pitfalls

Pearls	Pitfalls
Subperiosteally elevate the anterior compartment to the proximal tibiofibular joint laterally and medially to posteromedial tibial cortex, allowing for good soft tissue closure around the osteotomy.	Consider performing surgical approach first to avoid fluid extravasation.
Verify fluoroscopically that guide pins are parallel to the joint line fluoroscopically before initiating the osteotomy.	Anterior osteotomy poses a potential risk to the popliteal neurovascular bundle; exercise caution to maintain posterior tibial cortex, and use fluoroscopic guidance for pin placement.
The osteotomy cut needs to include the entire medial and lateral cortex to ensure appropriate posterior hinge.	The extensor mechanism could be injured during the osteotomy if not protected with retractors.
An osteotomy opening of 1 mm is equivalent to 1° of tibial slope correction.	Gently open the osteotomy to decrease the risk of fracture of the posterior tibial cortex.

cortex both medially and laterally (Fig 3). Great care is taken not to violate the posterior cortex while using the osteotome. A small osteotome is used on the posteromedial corner to ensure that the wedge can be opened.

The spreader device is placed just medial to the patellar tendon and the tibial tubercle. The opening spreader is opened gradually and continuously until the posterior tibial slope is in the desired neutral position on fluoroscopy and the recurvatum is eliminated (Fig 4). The spreader device is left in place for 5 minutes to allow for stress relaxation of the posterior cortex. Based on preoperative planning using radiographic imaging, and knowing that 1 mm of change is equivalent to 1° of tibial slope,[8] an appropriately sized plate is available for the patient (Table 1). This is confirmed during intraoperative measurement with a ruler.

The appropriately sized, posteriorly sloped Puddu plate (Arthrex, Naples, FL) is placed just medial to the patellar tendon anteriorly. The plate is fixed proximally with two 6.5-mm, fully threaded cancellous screws and distally with two 4.5-mm cortical screws (Fig 5). A Richards staple (Smith & Nephew, London, UK) is placed in the anterolateral aspect of the wedge to prevent further opening. The osteotomy is then packed with Opteform allograft bone graft (Exactech, Gainesville, FL). Final fluoroscopic images are obtained to confirm osteotomy position, hardware position, and adequate bone grafting.

The tourniquet is released, and copious irrigation is performed. The deep tissues are closed with 0 and 2-0 Vicryl, followed by a Monocryl stitch for the skin. Steri-Strips are very loosely applied. A sterile dressing is applied along with a knee immobilizer in full extension.

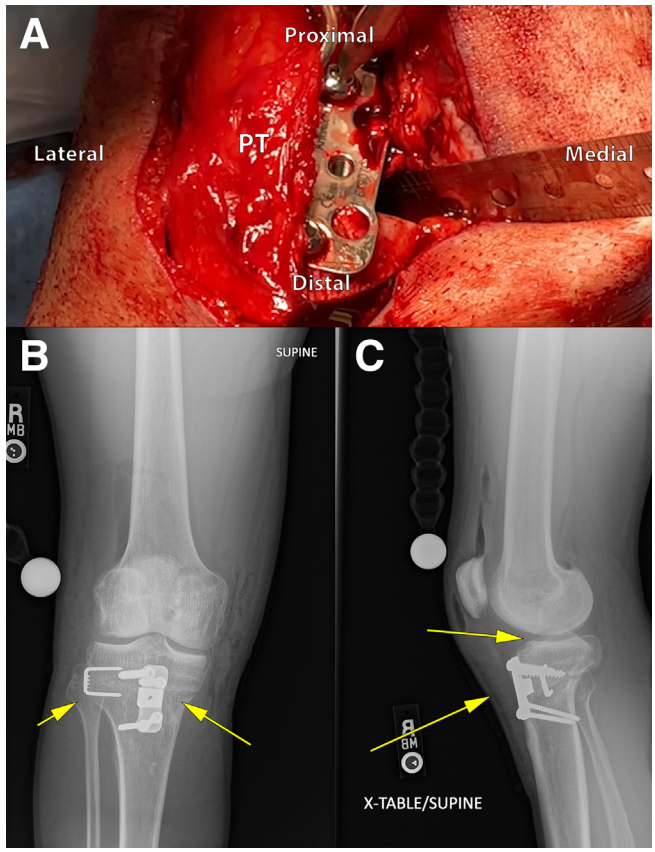

Fig 5. (A) A posteriorly sloped Puddu plate is placed just medial to the patellar tendon and fixed proximally with 2 cancellous screws and distally with 2 cortical screws. (B) Anteroposterior radiograph of the right knee showing appropriate placement of Puddu plate and anterolateral large Richards staple. (C) Lateral radiograph of the right knee confirming proper placement of Puddu plate and correction of anterior tibial slope. In these radiographs, it is evident that the tibial slope has been corrected, resulting in elimination of genu recurvatum and posterior tibial translation. PT, patellar tendon.

Patients should be non-weightbearing on the operated leg for 8 weeks. Hyperextension is to be avoided for the first 8 weeks. A goal of 0° to 90° of range of motion is established for the first 2 weeks. Physical therapy should begin the day after surgery to ensure knee motion, quadriceps activation, and edema control.

Table 2. Advantages and disadvantages

Advantages	Disadvantages
Allows for correction of sagittal plane tibial slope and genu recurvatum	Long period of non-weightbearing to allow osteotomy to heal
Can impart stability to posterior cruciate ligament (PCL)-deficient knee, potentially limiting need for second-stage PCL reconstruction	Risk of injury to popliteal neurovascular structures
Can perform simultaneous bone grafting of PCL tunnels if tunnel osteolysis is present	Technically demanding procedure

Deep vein thrombosis prophylaxis with enoxaparin for 2 weeks is recommended, followed by transition to aspirin and thromboembolic deterrant hose. Anteroposterior and lateral radiographs are obtained on postoperative day 1 and at 8 weeks. If there is evidence of healing at 8 weeks, then a partial-protected weightbearing program can be initiated. Once weightbearing is initiated, patients can advance one-quarter body weight per week until they are fully weightbearing. Anteroposterior and lateral radiographs are repeated at 3 months, and a PCL stress radiograph is performed at 6 months to verify that the posterior translation is addressed sufficiently with the osteotomy.

Discussion

Anterior opening wedge proximal tibial osteotomy is usually indicated for cases of genu recurvatum secondary to anterior tibial slope. A systemic review found that anterior slope is the predominant cause of genu recurvatum.[1,7] As posterior tibial slope increases, the resultant force on the PCL also decreases owing to downward forces being directed anteriorly through the tibia. As the posterior tibial slope decreases, forces through the PCL increase and can lead to instability or graft failure in cases of prior PCL reconstruction.[4,7,9]

One cohort of 5 osteotomies for the correction of genu recurvatum, with an average preoperative anterior tibial slope of 17° and an average postoperative posterior slope of 0.4°, achieved complete union of the osteotomy by 3 months without complications in all 5 cases.[2] Two of the patients in this cohort with preoperative posterior instability secondary to PCL insufficiency showed improved posterior instability by 1 grade postoperatively, with 1 patient going from grade 3 to grade 2 and another going from grade 2 to grade 1.[2] Another case report of a patient requiring opening wedge anterior tibial osteotomy for genu recurvatum showed uneventful recovery with complete resolution of symptoms and significantly improved subjective scores.[10]

Overall, anterior opening wedge anterior proximal osteotomy is a reliable surgical treatment for genu recurvatum, with patients being able to expect correction of knee hyperextension, restoration of a more posterior tibial slope, decreased posterior tibial translation, and increased subjective outcome scores (Table 2).[1]

References

1. Dean RS, Graden NR, Kahat DH, DePhillipo NN, LaPrade RF. Treatment for symptomatic genu recurvatum: A systematic review. *Orthop J Sports Med* 2020;8:2325967120944113.
2. Kim TW, Lee S, Yoon J-R, Han H-S, Lee MC. Proximal tibial anterior open-wedge oblique osteotomy: A novel technique to correct genu recurvatum. *Knee* 2017;24:345-353.
3. Gwinner C, Weiler A, Roider M, Schaefer FM, Jung TM. Tibial slope strongly influences knee stability after posterior cruciate ligament reconstruction: A prospective 5- to 15-year follow-up. *Am J Sports Med* 2016;45:355-361.
4. Bernhardson AS, Aman ZS, DePhillipo NN, Dornan GJ, Storaci HW, Brady AW, et al. Tibial slope and its effect on graft force in posterior cruciate ligament reconstructions. *Am J Sports Med* 2019;47:1168-1174.
5. Deng X, Hu H, Liu W, Zhu L. Clinical application of biplanar high tibial osteotomy for varus knee osteoarthritis and posterior cruciate ligament injuries with flattened tibial slope. *Asian J Surg* 2021;44:918-920.
6. Dean RS, Larson CM, Waterman BR. Posterior tibial slope: Understand bony morphology to protect knee cruciate ligament grafts. *Arthroscopy* 2021;37:2029-2030.
7. Morgan PM, LaPrade RF, Wentorf FA, Cook JW, Bianco A. The role of the oblique popliteal ligament and other structures in preventing knee hyperextension. *Am J Sports Med* 2010;38:550-557.
8. Sonnery-Cottet B, Mogos S, Thaunat M, Archbold P, Fayard J-M, Freychet B, et al. Proximal tibial anterior closing wedge osteotomy in repeat revision of anterior cruciate ligament reconstruction. *Am J Sports Med* 2014;42:1873-1880.
9. Bernhardson AS, DePhillipo NN, Daney BT, Kennedy MI, Aman ZS, LaPrade RF. Posterior tibial slope and risk of posterior cruciate ligament injury. *Am J Sports Med* 2019;47:312-317.
10. Gaskill TR, Pierce CM, James EW, LaPrade RF. Anterolateral proximal tibial opening wedge osteotomy to treat symptomatic genu recurvatum with valgus alignment: A case report. *JBJS Case Connector* 2014;4.