

Technical Note

Tibial Tubercle Preserving Anterior Closing Wedge Proximal Tibial Osteotomy and ACL Tunnel Bone Grafting for Increased Posterior Tibial Slope in Failed ACL Reconstructions

Edward R. Floyd, M.D., Gregory B. Carlson, M.D., Jill Monson, P.T., O.C.S., and Robert F. LaPrade, M.D., Ph.D.

Abstract: Anterior cruciate ligament reconstruction (ACLR) failure is multifactorial, but it is known that increased posterior tibial slope (PTS) leads to a greater likelihood of ACLR failure. This technical note describes the senior author's technique for performing an anterior closing wedge proximal tibial osteotomy, in which the osteotomy is made proximal to the tibial tubercle. This procedure is the first part of a staged surgery for patients with multiple failed ACLRs and increased sagittal plane PTS. Debridement of osteolytic reconstruction tunnels with bone grafting is also undertaken in preparation for a second-stage revision ACLR.

Introduction

A combination of increased tibial slope and younger age have been associated with a higher risk of failure for anterior cruciate ligament (ACL) reconstruction. Salmon et al. found that adolescents with a tibial slope of $>12^\circ$ were 11 times more likely to

rupture their ACL graft than adults with tibial slope $<12^\circ$ over 20 years.¹ Biomechanical studies have suggested that a higher posterior tibial slope (PTS) contributes to increased anterior tibial translation (ATT) and torque under axial loading.²⁻⁵ Bernhardson et al. demonstrated in vitro evidence that ACL graft forces increase linearly with increasing posterior tibial slope.⁶ Samuelson et al. reported further that increased ATT after ACL reconstruction (ACLR) is potentiated by concurrent posterior medial meniscal root tears.⁷ A high incidence of increased PTS has also been reported in patients with lateral meniscal posterior root tears simultaneous with ACL injury.⁸ Several authors have described procedures to correct tibial slope with anterior closing wedge proximal tibial osteotomy (PTO) for

From the Twin Cities Orthopedics, Edina-Crosstown, Edina, Minnesota, U.S.A. (E.R.F., G.B.C., R.F.LaP.); Georgetown University School of Medicine, Washington, D.C., U.S.A. (E.R.F.); and Training Haus, Twin Cities Orthopedics, Eagan-Viking Lakes, Minnesota, U.S.A. (J.M.).

The authors report the following potential conflicts of interest or sources of funding: R.F.LaP. reports personal fees from Arthrex, Smith & Nephew, and Ossur. He has received grants from Ossur and Smith & Nephew, all outside the submitted work. He has received royalties from Arthrex, Ossur, and Smith & Nephew. He is a paid consultant for Arthrex, Ossur, Smith & Nephew, and Linvatec. He serves on the editorial boards of American Orthopaedic Society for Sports Medicine, Journal of Experimental Orthopaedics, and Knee Surgery, Sports Traumatology, Arthroscopy and serves on the committees of American Orthopaedic Society for Sports Medicine, Arthroscopic Association of North America, and The International Society of Arthroscopy, Knee Surgery and Orthopaedic Sports Medicine. Full ICMJE author disclosure forms are available for this article online, as [supplementary material](#).

Received April 13, 2021; accepted May 26, 2021.

Address correspondence to Robert F. LaPrade, M.D., Ph.D., Twin Cities Orthopedics, Edina-Crosstown, 4010 W. 65th St. Edina, MN 55435-1706, U.S.A. E-mail: laprademdphd@gmail.com

© 2021 by the Arthroscopy Association of North America. Published by Elsevier. This is an open access article under the CC BY-NC-ND license (<http://creativecommons.org/licenses/by-nc-nd/4.0/>).

2212-6287/21601

<https://doi.org/10.1016/j.eats.2021.05.026>

Table 1. Indications for Proximal Tibial Closing Wedge Osteotomy

Indications	Contraindications
Increased Posterior tibial slope $>12^\circ$	PCL deficiency
Recurrent instability after ACL reconstruction	Coronal plane malalignment (varus or valgus $>10^\circ$), knee hyperextension $>10^\circ$
High-grade (3+) Lachman and/or pivot-shift in the setting of multiple failed ACL reconstructions	Grade IV Kellgren-Lawrence osteoarthritis, i.e., large osteophytosis, marked sclerosis, deformity, and joint space collapse

ACL, anterior cruciate ligament; PCL, posterior cruciate ligament.

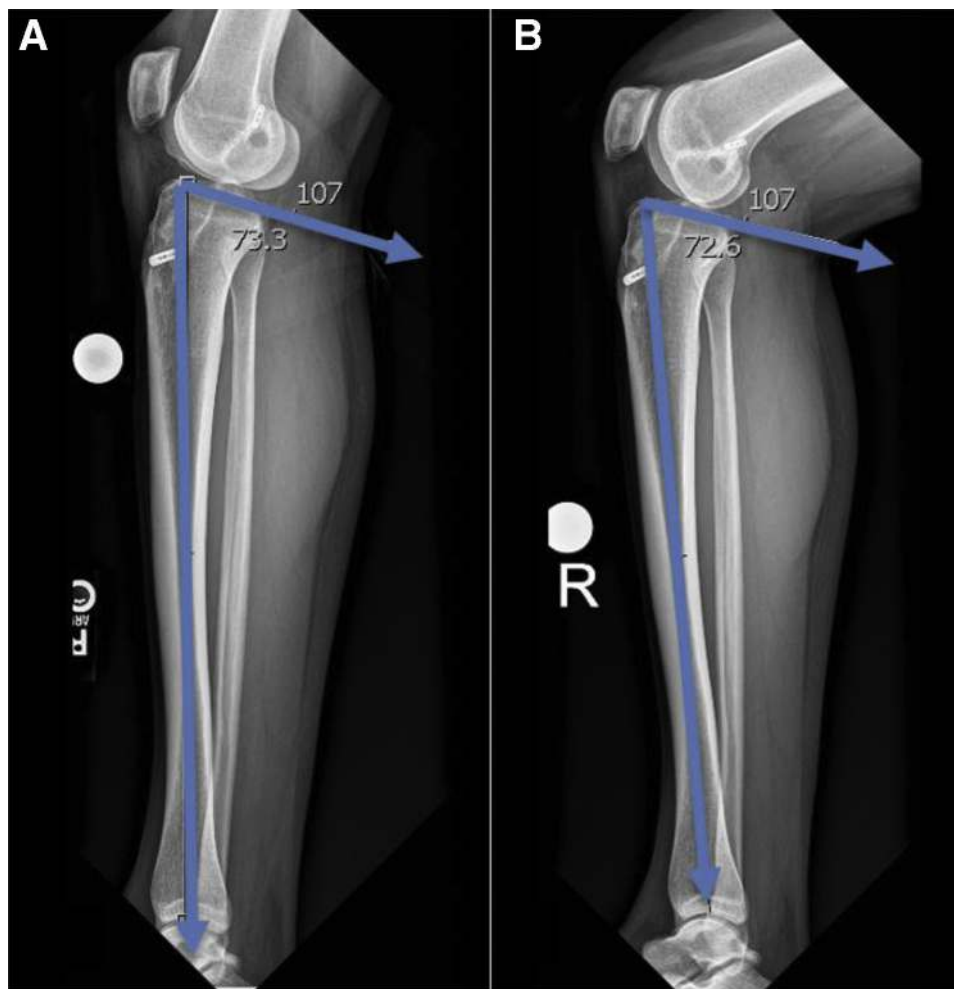


Fig 1. Posterior tibial slope (PTS) is measured on a lateral standard or long-leg radiograph. In this case, posterior slope is approximately 17° , calculated by subtracting the tibial slope angle (seen above as 73.3) from 90° . Increased PTS is thought to lead to anterior tibial translation and put stress on anterior cruciate ligament reconstructions, increasing the risk for reconstruction failure. (A) Lateral knee view in extension. (B) Lateral knee view in flexion.

Table 2. Pearls and Pitfalls

Pearls	Pitfalls
Presence of explosive Lachman or pivot-shift may indicate presence of concomitant pathology, for example, ACL + lateral meniscus root, ramp tear, etc.	Assistance is required to access previous femoral tunnels, to ensure the patient is positioned so that the knee can be maximally flexed.
Surgical approach is performed first to identify structures anteriorly prior to arthroscopy to prevent fluid extravasation.	Anterior osteotomy poses a potential risk to popliteal neurovascular bundle; exercise caution to maintain posterior tibial cortex and use fluoroscopic guidance for pin placement. The extensor mechanism could be injured during the osteotomy if not protected with retractors.
Subperiosteally elevate the anterior compartment laterally to the proximal tibiofibular joint laterally and medially to posteromedial tibial cortex, to allow for good soft tissue closure around the osteotomy.	Lack of aiming guide may lead to a nonparallel cut.
Thoroughly expose tibial tubercle and margins of patellar tendon to ensure protection of extensor mechanism.	Complete the posterior osteotomy with curettes instead of the saw and verify fluoroscopically that the osteotomy has no bony bridges.
Place inferior pins parallel to joint and use ruler to measure start site of superior pins, according to the desired height of osteotomy.	Gently close the osteotomy to decrease the risk of fracture of the posterior tibial cortex.
Verify pin position fluoroscopically before initiating osteotomy.	Angle fixation staples to avoid ACL reconstruction tunnels and intra-articular penetration.
Closing wedge osteotomy cut needs to include entire medial and lateral cortex to ensure appropriate posterior hinge.	
ACL, anterior cruciate ligament.	

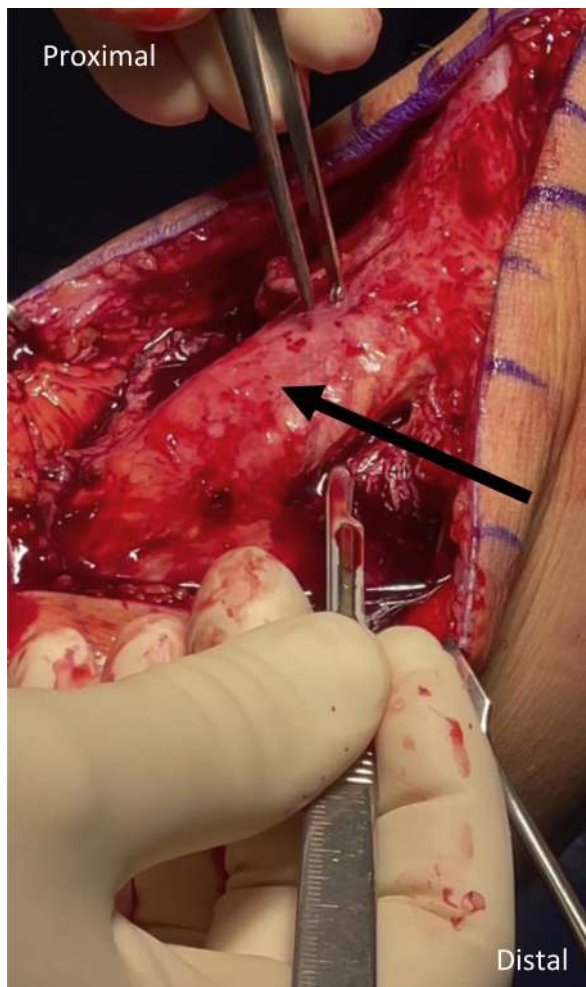


Fig 2. Exposure of the patellar tendon: In patients with increased posterior tibial slope $>12^\circ$, a proximal tibial closing wedge osteotomy may be pursued to increase the likelihood of success for anterior cruciate ligament reconstruction. After making an anterior incision and developing generous medial and lateral subcutaneous flaps, the extensor mechanism is exposed. A closing wedge procedure can be accomplished without osteotomy of the tibial tubercle, but to do so, great care must be taken to adequately expose the extensor mechanism and protect the patellar tendon during wedge excavation and closure. Black arrow denotes patellar tendon, left knee.

revision ACLR.⁹⁻¹¹ Here, we describe a tibial tubercle-sparing procedure that may improve morbidity and recovery time.

Preoperative Planning

A slope of $<5^\circ$ may predispose the patient to posterior cruciate ligament injury;¹¹ therefore, an ideal corrected tibial slope will be $6-8^\circ$ (Table 1).^{9,11} It has been estimated that 1 mm of anterior tibial resection equates to 1° of PTS correction (e.g., 9° slope correction equates to a 9-mm resection in the patient in this report).⁹⁻¹² Lateral standard or long-leg radiographs (Fig 1) are used to measure tibial slope and evaluate prior ACLR

femoral and tibial tunnels. Reconstruction tunnel osteolysis or malposition, which could interfere with revision anatomic tunnel placement is examined with a CT scan. Tunnels enlarged more than 12 mm should be considered for bone grafting. Six to seven months of healing time is necessary for the osteotomy and bone graft to heal sufficiently to proceed with the osteotomy fixation hardware removal and re-revision ACLR and meniscal root repair.

Patient Positioning and Anesthesia

The operative technique is detailed in Video 1. The patient is placed in the supine position, general anesthesia is induced, and a tourniquet is inflated on the operative side on the upper thigh. Bilateral knee examination, including range of motion, Lachman, pivot-shift, varus and valgus stress, posterior drawer and dial testing are performed. The approach and exposure is made before arthroscopy (Table 2).

Surgical Approach

A longitudinal anterior midline incision is made, incorporating any previous incision and extending just proximal to the patella and distal to the tibial tubercle by 3-4 cm. Full-thickness subcutaneous flaps are developed medially and laterally. The tibial tubercle and patellar tendon margins are identified and a Z-retractor placed under the tendon to protect the extensor mechanism (Fig 2). The tissues overlying Gerdy's tubercle are subperiosteally elevated from the inferior aspect of their insertion for ~ 1 cm proximally, and the dissection is carried posteriorly to the anterior margin of the proximal tibiofibular joint. The anterior compartment musculature is also subperiosteally elevated at its superior margin to improve visualization. Subperiosteal dissection is performed medially and deep into the MCL to the posteromedial aspect of the tibia (Fig 3).

Then, medial and lateral parapatellar tendon portals are created; diagnostic arthroscopy is performed with chondroplasty, as appropriate. The menisci are carefully examined and tears requiring repair are documented during the second-stage surgery. The remnant ACL graft and previous reconstruction tunnels are debrided. The knee may need to be maximally flexed to gain access to the femoral tunnel. A straight and curved shaver (Dyonics, Smith & Nephew, London, UK), curette, and rasp are used to thoroughly clean the scar tissue in the femoral tunnel until bleeding bone margins are obtained. The tibial tunnel is identified, and a guide pin is placed up the tunnel and then overreamed with a 10-mm acorn reamer. The tunnel is cleared of scar tissue until bleeding bone is achieved to complete the tunnel preparation for bone grafting.

The leg holder is now removed sterilely, and the foot of the bed is leveled and re-draped. Under fluoroscopic

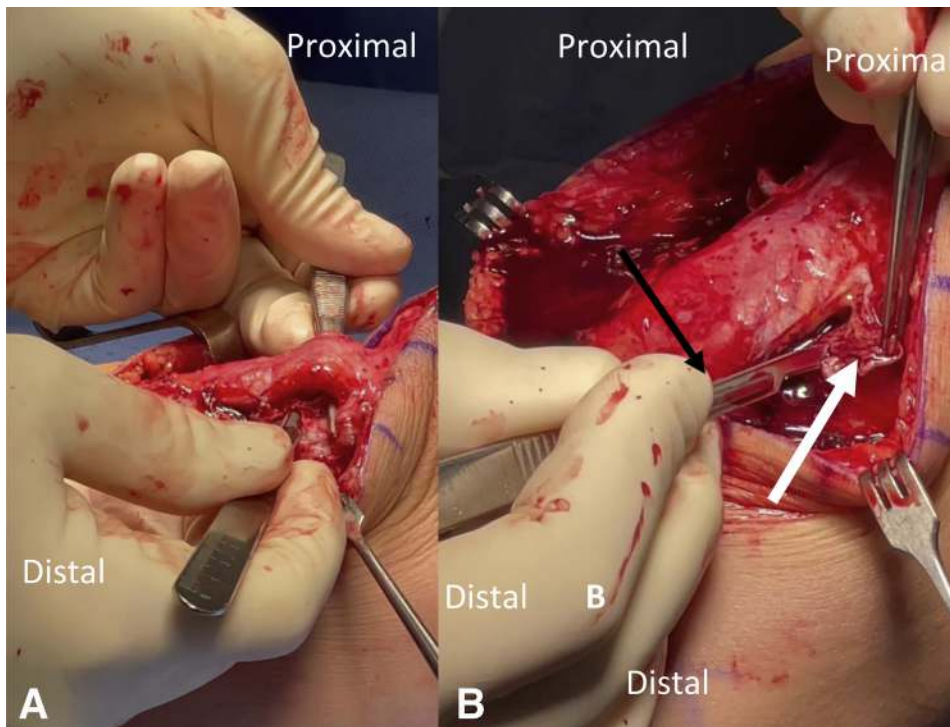


Fig 3. Elevation of subperiosteal flaps. Creation of a proximal tibial closing wedge osteotomy requires the preservation of soft tissue attachments superficial to the osteotomy site. Incision of the periosteum is made in the midline, and the overlying tissue is gently elevated medially to the posteromedial aspect and laterally to the proximal tibiofibular joint. Elevation is accomplished with a Cobb elevator and scalpel. (A) The surgeon protectively elevates the patellar tendon of a left knee with forceps and a Z-retractor, while elevating a lateral periosteal flap. (B) The surgeon holds the flap with forceps and uses a scalpel to develop the flap. White arrow denotes subperiosteal flap with overlying soft tissue.

guidance, two guide pins are placed parallel to the joint line, just above the level of the tibial tubercle (Fig. 4). The proximal extent of the osteotomy to achieve

desired slope correction is then measured and marked. Two additional K-wires are drilled on the anterior tibia, proximal to the first two guides, entering through the

Fig 4. Proximal tibial closing wedge osteotomy. (A) After carefully elevating subperiosteal soft tissue flaps to expose the underlying tibial cortex, guide pins are drilled parallel to the joint line from anterior to posterior at the inferior margin of the desired osteotomy. (B) Intraoperative fluoroscopy is used to verify the correct position of the guide pins, entering the anterior tibial cortex and halting at the posterior cortex.

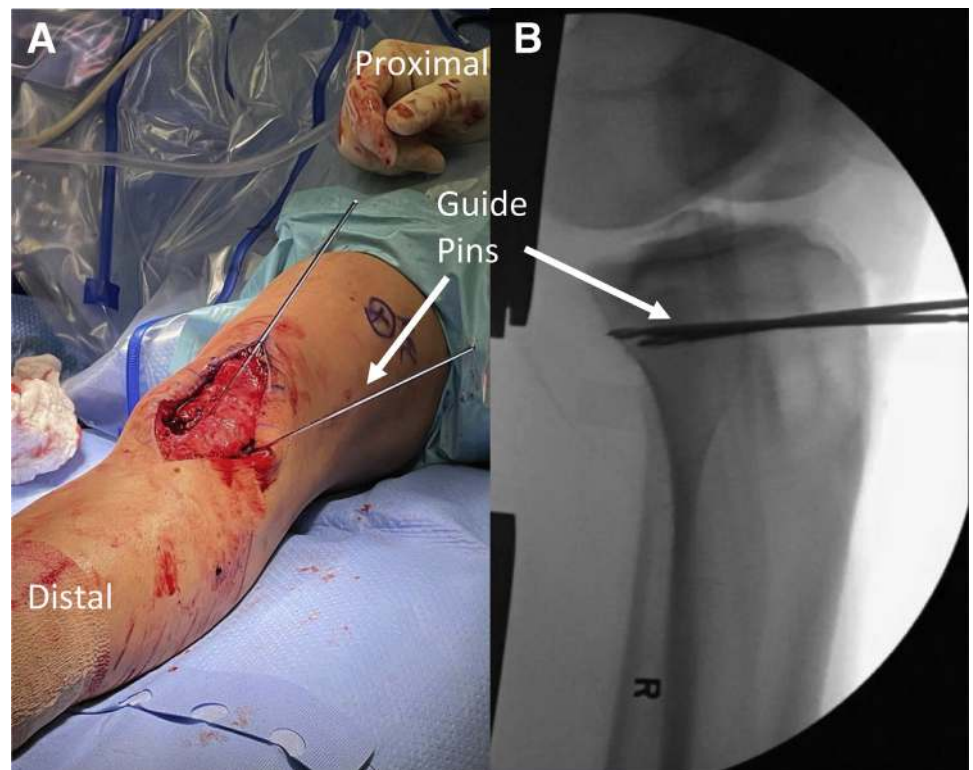


Fig 5. Proximal tibial closing wedge osteotomy is used to decrease the posterior tibial slope (PTS), a significant risk factor for anterior cruciate ligament reconstruction failure. Two guide pins are inserted parallel to the joint line at the inferior margin of the desired extent of osteotomy. (A) An additional two guide pins are then inserted proximal to these at the superior extent of the desired osteotomy. A ruler (white arrow) is used to verify at a distance of 1 mm per 1° of desired PTS correction. (B) The superior pins are angled to converge with the inferior pins at the posterior tibial cortex. The above images depict a left knee.

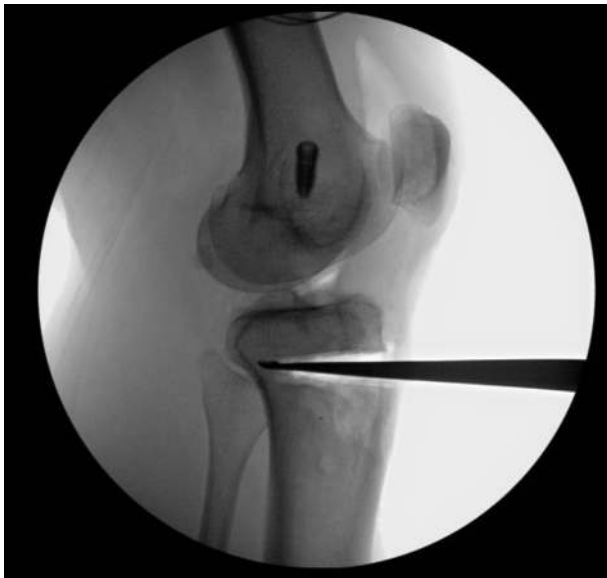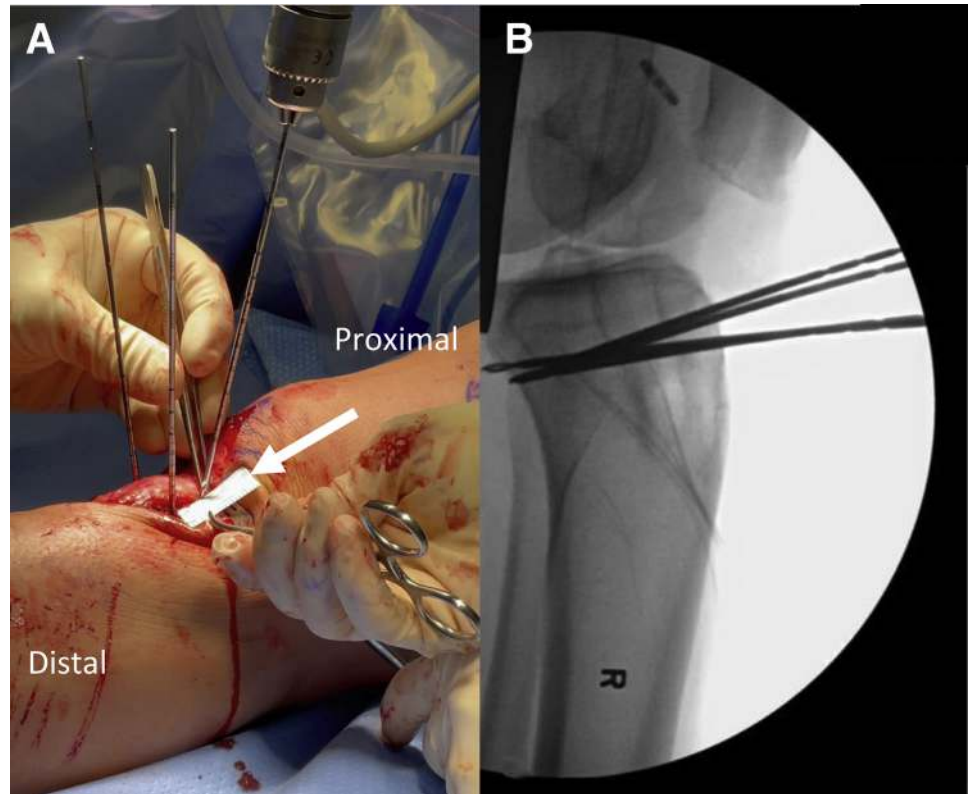


Fig 6. Fluoroscopic image of completed osteotomy. An anterior closing wedge proximal tibial osteotomy to decrease tibial slope is seen in this image. After completing bone resection using ACL saw, rongeurs, and curettes, a large curette is placed in the osteotomy site to fluoroscopically verify the extent of resection. The osteotomy wedge should extend to the anterior aspect of the posterior tibial cortex without violating the posterior cortex. This will allow closure of the osteotomy along a posterior cortical hinge.

anterior tibial cortex and angled to converge with the first two pins at the posterior tibial cortex. Pin positions are verified fluoroscopically (Fig. 5).

An ACL patellar tendon graft harvest saw blade (9 × 25 mm, Stryker, Kalamazoo, MI) is used to make an anterior tibial cortical cut for the osteotomy (Fig. 6). A retractor is placed beneath the patellar tendon to protect it throughout the osteotomy. Medium curettes can then be used to remove the bone wedge and remaining bone. Small rongeurs or small osteotomes are used to remove bone at the far posteromedial and posterolateral aspects of the tibia. The osteotomy includes the entire medial and lateral tibial cortex to allow for an appropriate posterior hinge. A curette is used on the posterior cortex under fluoroscopy to ensure no bony bridges remain. The osteotomy can now be gently hinged closed by slowly hyperextending the knee, and a large bump placed behind the heel to maintain the reduction. A large Richards staple (Smith & Nephew, London, UK) is placed laterally, and two staples are placed medially to secure the osteotomy, taking care to avoid the tibial ACL tunnels and avoid intra-articular penetration. Hardware position is verified fluoroscopically (Fig. 7).

Finally, the ACL tunnels are bone-grafted. Autologous bone from the osteotomy is packed into the tibial

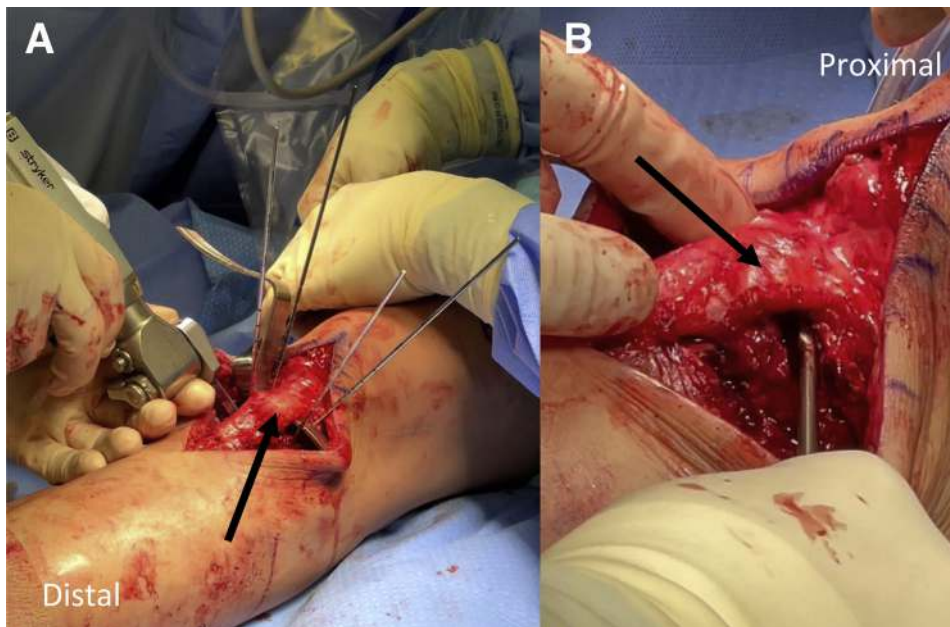


Fig 7. Completing a proximal tibial closing wedge osteotomy. After drilling guide pins at the superior and inferior margins of the desired osteotomy, an ACL saw (A) is used to begin the osteotomy, cutting colinear with the planes between the inferior and superior pairs of guide pins. A Z-retractor (A) is used to protect the patellar tendon, while the saw removes bone posterior to the tendon. (B) A small curette is then used to finish removing bone in the path of the closing wedge. This osteotomy wedge will then be closed to decrease posterior tibial slope (PTS); increased PTS is a major risk factor in anterior cruciate ligament reconstruction failure. Black arrows denote patellar tendon.

tunnel and any gaps in the osteotomy. The arthroscope is then placed back into the knee, and Opteform allograft bone matrix (Exactech, Gainesville, FL) is packed into the femoral tunnel. Final AP and lateral fluoroscopic radiographs are obtained to confirm hardware and graft placement (Fig. 8). Deep tissues are closed with 0 Vicryl (Ethicon, Somerville, NJ), taking care to close the previously raised subperiosteal flaps. Subcutaneous tissue is closed with 2-0 Vicryl and

3-0 Monocryl (Ethicon, Somerville, NJ) is used for skin closure. Steri-Strips are applied to the skin, followed by a sterile dressing and a knee immobilizer in full extension.

Rehabilitation

Postoperatively, the patient is non-weightbearing for 8 weeks with crutches and a knee immobilizer. Cryotherapy is recommended to minimize pain and swelling

Fig 8. Securing the osteotomy, bone grafting tunnels. After removing bone from the osteotomy site, the wedge is very carefully closed with a bump placed under the heel. (A) The now-closed osteotomy is secured with several large staples. (B) In patients who will be receiving second-stage anterior cruciate ligament (ACL) reconstruction following the osteotomy, bone grafting of ACL tunnels may use a combination of bone fragments from the osteotomy and allograft bone matrix. The bone fragments are packed into the osteotomy site with forceps, and into the debrided tibial and femoral (white arrow) tunnels.

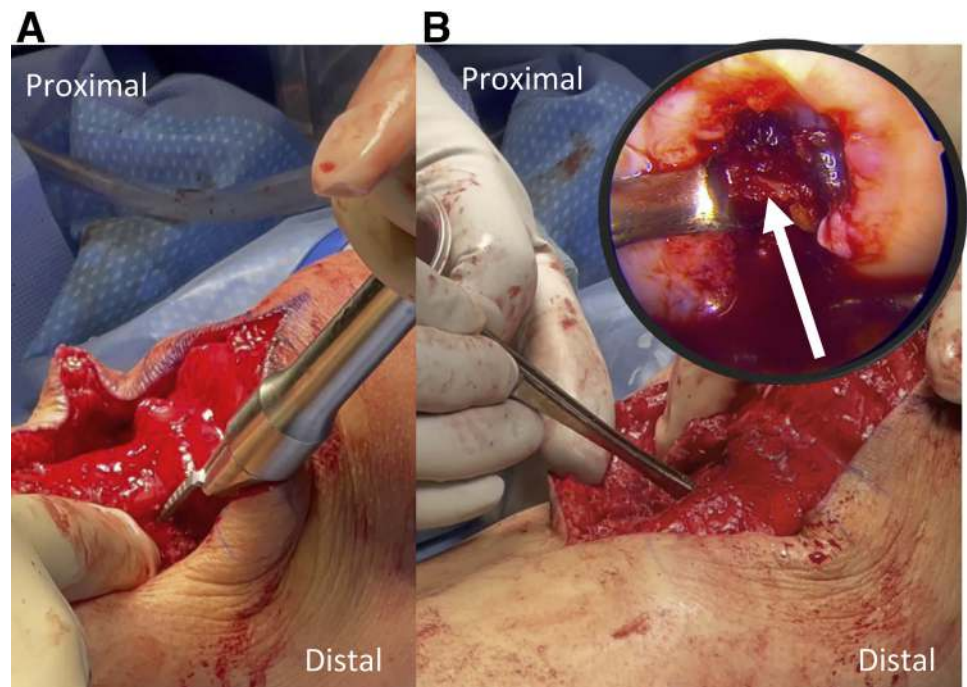
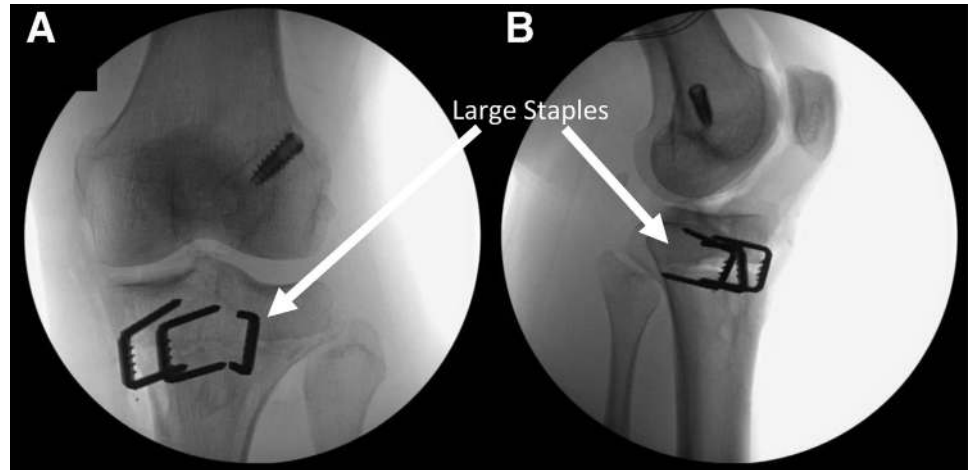


Fig 9. After proximal tibial anterior closing wedge osteotomy, large staples hold the wedge closed and in compression for 6 months before revision ACL reconstruction. (A) Anteroposterior (AP) and lateral (B) view of a right knee are shown above after closing wedge osteotomy. Autologous bone from the osteotomy or allograft used for bone grafting anterior cruciate ligament reconstruction tunnels can be additionally packed in any gaps at the osteotomy site.



(Game Ready, Concord, CA). Physical therapy is initiated immediately after discharge, with emphasis on patient education, symptom control, immediate range-of-motion (ROM), and quadriceps muscle activation. Hyperextension stretching is discouraged to limit the potential development of increases in heel height. Knee flexion up to 90° is permitted in the first 2 weeks, and then it is increased gradually until full flexion range of motion (ROM) is restored. Deep vein thrombosis prophylaxis consists of compression hose and enoxaparin for 2 weeks, then transitions to aspirin until initiation of weightbearing. Radiographs are obtained at 8 weeks to evaluate whether healing is sufficient to permit partial weightbearing at one-quarter body weight, then advanced gradually to full weightbearing by 12 weeks. At 3 months, repeat radiographs evaluate whether the patient can be weaned off crutches. At the 6-month mark, repeat radiographs are obtained to evaluate whether the patient has adequately healed from the osteotomy (Fig. 9) and bone graft tunnels to proceed with a re-revision ACL reconstruction with lateral meniscal root repair.

Discussion

In the setting of repeat ACLR failure, underlying factors, such as increased PTS or concomitant meniscal tears, including ramp or root tears, should be considered. (Table 3). The method detailed here describes anterior closing wedge PTO with osteotomy performed proximal to the tibial tubercle (TT), thereby making the procedure less morbid and the postoperative recovery easier, and decreasing the risk of TT delayed union or nonunion.^{13,14} Previous technique descriptions distalize the TT, while making a cut through the anatomic location of the tubercle, and may adjust the extensor mechanism tension, according to the size of the anterior wedge resection.^{9,11} Furthermore, our technique differs from the TT-preserving technique described by Queiros et al. in that our technique performs the osteotomy proximal to the TT, whereas their technique performs the osteotomy posterior to the TT, preserving the TT's distal insertion.⁶ An a recent retrospective review of 109 revision ACLR patients reinforced the correlation of increased tibial slope as a risk factor for revision, and patients with PTS > 12° were treated with biplanar

Table 3. Advantages and Disadvantages of Proximal Tibial Closing Wedge Osteotomy

Advantages	Disadvantages
Allows for correction of sagittal plane tibial slope	Technically demanding procedure
Tibial tubercle is preserved, making the procedure less morbid, the recovery easier, and decreasing the risk of tibial tubercle osteotomy non-union.	Potential to increase knee hyperextension following osteotomy
Can impart additional stability to the knee despite of ACL-deficiency	Requires 8-week period of non-weightbearing
Anterior approach allows for simultaneous bone grafting of previous ACL reconstruction tunnels	Risk of injury to popliteal neurovascular structures during guide pin drilling and osteotomy wedge resection

ACL, anterior cruciate ligament.

medial PTO or anterior closing wedge PTO for re-revision.¹⁵ In the experience of the senior author, secondary knee hyperextension has not been a complication if hyperextension is avoided in the early postoperative period. This technical note describes the senior author's technique for an anterior closing wedge PTO to reduce the sagittal plane posterior tibial slope for a patient with increased posterior tibial slope and failed ACLR, while also preserving the tibial tubercle.

References

1. Salmon LJ, Heath E, Akrawi H, Roe JP, Linklater J, Pinczewski LA. 20-Year outcomes of anterior cruciate ligament reconstruction with hamstring tendon autograft: The catastrophic effect of age and posterior tibial slope. *Am J Sports Med* 2018;46:531-543.
2. Feucht MJ, Mauro CS, Brucker PU, Imhoff AB, Hinterwimmer S. The role of the tibial slope in sustaining and treating anterior cruciate ligament injuries. *Knee Surg Sports Traumatol Arthrosc* 2013;21:134-145.
3. Fening SD, Kovacic J, Kambic H, McLean S, Scott J, Miniaci A. The effects of modified posterior tibial slope on anterior cruciate ligament strain and knee kinematics: A human cadaveric study. *J Knee Surg* 2008;21:205-211.
4. Giffin JR, Vogrin TM, Zantop T, Woo SL, Harner CD. Effects of increasing tibial slope on the biomechanics of the knee. *Am J Sports Med* 2004;32:376-382.
5. Bates NA, Nesbitt RJ, Shearn JT, Myer GD, Hewett TE. Posterior tibial slope angle correlates with peak sagittal and frontal plane knee joint loading during robotic simulations of athletic tasks. *Am J Sports Med* 2016;44:1762-1770.
6. Bernhardson AS, Aman ZS, Dornan GJ, et al. Tibial slope and its effect on force in anterior cruciate ligament grafts: Anterior cruciate ligament force increases linearly as posterior tibial slope increases. *Am J Sports Med* 2019;47:296-302.
7. Samuelsen BT, Aman ZS, Kennedy MI, et al. Posterior medial meniscus root tears potentiate the effect of increased tibial slope on anterior cruciate ligament graft forces. *Am J Sports Med* 2020;48:334-340.
8. Bernholt D, DePhillipo NN, Aman ZS, Samuelsen BT, Kennedy MI, LaPrade RF. Increased posterior tibial slope results in increased incidence of posterior lateral meniscal root tears in ACL reconstruction patients. *Knee Surg Sports Traumatol Arthrosc* In press. doi:10.1007/s00167-021-06456-4.
9. Sonnery-Cottet B, Mogos S, Thaunat M, et al. Proximal tibial anterior closing wedge osteotomy in repeat revision of anterior cruciate ligament reconstruction. *Am J Sports Med* 2014;42:1873-1880.
10. Queiros CM, Abreu FG, Moura JL, et al. Anterior closing-wedge osteotomy for posterior slope correction with tibial tubercle preservation. *Arthrosc Tech* 2019;8:e1105-e1109.
11. DePhillipo NN, Kennedy MI, Dekker TJ, Aman ZS, Grantham WJ, LaPrade RF. Anterior closing wedge proximal tibial osteotomy for slope correction in failed ACL reconstructions. *Arthrosc Tech* 2019;8:e451-e457.
12. Dejour D, Saffarini M, Demey G, Baverel L. Tibial slope correction combined with second revision ACL produces good knee stability and prevents graft rupture. *Knee Surg Sports Traumatol Arthrosc* 2015;23:2846-2852.
13. Johnson AA, Wolfe EL, Mintz DN, Demehri S, Shubin Stein BE, Cosgarea AJ. Complications after tibial tuberosity osteotomy: Association with screw size and concomitant distalization. *Orthop J Sports Med* 2018;6:2325967118803614.
14. Payne J, Rimmke N, Schmitt LC, Flanigan DC, Magnussen RA. The incidence of complications of tibial tubercle osteotomy: A systematic review. *Arthroscopy* 2015;31:1819-1825.
15. Ziegler CG, DePhillipo NN, Kennedy MI, Dekker TJ, Dornan GJ, LaPrade RF. Beighton score, tibial slope, tibial subluxation, quadriceps circumference difference, and family history are risk factors for anterior cruciate ligament graft failure: A retrospective comparison of primary and revision anterior cruciate ligament reconstructions. *Arthroscopy* 2021;37:195-205.