



# Increased posterior tibial slope results in increased incidence of posterior lateral meniscal root tears in ACL reconstruction patients

David Bernholt<sup>1</sup> · Nicholas N. DePhillipo<sup>2,3</sup> · Zachary S. Aman<sup>4</sup> · Brian T. Samuelsen<sup>5</sup> · Mitchell I. Kennedy<sup>4</sup> · Robert F. LaPrade<sup>2</sup>

Received: 28 July 2020 / Accepted: 12 January 2021  
© European Society of Sports Traumatology, Knee Surgery, Arthroscopy (ESSKA) 2021

## Abstract

**Purpose** While the association with acute anterior cruciate ligament (ACL) tears has been established, other risk factors and associated pathologies which occur with a concomitant lateral meniscal posterior root tear (LMPRT) are not well defined. The purpose of this study was to compare the risk factors and concomitant pathologies between patients with LMPRT and patients without LMPRTs in the setting of a primary ACL tear.

**Methods** Patients with a LMPRT identified at the time of primary ACL reconstruction by a single surgeon were identified. These patients were matched by age and sex to patients undergoing primary ACL reconstruction who were not found to have lateral meniscus root tears (control group) in a 1:1 ratio. Lateral posterior tibial slope (PTS), medial PTS, lateral femoral condyle height and depth, lateral tibial plateau depth, and lateral tibial plateau subluxation were measured on MRI. Anteroposterior full-limb alignment radiographs were used to measure the medial proximal tibia angle (MPTA), the mechanical lateral distal femoral angle (mLDFA), and the mechanical weightbearing axis for the injured extremity.

**Results** One-hundred three patients were included in both the LMPRT group and the matched control group. Patients with a LMPRT had a significantly steeper lateral PTS ( $9.1^\circ$  vs.  $7.0^\circ$ ,  $p=0.001$ ), a steeper medial PTS ( $7.0^\circ$  vs.  $6.0^\circ$ ,  $p=0.03$ ), and a greater lateral-to-medial slope asymmetry ( $2.0^\circ$  vs.  $1.0^\circ$ ,  $p=0.001$ ). There were no differences in lateral femoral condyle depth or height, lateral tibial plateau depth, lateral tibial plateau subluxation, MPTA, mLDFA, or mechanical weightbearing axis between groups. There was a significantly increased incidence of medial meniscus ramp lesions in patients with lateral meniscus posterior root tears compared with controls (34.0% vs. 15.5%, odds ratio: 2.8,  $p=0.002$ ). There were no associations with concomitant ligament injuries, medial meniscus root tears, or non-ramp tears based on case/control grouping.

**Conclusion** In conclusion, LMPRTs in the setting of primary ACL injuries were associated with significantly increased lateral and medial PTSs, and increased asymmetry between lateral and medial PTSs. In addition, clinicians should be aware of the increased incidence of concurrent medial meniscal ramp lesions in patients with LMPRTs. Knowledge of these associations helps guide clinical decision-making and counselling of patients in the setting of ACL tears with concomitant LMPRTs.

**Level of evidence** IV.

**Keywords** Posterior lateral meniscus root tear · Tibial slope · MRI · ACL tear

✉ Robert F. LaPrade  
Laprademphd@gmail.com

<sup>1</sup> Campbell Clinic Orthopaedics, University of Tennessee Health Science Center, Memphis, TN, USA

<sup>2</sup> Twin Cities Orthopedics, 4010 West 65th Street, Edina, MN 55435, USA

<sup>3</sup> Department of Sports Medicine, Oslo Sports Trauma Research Center, Norwegian School of Sport Sciences, Oslo, Norway

<sup>4</sup> Steadman Philippon Research Institute, Vail, CO, USA

<sup>5</sup> Beth Israel Lahey Health, Boston, MA, USA

## Introduction

Lateral meniscal posterior root tears (LMPRT) are common concomitant injuries in the setting of anterior cruciate ligament (ACL) tears, reportedly occurring in 8–15% of patients [2, 3, 6, 7, 18]. These meniscal injuries are important to recognize because the studies have demonstrated both deterioration of the lateral compartment and progression of arthritis when left untreated [23]. In addition, untreated LMPRTs also increase instability of ACL-deficient knees [9, 16, 23]. LMPRTs can be difficult to diagnose on MRI with lower

sensitivity compared with the detection of other meniscal tears [1, 17]. While the association with acute ACL tears is well-established, other associated pathologies of concomitant ACL and LMPRT injuries are not well-defined. Knowing additional pathologies or radiologic findings associated with LMPRTs may help the clinician to have a higher index of suspicion for the presence of these meniscus tears.

Radiologic risk factors for LMPRTs have been identified in small case series [6, 14, 21], including associations between LMPRTs with increased lateral posterior tibial slope (PTS) [14, 21], increased difference between lateral and medial PTS [14], and increased tibia varus [21]. An additional study demonstrated an increased risk of LMPRT in male patients that sustain injuries from contact [6]. However, two of these studies included only 20 patients with LMPRTs [6, 14] while the third study had only ten patients with LMPRTs [21]. One large database study did examine the demographic and clinical risk factors for LMPRTs, without examining the radiologic risk factors, and found an increased incidence of LMPRT with contact sports and the presence of a concomitant medial meniscus tear [22]. Thus, given the relatively small amount of data regarding radiologic risk factors for LMPRTs within the current literature, additional studies are necessary to better identify these risk factors.

The purpose of this study was to compare knee alignment and concomitant pathologies between patients with LMPRTs and patients without LMPRTs in the setting of primary ACL tears to determine risk factors for LMPRTs that should raise clinical suspicion for these injuries. The null hypothesis considered was that there would be no difference in tibial plateau morphology, lower extremity alignment, BMI, or ligamentous and medial meniscal injury between ACL tear patients with and without LMPRTs.

## Materials and methods

This study was approved following review from an institutional review board (Vail Health IRB, ID#: 2019-11). The study design was a retrospective case–control study. Demographic information and data from surgical procedure charts were collected on all patients with primary ACL tears with concomitant LMPRTs treated by a single board-certified orthopaedic surgeon (initials blinded for review) between 2010 and 2019. These patients were designated as the case group. Patients with combined ACL and LMPRTs were matched in a one-to-one allocation according to age and gender with patients who are with ACL tears without LMPRTs (control group). For all patients in both case and control groups, pre-operative magnetic resonance imaging (MRI) and standing anteroposterior (AP) full limb alignment radiographs were reviewed. Operative reports were reviewed

and data for concomitant ligament tears and meniscal tears were based upon arthroscopic diagnosis of these injuries. All meniscal tears including root tears and RAMP lesions were diagnosed arthroscopically. There were no exclusion criteria for this study.

## MRI measurements

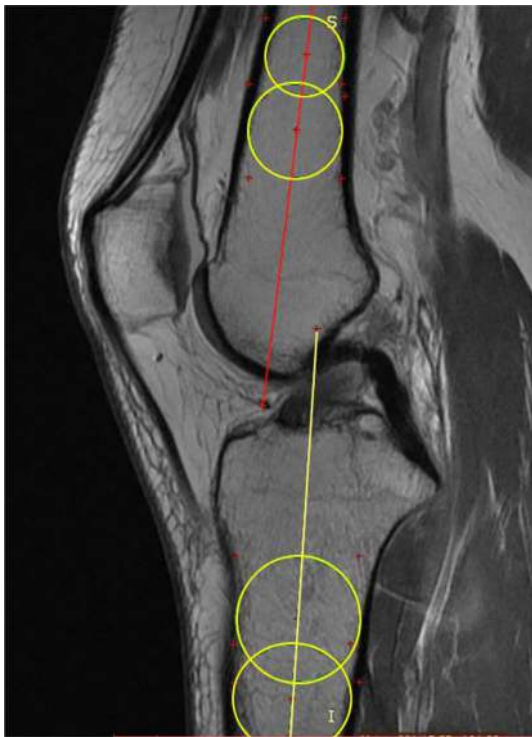Lateral and medial PTS, lateral femoral condyle height and depth, lateral tibial plateau subluxation, and lateral tibial plateau depth were measured using pre-operative knee MRI images. Knee MRIs included both 1.5 T and 3.0 T studies, but were all performed with the patient supine and the knee in an extended position. All measurements were performed by a sports-fellowship trained orthopaedic surgeon (initials blinded for review) with MRI images de-identified to maintain observed blinding. Measurements were performed using RadiAnt Dicom Viewer software (Medixant, Poland) and ImageJ software (LOCI, University of Wisconsin). Three-dimensional multiplanar reconstruction was utilized to ensure sagittal MRI images were in the plane perpendicular to the posterior tibial condylar axis. All MRI measurements were made according to previously validated techniques which have been shown to have good interobserver reliability [10, 12]. All distance and angular measurements could be made to one decimal point, thus all values were reported to the nearest single decimal point.

## Lateral and medial PTS

The PTS of both the lateral and medial tibial plateau was measured using a previously validated technique [12]. The centre sagittal MRI slice demonstrating the tibial PCL attachment and intercondylar eminences was selected to determine the anatomic axis of the tibia. Two best-fit circles were positioned within the tibial shaft, such that the anterior and posterior cortical lines were tangential to the circles. A line connecting the centre of these circles was then drawn to establish the anatomic longitudinal axis of the tibia (Fig. 1). The medial and lateral tibial slopes were then measured as the angle between this longitudinal axis and the subchondral surface of the medial and lateral tibial plateau, respectively (Fig. 2). Intrarater reliability for this measurement was excellent with intraclass correlation coefficient (ICC) of 0.856.

## Lateral tibial plateau subluxation and sagittal plane depth

Lateral tibial plateau subluxation was measured from the sagittal MRI slice at the centre of the lateral tibial plateau from medial to lateral. The technique that was utilized was described by Grassi et al. [10] in which two lines



**Fig. 1** Illustration of tibial and femoral longitudinal axis drawn on the midsagittal MRI slice based upon tibial PCL attachment and presence of intercondylar eminence of tibia. The femoral longitudinal axis line (red) and the tibial longitudinal axis line (yellow) are drawn as a line connecting the midpoints of two best-fit circles in the femoral and tibial shafts, respectively

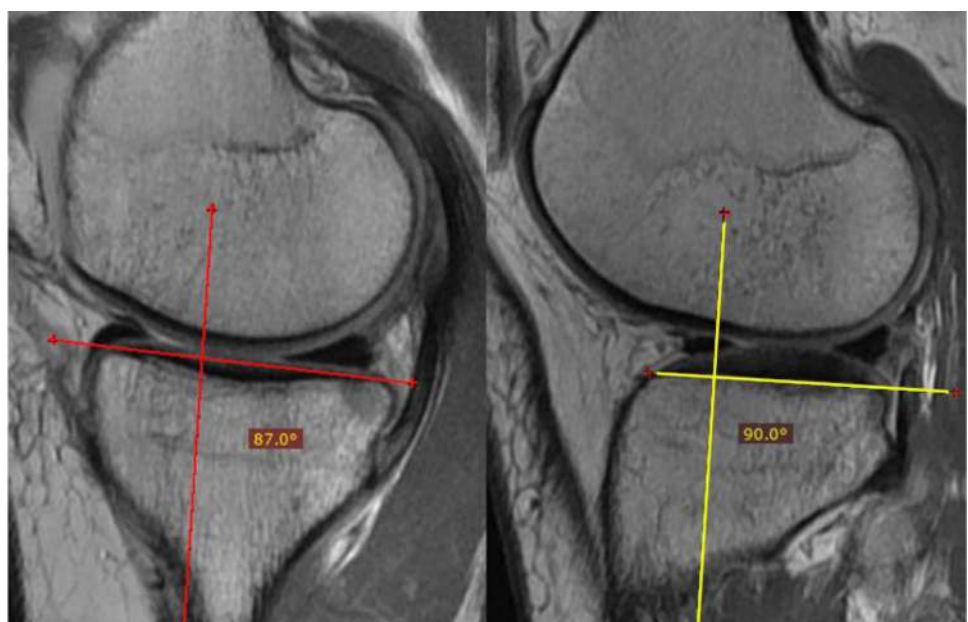
perpendicular to the lateral tibial plateau subchondral surface were drawn, one tangent to the posterior-most aspect

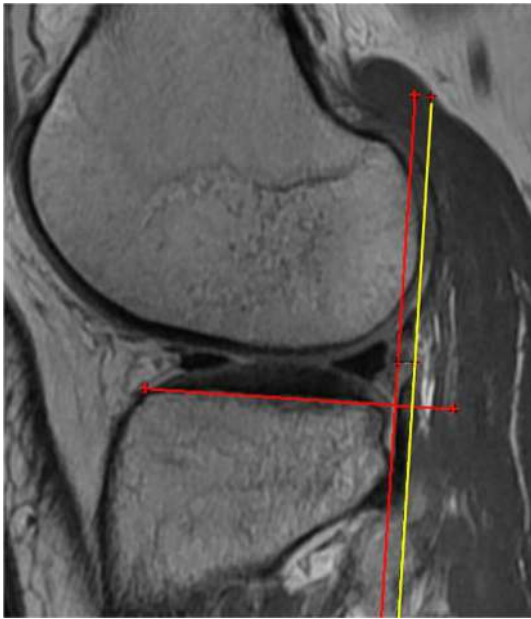of the lateral femoral condyle and one tangent to the posterior-most aspect of the lateral tibial plateau. The distance between these lines was then measured, with positive values representing anterior translation of the lateral tibial plateau relative to the lateral femoral condyle (Fig. 3). Lateral tibial plateau sagittal plane depth was measured from the sagittal MRI slice at the centre of the lateral tibial plateau from medial to lateral. The lateral tibial plateau sagittal plane depth and the lateral tibial plateau articular surface sagittal plane depth were measured using lines parallel to the subchondral surface of the lateral tibial plateau (Fig. 4). Intra-rater reliability for this measurement was excellent with ICC of 0.901.

**Lateral femoral condylar height and depth**

Lateral femoral condylar height and depth were measured from the sagittal MRI slice at the centre of the lateral femoral condyle from medial to lateral. The technique that was utilized was described by Grassi et al. [10] in which (1) the femoral longitudinal axis was established on the mid-sagittal MRI and copied to the MRI sagittal slice at the medial-to-lateral midpoint of the lateral femoral condyle, (2) a line parallel to the femoral longitudinal axis and tangential to the posterior-most aspect of the lateral femoral condyle was drawn, (3) two lines perpendicular to the femoral longitudinal axis were drawn, one tangent to the distal-most aspect of the lateral femoral condyle, and one at the level in which the lateral femoral condyle contacted the posterior tangent line. Lateral femoral condylar sagittal plane depth was measured as the distance between the femoral longitudinal axis and the line parallel to it at the posterior-most aspect of

**Fig. 2** MRI images demonstrating the calculation of the medial PTS (left, red) and the lateral PTS (right, yellow). The angle between the medial or lateral subchondral surface and the longitudinal tibial axis line was calculated for each respective side of the knee. The angle was converted into PTS by subtracting the calculated number from 90, with a negative number representing an anterior tibial slope



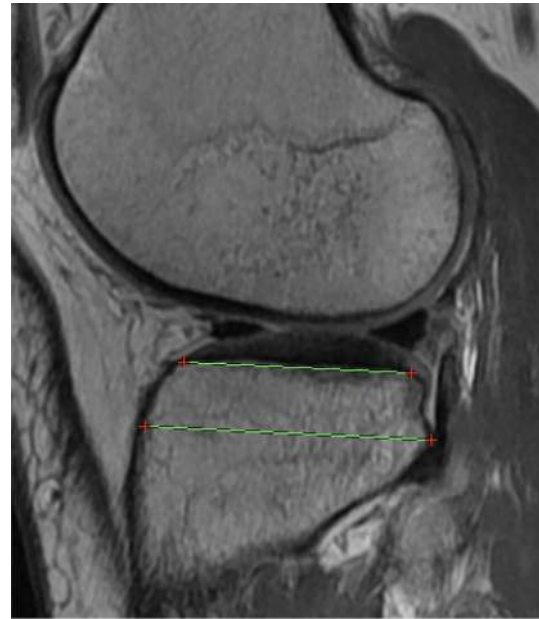


**Fig. 3** MRI sagittal slice at the medial-to-lateral midpoint of the lateral tibial plateau demonstrating calculation of lateral tibial plateau subluxation. Two lines perpendicular to the lateral tibial plateau subchondral surface were drawn, one tangential to the posterior aspect of the lateral tibial plateau (red) and one tangential to the posterior aspect of the lateral femoral condyle (yellow). The distance between these lines was measured to provide a value for lateral tibial plateau subluxation with the positive values indicating anterior translation of the lateral tibial plateau relative to the lateral femoral condyle

the lateral femoral condyle. Lateral femoral condylar sagittal plane depth was measured as the distance between the two lines perpendicular to the femoral longitudinal axis described in step 3 earlier in this paragraph (Fig. 5). Lateral femoral condylar index was calculated as the ratio of height/depth. Intra-rater reliability for lateral femoral condylar index was excellent with ICC of 0.871.

### Radiographic measurements

Weightbearing mechanical axis, medial proximal tibial angle (MPTA), and mechanical lateral distal femoral angle (mLDFA) were measured using pre-operative standing hip-to-ankle long alignment AP radiographs. These radiographs were obtained in standardized fashion with full weightbearing on bilateral lower extremities. Measurements were made by a single observer using PACS system. The weightbearing mechanical axis was calculated as a percentage of where the hip-to-ankle mechanical weightbearing line crossed the tibial plateau from medial to lateral compared with the total width of the tibial plateau. First, a line was drawn from the centre of the femoral head to the centre of the ankle joint. Next, the distance from the medial aspect of the tibial plateau to the point where the weightbearing line intersected the



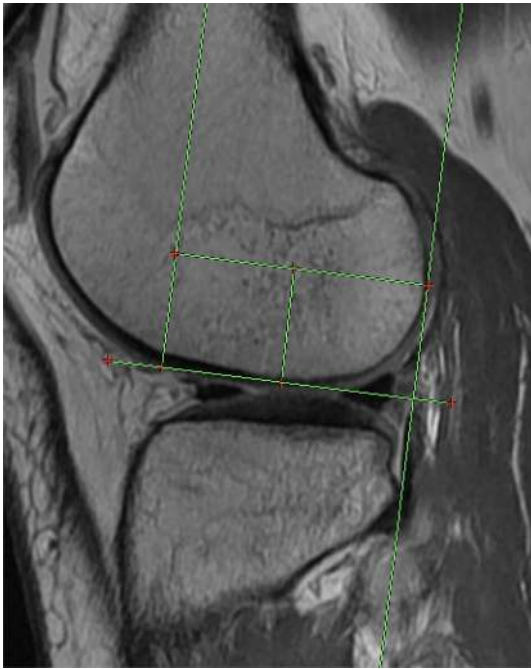
**Fig. 4** MRI sagittal slice at the medial-to-lateral midpoint of the lateral tibial plateau demonstrating the measurement of the lateral tibial plateau sagittal plane depth and the lateral tibial plateau articular surface sagittal plane depth. These lines were parallel with the articular surface depth measuring the anterior-to-posterior distance of the articular surface and the lateral tibial plateau depth measuring the anterior-to-posterior distance of the lateral tibial plateau at the level which it extends farthest posteriorly

tibial plateau was measured. This distance was then divided by the measured total lateral plateau width to provide the varus/valgus weightbearing axis for the knee (Fig. 6).

The MPTA was measured as the angle between the line along the surface of the tibial plateau and the mechanical axis of the tibia (Fig. 7). The mLDFA was measured as the angle between the line along the medial and lateral distal femoral articular surface and the mechanical axis of the femur (Fig. 7).

### Statistical analysis

Values for MRI and radiographic measurements were compared between case and control groups using paired *t* tests. Clinical characteristics, such as the presence of posterior cruciate ligament (PCL), medial collateral ligament, lateral (fibular) collateral ligament and posterolateral corner injuries or medial meniscal tears, mechanism of injury (contact vs. noncontact) were assessed using Chi-square testing and BMI was compared between groups using paired *t* tests. All statistical analyses were performed using IBM SPSS Statistical Suite, version 26, and the alpha level was set for statistical significance at 0.05. Due to multiple statistical testing for both paired *t* testing and Chi-square testing, Bonferroni correction was performed with the significance corrected

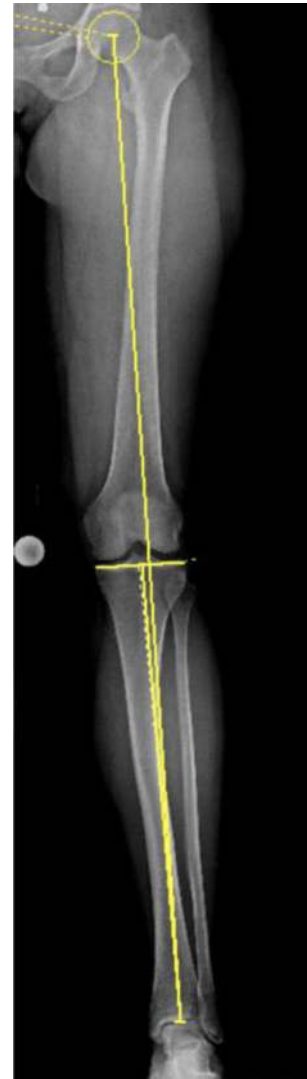

**Fig. 5** MRI sagittal slice at the medial-to-lateral midpoint of the lateral femoral condyle demonstrating the measurement of the lateral femoral condylar height and depth. The femoral longitudinal axis line was established on the midsagittal MRI slice and copied to this MRI slice. A line parallel to this was drawn tangential to the posterior-most aspect of the lateral femoral condyle. The distance between these two lines was considered the lateral femoral condylar sagittal depth. Two lines perpendicular to the femoral longitudinal axis were drawn, one tangential to the most distal aspect of the lateral femoral condyle, and one intersecting the most posterior point of the lateral femoral condyle. The distance between these two lines was considered as the lateral femoral condylar height

to 0.004 for *t* testing and 0.008 for Chi-square testing. An a priori power analysis was performed utilizing effect size identified in a prior study for differences in lateral posterior tibial slope in patients with and without ACL tears with alpha set at 0.05 and beta set at 0.80 [5]. This power analysis suggested 56 patients per group would be required to identify a statistically significant difference between groups.

## Results

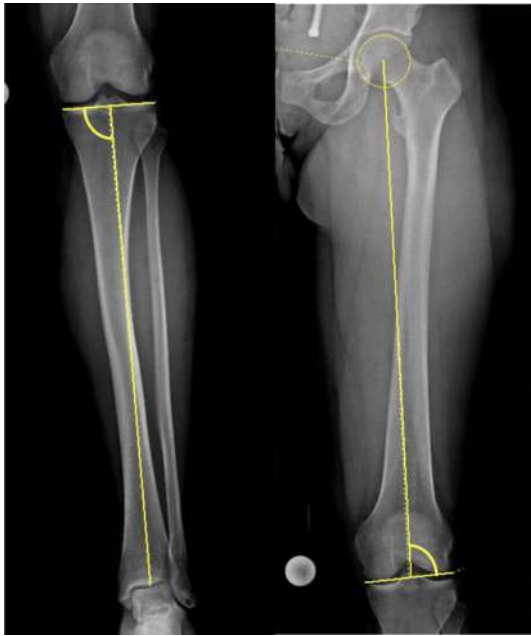
During the study time period, there were 851 patients identified with primary ACL tears. Of this population, 103 patients (12.1%) sustained LMPRTs in the setting of a primary ACL tear; these patients were matched according to age and gender with 103 patients with a primary ACL tear, but no LMPRT taken from the same primary ACL tear cohort. The mean age of the LMPRT group was 36.1 years compared with 36.1 years in the control group (SD: 14.6, n.s.). There was no difference in BMI between groups (24.5 vs. 24.6, SD:



**Fig. 6** Standing hip-to-ankle long alignment AP radiograph with mechanical weightbearing line drawn from the centre of the femoral head to the centre of the tibial plafond. The varus/valgus weightbearing axis was calculated as the distance from the medial side of the tibial plateau to the place where this line intersected the tibial plateau divided by the total width of the tibial plateau

3.4, n.s.). There was no difference in the incidence of contact vs. non-contact mechanism between the groups with a 21.4% incidence of contact mechanism in the LMPRT group compared with 19.4% in controls (n.s.). There was no difference in the number of acute (surgery within 6 weeks of injury) versus chronic injuries between groups with acute injuries in 71.8% of LMPRT patients compared with 76.7% in the control group (n.s.).

MRI and radiographic measurements for the LMPRT and control groups are reported in Table 1. Patients in the LMPRT group demonstrated a significantly steeper mean lateral PTS (9.1° vs. 7.0°,  $p=0.001$ ) and medial PTS (7.0° vs. 6.0°,  $p=0.03$ ), and a significantly greater



**Fig. 7** Standing hip-to-ankle long alignment AP radiographs demonstrating the measurement of MPTA (left) and mLDFA (right). The medial component of the angle between the tibial plateau and the mechanical axis of the tibia was measured as the MPTA. The lateral component of the angle between the line along distal medial and lateral femoral condyles and the mechanical femoral axis was measured as the mLDFA

lateral-to-medial slope asymmetry ( $2.0^\circ$  vs.  $1.0^\circ$ ,  $p=0.001$ ) as well. With Bonferonni correction, lateral PTS and slope asymmetry remained significantly different between groups, while medial PTS failed to meet statistical significance with correction. There was no difference in the LFC depth, height

or index between groups. There was also no difference in weightbearing mechanical axis ( $44.6\%$  vs.  $45.9\%$ , n.s.) or either MPTA ( $87.0^\circ$  vs.  $86.8^\circ$ , n.s.) or mLDFA ( $87.0^\circ$  vs.  $87.0^\circ$ , n.s.).

Associations between the presence of LMPRTs and various ligament and meniscal injuries are shown in Table 2. There was a significantly increased incidence of medial meniscus ramp lesions in patients in the LMPRT group ( $34.0\%$  vs.  $15.5\%$ , odds ratio: 2.8,  $p=0.002$ ). This remained statistically significant after Bonferonni correction. There was no increased incidence of collateral ligament, PCL, or posterolateral corner injuries with increased incidence in the LMPRT group relative to the control group (n.s.), and there was no increased incidence of medial meniscus or medial meniscus root tear (n.s.).

## Discussion

The most important finding of this study was that in the setting of a primary ACL tear, patients with a LMPRT had a significantly higher lateral PTS and increased lateral-to-medial PTS asymmetry compared with those without LMPRTs. There was also a significantly increased incidence of concurrent medial meniscus ramp lesion in the LMPRT group compared with the control group. In contrast to previous studies, no difference in knee alignment was found when assessing medial proximal tibial angle, mechanical lateral distal femoral angle, or weightbearing axis between groups [6, 21]. This study provides clinical utility in helping providers to have a higher degree of suspicion for LMPRTs in patients with steeper PTS or the presence of medial

**Table 1** MRI and radiographic measurements for patients with LMPRT in the setting of primary ACL tear compared to control patients without LMPRT in the setting of primary ACL tear

	LMPRT	Control	SD	<i>p</i> value
Lateral PTS ( $^\circ$ )	9.1	7.0	3.5   3.3	<b>0.001</b>
Medial PTS ( $^\circ$ )	7.0	6.0	3.0   3.0	0.03
PTS asymmetry ( $^\circ$ )	2.0	1.0	2.4   1.9	<b>0.001</b>
LFC depth (mm)	41.6	42.1	3.4   3.3	n.s.
LFC height (mm)	19.9	20.1	2.4   2.2	n.s.
LFC index (height/depth)	0.48	0.48	0.05   0.05	n.s.
LTP depth (mm)	45.2	45.6	4.2   4.8	n.s.
LTP articular depth (mm)	31.7	31.7	3.3   4.2	n.s.
LTP subluxation (mm)	5.4	4.7	4.1   3.5	n.s.
Weightbearing axis (% from medial)	44.6	45.9	11.8   12.1	n.s.
MPTA ( $^\circ$ )	87.0	86.8	1.5   1.8	n.s.
mLDFA ( $^\circ$ )	87.0	87.0	1.7   1.7	n.s.

Bolded values indicate statistical significance after Bonferonni correction

SD standard deviation, LMPRT lateral meniscus posterior root tear, PTS posterior tibial slope, LFC lateral femoral condyle, LTP lateral tibial plateau, MPTA medial proximal tibial angle, mLDFA mechanical lateral distal femoral angle

**Table 2** Chi-square associations between LMPRT and control groups with various ligament and meniscal injuries

	MCL tear		PCL tear		FCL tear		PLC tear		Medial meniscus tear		Medial meniscus ramp lesion	
	Incidence	p value	Incidence	p value	Incidence	p value	Incidence	p value	Incidence	p value	Incidence	p value
LMPRT	23/103 (22.3%)	n.s.	10/103 (9.7%)	n.s.	30/103 (29.1%)	n.s.	4/103 (3.9%)	n.s.	56/103 (54.4%)	n.s.	35/103 (34.0%)	<b>0.002</b>
Control	18/103 (17.5%)		7/103 (6.8%)		35/103 (34.0%)		3/103 (2.9%)		48/103 (46.6%)		16/103 (15.5%)	

Bolded values indicate statistical significance after Bonferroni correction

LMPRT lateral meniscus posterior root tear, MCL medial collateral ligament, PCL posterior cruciate ligament, FCL fibular collateral ligament, PLC posterolateral corner injury

meniscus ramp lesions. This is important since LMPRTs cannot always be clearly identified on pre-operative MRI images.

In the current study, there was a 34% incidence of concurrent medial meniscal ramp lesions in patients with LMPRTs compared with a 15.5% incidence of ramp lesions in case-matched controls. This should not be surprising since a recent study by Kim et al. has demonstrated increased posterior tibial slope as a risk factor for medial meniscal ramp lesions [13]. Previous biomechanical studies have demonstrated that the posterior horn of the medial meniscus and the lateral meniscus posterior root are important restraints to anterior tibial translation and knee internal rotation, respectively [4, 8, 20]. Clinically, Mouton et al. reported increased dynamic rotational laxity, as expressed by grade III pivot shift testing, in patients with combined ACL and medial ramp tears compared to patients with isolated ACL tears [19]. Similarly, Sonnery-Cottet et al. reported that 55% of patients in their study with combined ACL and ramp tears had > 6 mm of anterior knee laxity on physical exam [24]. Thus, a combined injury pattern involving a medial ramp lesion and lateral meniscus posterior root tear may help explain the disproportionately increased knee instability observed in some ACL-deficient patients. Particularly in the setting of a grade III pivot shift on pre-operative examination, clinicians ought to suspect a potential combined medial meniscal ramp lesion with the presence of a LMPRT in patients undergoing ACL reconstruction.

The findings of the present study do agree with those presented by Kolbe et al., who also demonstrated increased lateral PTS and lateral-to-medial PTS asymmetry as radiographic risk factors for LMPRT. The average value of lateral PTS in their study was  $8.0^\circ \pm 3.2^\circ$  compared with  $9.1^\circ \pm 3.5^\circ$  in our study, with a similar measurement methodology on MRI [14]. Kolbe et al. did show greater lateral-to-medial PTS asymmetry in LMPRTs than was shown in this study, and this is likely due to the fact that they did not observe a significant difference in medial PTS between patients with and without LMPRTs, whereas we also demonstrated an elevated medial PTS of  $7.0^\circ$  compared with  $6.0^\circ$  in controls [14]. The values measured for both medial and lateral PTS in our study are similar to those in other prior studies using MRIs for measurement of slope in patients with ACL tears, such as Hashemi et al. who reported a lateral PTS of  $7.2^\circ$  and medial PTS of  $6.0^\circ$  in males and  $8.4^\circ$  and  $6.9^\circ$  in females [11]. Okoroha et al. used a different methodology, measuring tibial slope by radiograph only, and they reported a tibial slope of  $12.6^\circ \pm 1.5$  in patients with LMPRT, which was higher than patients without LMPRT [21].

The present study found no differences in radiographic parameters used to assess coronal plane knee alignment. This contrasts the findings of Okohora et al. who demonstrated increased tibia vara in patients with LMPRT.

The present study did have a tenfold higher number of patients, which provides higher statistical power with less susceptibility to outliers. Valgus injury mechanisms have previously been reported to be associated with LMPRTs [15], and the authors theorize that valgus alignment would predispose patients to LMPRT rather than varus; however, the findings of the present study showed no association with either varus or valgus alignment. This study also did not find either an increased BMI or an increased incidence of a contact mechanism to be present in the LMPRT group, both of which had been reported as significant associations in prior studies [6, 21].

This study does have some limitations. By virtue of matching by both age and sex, the authors are unable to comment on whether there may be differences in the incidence of LMPRTs based on either age or gender. This was a limitation that the authors were willing to accept because the primary goal was to assess for differences in radiographic parameters between patients with and without LMPRT and it was desired to control for other factors which could potentially confound the analysis. Another limitation includes the use of knee MRIs to measure PTS because the MRI images do not include full-length images of the tibia which can limit the measurement of the tibial shaft axis. However, a measurement technique was utilized that has been used in other studies and has been validated to be reliable [4, 10–12]. Given the previously demonstrated reliability of measurement techniques used, a single observer was utilized. In addition, both 1.5 T and 3.0 T MRI images were analysed in this study, however, the heterogeneity of MRI imaging used increases the generalizability of this study.

## Conclusion

LMPRTs in the setting of primary ACL injuries were associated with significantly increased lateral PTS, and increased asymmetry between lateral and medial PTSs. In addition, clinicians should be aware of the increased incidence of concurrent medial meniscal ramp lesions in patients with LMPRTs. Knowledge of these associations should help guide clinical decision-making and counselling of patients in the setting of ACL tears with concomitant LMPRTs.

**Funding** Approved by Vail Health Hospital Institutional Review Board: Protocol #2019-11.

## Compliance with ethical standards

**Conflict of interest** The authors declare that they have no conflict of interest.

**Ethical approval** Ethical approval was obtained from the Institutional Review Board (IRB) from Vail Health Hospital.

## References

- Asai K, Nakase J, Oshima T, Shimozaki K, Toyooka K, Tsuchiya H (2020) Lateral meniscus posterior root tear in anterior cruciate ligament injury can be detected using MRI-specific signs in combination but not individually. *Knee Surg Sports Traumatol Arthrosc* 28:3094–3100
- Brody JM, Lin HM, Hulstyn MJ, Tung GA (2006) Lateral meniscus root tear and meniscus extrusion with anterior cruciate ligament tear. *Radiology* 239:805–810
- De Smet AA, Blankenbaker DG, Kijowski R, Graf BK, Shinki K (2009) MR diagnosis of posterior root tears of the lateral meniscus using arthroscopy as the reference standard. *AJR Am J Roentgenol* 192:480–486
- DePhillipo NN, Moatshe G, Chahla J, Aman ZS, Storaci HW, Morris ER et al (2019) Quantitative and qualitative assessment of the posterior medial meniscus anatomy: defining meniscal ramp lesions. *Am J Sports Med* 47:372–378
- DePhillipo NN, Zeigler CG, Dekker TJ, Grantham WJ, Aman ZS, Kennedy MI et al (2019) Lateral posterior tibial slope in male and female athletes sustaining contact versus noncontact anterior cruciate ligament tears: a prospective study. *Am J Sports Med* 47:1825–1830
- Feucht MJ, Bigdon S, Mehl J, Bode G, Muller-Lantzsch C, Sudkamp NP et al (2015) Risk factors for posterior lateral meniscus root tears in anterior cruciate ligament injuries. *Knee Surg Sports Traumatol Arthrosc* 23:140–145
- Forkel P, Herbort M, Sprenger F, Metzclaff S, Raschke M, Petersen W (2014) The biomechanical effect of a lateral meniscus posterior root tear with and without damage to the menisocofemoral ligament: efficacy of different repair techniques. *Arthroscopy* 30:833–840
- Frank JM, Moatshe G, Brady AW, Dornan GJ, Coggins A, Muckenhirn KJ et al (2017) Lateral meniscus posterior root and menisocofemoral ligaments as stabilizing structures in the ACL-deficient knee: a biomechanical study. *Orthop J Sports Med* 5:2325967117695756
- Geeslin AG, Civitarese D, Turnbull TL, Dornan GJ, Fuso FA, LaPrade RF (2016) Influence of lateral meniscal posterior root avulsions and the menisocofemoral ligaments on tibiofemoral contact mechanics. *Knee Surg Sports Traumatol Arthrosc* 24:1469–1477
- Grassi A, Macchiarola L, Urrizola Barrientos F, Zicaro JP, Costa Paz M, Adravanti P et al (2019) Steep posterior tibial slope, anterior tibial subluxation, deep posterior lateral femoral condyle, and meniscal deficiency are common findings in multiple anterior cruciate ligament failures: an MRI case-control study. *Am J Sports Med* 47:285–295
- Hashemi J, Chandrashekar N, Mansouri H, Gill B, Slauterbeck JR, Schutt RC Jr et al (2010) Shallow medial tibial plateau and steep medial and lateral tibial slopes: new risk factors for anterior cruciate ligament injuries. *Am J Sports Med* 38:54–62
- Hudek R, Schmutz S, Regenfelder F, Fuchs B, Koch PP (2009) Novel measurement technique of the tibial slope on conventional MRI. *Clin Orthop Relat Res* 467:2066–2072
- Kim SH, Seo HJ, Seo DW, Kim KI, Lee SH (2020) Analysis of risk factors for ramp lesions associated with anterior cruciate ligament injury. *Am J Sports Med* 48:1673–1681
- Kolbe R, Schmidt-Hebbel A, Forkel P, Pogorzelski J, Imhoff AB, Feucht MJ (2019) Steep lateral tibial slope and lateral-to-medial



- slope asymmetry are risk factors for concomitant posterolateral meniscus root tears in anterior cruciate ligament injuries. *Knee Surg Sports Traumatol Arthrosc* 27:2585–2591
15. Kosy JD, Matteliano L, Rastogi A, Pearce D, Whelan DB (2018) Meniscal root tears occur frequently in multi-ligament knee injury and can be predicted by associated MRI injury patterns. *Knee Surg Sports Traumatol Arthrosc* 26:3731–3737
  16. LaPrade CM, Jansson KS, Dornan G, Smith SD, Wijdicks CA, LaPrade RF (2014) Altered tibiofemoral contact mechanics due to lateral meniscus posterior horn root avulsions and radial tears can be restored with in situ pull-out suture repairs. *J Bone Jt Surg Am* 96:471–479
  17. LaPrade RF, Ho CP, James E, Crespo B, LaPrade CM, Matheny LM (2015) Diagnostic accuracy of 3.0 T magnetic resonance imaging for the detection of meniscus posterior root pathology. *Knee Surg Sports Traumatol Arthrosc* 23:152–157
  18. Matheny LM, Ockuly AC, Steadman JR, LaPrade RF (2015) Posterior meniscus root tears: associated pathologies to assist as diagnostic tools. *Knee Surg Sports Traumatol Arthrosc* 23:3127–3131
  19. Mouton C, Magosch A, Pape D, Hoffmann A, Nuhrenborger C, Seil R (2019) Ramp lesions of the medial meniscus are associated with a higher grade of dynamic rotatory laxity in ACL-injured patients in comparison to patients with an isolated injury. *Knee Surg Sports Traumatol Arthrosc*. <https://doi.org/10.1007/s00167-019-05579-z>
  20. Musahl V, Citak M, O’Loughlin PF, Choi D, Bedi A, Pearle AD (2010) The effect of medial versus lateral meniscectomy on the stability of the anterior cruciate ligament-deficient knee. *Am J Sports Med* 38:1591–1597
  21. Okoroha KR, Patel RB, Kadri O, Jildeh TR, Krause A, Gullede C et al (2019) Abnormal tibial alignment is a risk factor for lateral meniscus posterior root tears in patients with anterior cruciate ligament ruptures. *Knee Surg Sports Traumatol Arthrosc* 27:590–595
  22. Praz C, Vieira TD, Saithna A, Rosentiel N, Kandhari V, Nogueira H et al (2019) Risk factors for lateral meniscus posterior root tears in the anterior cruciate ligament-injured knee: an epidemiological analysis of 3956 patients from the SANTI study group. *Am J Sports Med* 47:598–605
  23. Shelbourne KD, Roberson TA, Gray T (2011) Long-term evaluation of posterior lateral meniscus root tears left in situ at the time of anterior cruciate ligament reconstruction. *Am J Sports Med* 39:1439–1443
  24. Sonnery-Cottet B, Praz C, Rosenstiel N, Blakeney WG, Ouanekar H, Kandhari V et al (2018) Epidemiological evaluation of meniscal ramp lesions in 3214 anterior cruciate ligament-injured knees from the SANTI study group database: a risk factor analysis and study of secondary meniscectomy rates following 769 ramp repairs. *Am J Sports Med* 46:3189–3197

**Publisher’s Note** Springer Nature remains neutral with regard to jurisdictional claims in published maps and institutional affiliations.