

Technique for Treatment of Subchondral Compression Fracture of the Lateral Femoral Condyle Associated With ACL Tear



Konrad Malinowski, M.D., Ph.D., Marcin Mostowy, Adrian Góralczyk, M.D., Robert F. LaPrade, M.D., Ph.D., and Krzysztof Hermanowicz, M.D., Ph.D.

Abstract: Excessive knee pivoting that causes a complete anterior cruciate ligament (ACL) tear may result in a subchondral compression fracture on the lateral femoral condyle after impacting the lateral tibial condyle. Because this mechanism is similar to the humeral head that has an impact on the glenoid during an anterior shoulder dislocation, such an osteochondral fracture can be considered equivalent to a “Hill-Sachs lesion of the knee.” Restoring the native anatomy of the lateral femoral condyle articular surface is crucial, because its depression alters knee biomechanics, leading to bony knee instability, potentially greatly elevating the risk of ACL reconstruction failure and meniscal tears. In addition, bony knee instability increases the forces acting on the cartilage, which may impair one’s quality of life and lead to the development of osteoarthritis. The fact that many patients with complete ACL tears are relatively young emphasizes the key role of osteoarthritis prevention. The aim of this report is to present a minimally invasive procedure to treat the “Hill-Sachs–like” knee lesion, a tricky enemy of knee stability.

Introduction

During complete anterior cruciate ligament (ACL) tears in pivoting mechanisms, the area of the lateral femoral condyle (LFC) localized just above the anterior third of the lateral meniscus (LM) impacts the posterior border of the lateral tibial plateau (LTP),

which may result in a subchondral compression fracture.¹ It has been proved that compression of the posterior border of the LTP can lead to bony knee instability, similarly to a Bankart lesion in the glenohumeral joint.² Just as in the glenohumeral joint, a “knee Bankart lesion” can be associated with a “knee Hill-Sachs lesion.” There are many reports of LFC posttraumatic bone bruises and impaction fractures arising similar to the humeral head bruises in Hill-Sachs lesion after humeral head impacting glenoid during anterior shoulder dislocation.³ A prevalence of such “Hill-Sachs–like” lesions of the LFC was reported to be as high as 83% in patients with complete ACL tears.³ While bone bruises may be considered “subchondral contusions” with no articular surface alterations, subchondral compression fractures result in articular surface depression.⁴ Either way, it is important to distinguish subchondral fractures characterized by intact, depressed cartilage from intraarticular fractures with disrupted cartilage.⁴ While some studies analyzed stress fractures emerging from repetitive bone-on-bone impactions,⁵⁻⁷ there is a paucity of literature concerning posttraumatic subchondral compression condylar fractures. The only one found was a case series of subchondral compression fractures of the weightbearing part of the medial femoral condyle (MFC) and no cases of LFC “Hill-Sachs–like lesions.”⁸

From the Artromedical Orthopaedic Clinic, Belchatow, Poland (K.M.); Orthopedic and Trauma Department, Veteran’s Memorial Teaching Hospital in Lodz, Medical University of Lodz, Lodz, Poland (M.M.); ORTIM Orthopaedic Clinic, Bialystok, Poland (A.G., K.H.); and Twin Cities Orthopedics, Edina, Minnesota, USA (R.F.L.).

Conflict of interests: K. Malinowski reports he is a Zimmer Biomet consultant and is on the PTArthro Board, he reports no conflict of interests for this video and manuscript; R.F. LaPrade reports no conflict of interests for this video and manuscript; he reports that that he is a consultant and receives royalties from Arthrex, Ossur and Smith and Nephew; and is on the Editorial Boards of AJSM, JEO and KSSTA; Other authors have no conflict of interest. Full ICMJE author disclosure forms are available for this article online, as [supplementary material](#).

Received December 21, 2019; accepted February 16, 2020.

Address correspondence to Konrad Malinowski, M.D., Ph.D., Artromedical Orthopaedic Clinic, Chrobrego 24, 97-400 Belchatow, Poland. E-mail: malwin8@wp.pl

© 2020 by the Arthroscopy Association of North America. Published by Elsevier. This is an open access article under the CC BY-NC-ND license (<http://creativecommons.org/licenses/by-nc-nd/4.0/>).

2212-6287/191567

<https://doi.org/10.1016/j.eats.2020.02.016>

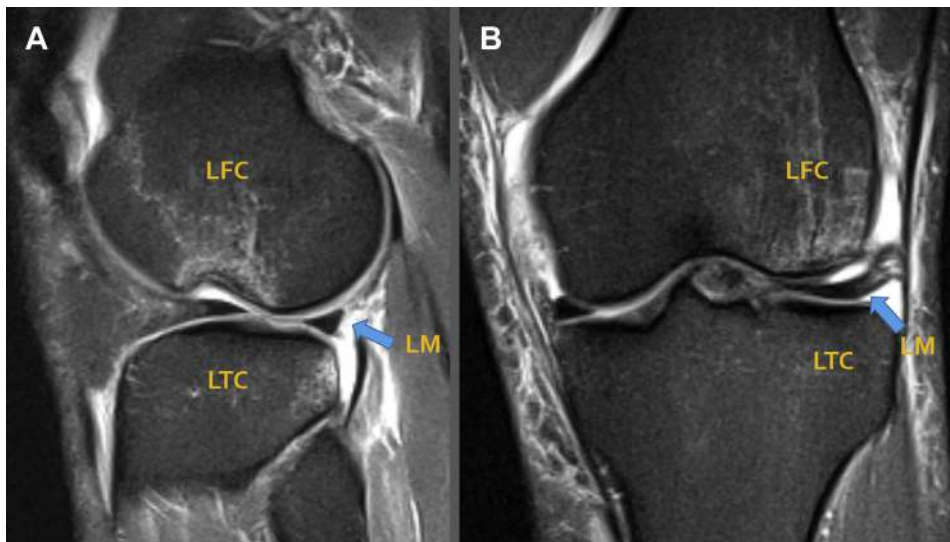


Fig 1. MRI scans of the left knee with “Hill-Sachs-like lesion” before surgery: (A) Sagittal view. Fracture and bone marrow oedema can be seen on lateral femoral condyle (LFC). (B) Coronal view. LFC fracture and bone marrow oedema can be seen as well. Lateral Meniscus (LM) is elevated without contact with LFC nor Lateral Tibial Condyle (LTC). Such lesion leads to bony knee instability, causing the risk of ACL reconstruction failure and meniscal tears to increase. What is more, the articulation area is reduced and lateral meniscus load distribution function is decreased, which alters knee biomechanics and increases the risk of osteoarthritis (OA).

As mentioned, a “knee Hill-Sachs lesion” may lead to bony instability, especially if it engages with an impaction fracture of the posterior border of the LTP. Beside impairing functionality and inducing pain, the risk of ACL reconstruction failure and meniscal tears increases dramatically if such instability is not addressed.^{2,5-8} In addition, the articulation area is reduced and lateral meniscus load distribution function is decreased, which alters knee biomechanics and increases the risk of osteoarthritis (OA).⁹ A minimally invasive operative technique is described to avoid these potentially disastrous consequences of the “knee Hill-Sachs lesion” and is reported here.

Diagnosis

The “knee Hill-Sachs lesions,” which are osteochondral compression fractures of the LFC, can be seen on magnetic resonance images in the sagittal and coronal views (Fig. 1, Video 1) and confirmed during the arthroscopic knee examination (Fig. 2, Video 1). On the sagittal view, a discontinuation of the convex LFC contour can be seen.

Surgical Technique

Indications

The indication for the presented technique is a post-traumatic LFC osteochondral compression fracture with good condition of the overlying cartilage.

Contraindications

Contraindications for this technique include poor cartilage condition (greater than grade 2 according to the ICRS classification), displaced articular surface fractures, and spontaneous osteonecrosis of the knee.

Patient Positioning

The patient is positioned supine with a nonsterile thigh tourniquet used to diminish intraoperative bleeding. The leg is placed in the leg holder and prepared and draped in a standard sterile manner.

Arthroscopic Part of the Procedure

The diagnostic arthroscopy is performed using standard anterolateral and anteromedial portals. Clinical

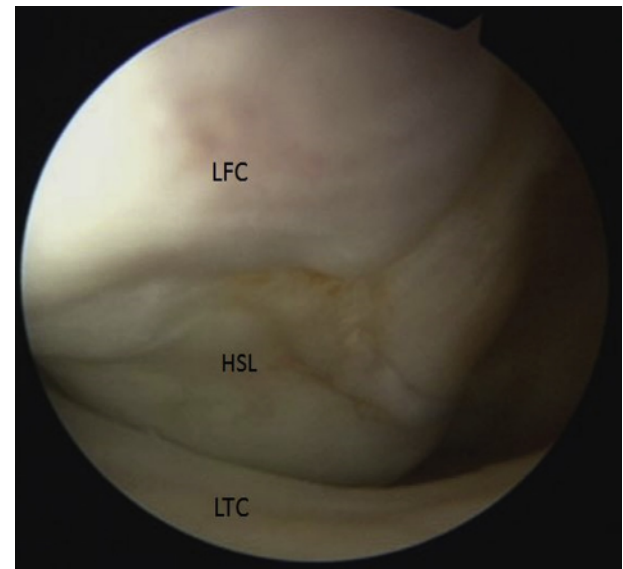


Fig 2. Arthroscopic view in the left knee through anterolateral portal. Lateral Femoral Condyle (LFC) osteochondral fracture (HSL, Hill-Sachs-like Lesion) can be seen in 30° of knee flexion. As the knee is being extended and in full extension, it can be seen that femoral and tibial surfaces do not articulate with each other. (LTC, Lateral Tibial Condyle.)

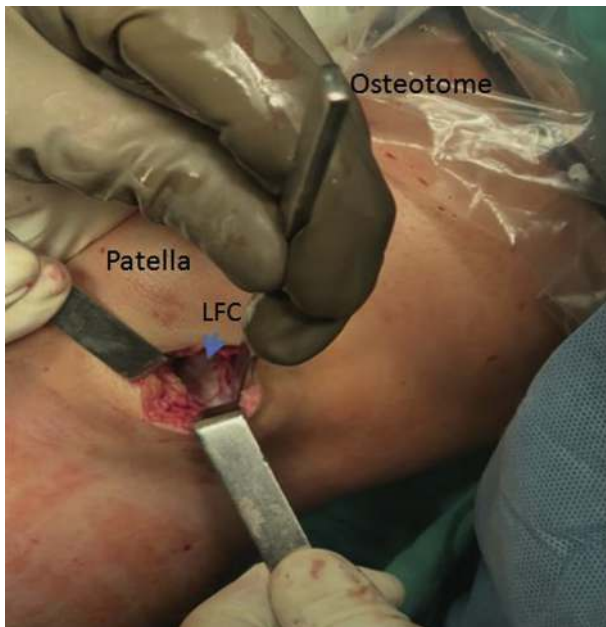


Fig 3. After arthroscopic confirmation of Lateral Femoral Condyle (LFC) osteochondral fracture (HSL, Hill-Sachs-like Lesion) the anterolateral portal is enlarged to 2-3 cm. Soft tissues are retracted to visualize LFC and an osteotome is used to separate the cartilage along with subchondral bone layer, about 1,5 mm thick.

and radiological findings are confirmed arthroscopically. The ACL reconstruction is performed, along with adjunct arthroscopic procedures, if necessary.

Minimally Invasive Treatment of a “Knee Hill-Sachs Lesion”

The anterolateral arthroscopic portal is enlarged to 2 to 3 cm, according to the size of the lesion. The knee is then extended to the angle, allowing for direct fracture visualization. An 8-mm osteotome (Arestomed, Opole, Poland) is used to separate the cartilage along with subchondral bone layer, about 1.5 mm thick (Fig. 3, Video 1). Then, an elevator (Aesculap Chifa, Warsaw, Poland) is introduced under the partially separated osteochondral flap and gently impacted with a hammer to reduce the separation. In order to protect the cartilage, a surgeon puts a finger on the articular surface above the fracture and then uses the elevator to further mobilize the osteochondral flap (Fig. 4, Video 1). It is important to use an elevator gently, while performing rotatory maneuvers to diminish the risk of cartilage injury. The separated osteochondral flap should be mobile. In the next step, a 2-cm syringe with an obliquely cut apex is used to introduce cancellous bone allograft under the created flap. The bone graft has to be crushed to pulp before introducing it through the syringe. The blunt site of a drill (Zimmer-Biomet 9-mm low profile femoral drill)

is used to push the bone graft pulp from the syringe under the flap and then packed in the defect tightly, first by impaction with the drill and then with the elevator (Fig. 5, Video 1). As more graft is packed under the flap, elevation of the LFC articular surface can be observed. The goal is to restore the joint surface anatomy as it was before the traumatic lesion. The surgeon should control the amount of elevation with one's fingers. Care should be taken to avoid losing bone graft pieces outside of the desired filling space. The next step is to grab lateral recess periosteum with tweezers and mobilize it with an elevator. Then, the mobilized periosteum is sutured to the osteochondral flap margin using a bioabsorbable suture (Vicryl 2-0). Two or three sutures are placed, closing the LFC surface defect (Fig. 6, Video 1). The superficial layers are closed in a standard manner.

Rehabilitation

Passive knee range of motion to 0°-90° is safe and starts at the first postoperative day. Walking on crutches with no weightbearing is recommended for 6 weeks. In the first 6 weeks, quadriceps strengthening exercises, co-contraction exercises, and patella and scars intensive mobilization are performed as well as stationary bike under physiotherapist supervision.

After 6 weeks, a gradual weightbearing is allowed with shoe insoles that force the hindfoot to supine position and 4- to 6-mm elevation of medial foot edge to

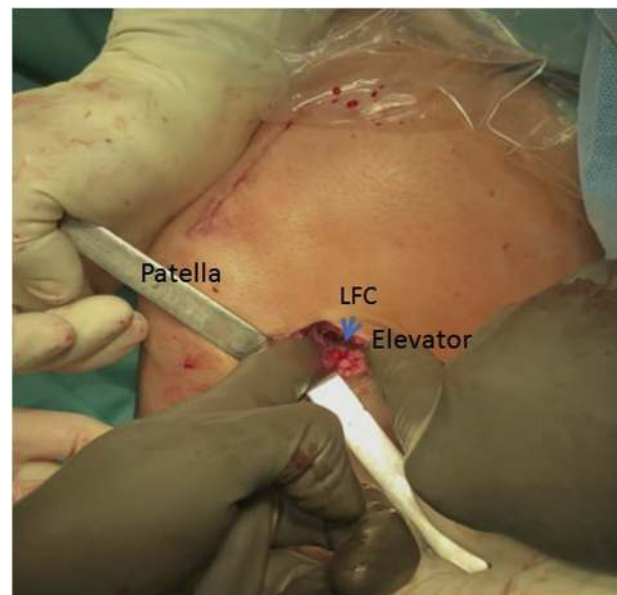


Fig 4. After arthroscopic confirmation of Lateral Femoral Condyle (LFC) osteochondral fracture (HSL, Hill-Sachs-like Lesion), anterolateral portal enlargement and separating the osteochondral flap from LFC, it has to be mobilized. Surgeon uses finger to protect the cartilage during osteochondral flap mobilization with an elevator.

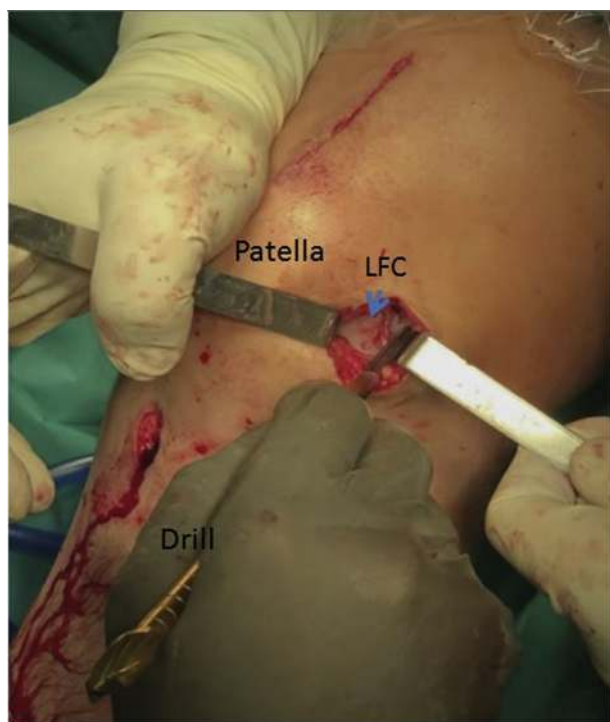


Fig 5. After arthroscopic confirmation of Lateral Femoral Condyle (LFC) osteochondral fracture (HSL, Hill-Sachs-like Lesion), anterolateral portal enlargement, separation and mobilization of LFC osteochondral flap, the next step is to pack the bone pulp under the created flap. Surgeon uses the blunt site of the drill to pack the bone pulp tightly.

decrease the load on the lateral compartment of the knee.

Discussion

This minimally invasive technique of an LFC “Hill Sachs-like” osteochondral fracture treatment is efficient in restoring the native articular surface anatomy, physiologic cartilage–meniscus–cartilage contact, and bony knee stability–joint congruence. This is the main benefit of the technique, because without such restoration knee subluxations could occur, especially if a “knee Hill-Sachs lesion” engaged with a “knee Bankart lesion.”¹⁰ It would greatly elevate the risk of ACL reconstruction failure, meniscal tears, and OA development and impair the patient’s quality of life.² The next benefit of the presented technique is its minimal invasiveness, allowing for a faster recovery. Furthermore, it is not very technically demanding, presumably shortening the learning curve. Another advantage is that no chondral or osteochondral grafts are needed, because in this described lesion, the cartilage is not damaged and is just depressed. A cancellous bone allograft is used and therefore no harvesting site morbidity is observed. The osteoconductive properties of the cancellous bone allograft

allow for full weightbearing after 6 weeks of rehabilitation. A further benefit of the presented technique is retaining the native hyaline cartilage, whose properties are far superior to fibrohyaline connective tissue emerging after microfractures or microabrasion.¹¹ It is especially important due to the fact that many patients are active young people who sustain a “Hill-Sachs-like” osteochondral injury during sports-related “pivot shift” ACL tear. Furthermore, there is no hardware introduced during the surgery, so there is minimal risk of its loosening or soft tissue irritation. The periosteum is threaded with bioabsorbable sutures, leaving no foreign body within the knee joint after the absorption.

However, this technique is only applicable with good cartilage condition and the risk of intraoperative damage of cartilage does exist. The postoperative scar is slightly longer than after standard arthroscopy, yet much shorter than after non–minimally invasive medial knee classic surgeries. The next disadvantage is a longer time of surgery. Furthermore, the risk of arthrofibrosis is theoretically elevated due to greater tissue traumatization. It is therefore important to initiate knee motion as early as possible and to perform intensive patellofemoral joint and scar mobilization. Another disadvantage of the technique is greater quadriceps muscle mass loss due to no weightbearing in first 6 weeks postoperatively. Quadriceps strengthening exercises, co-contraction exercises, and the use of a stationary bike should be initiated right after surgery to stimulate quadriceps muscle as much mass as possible.

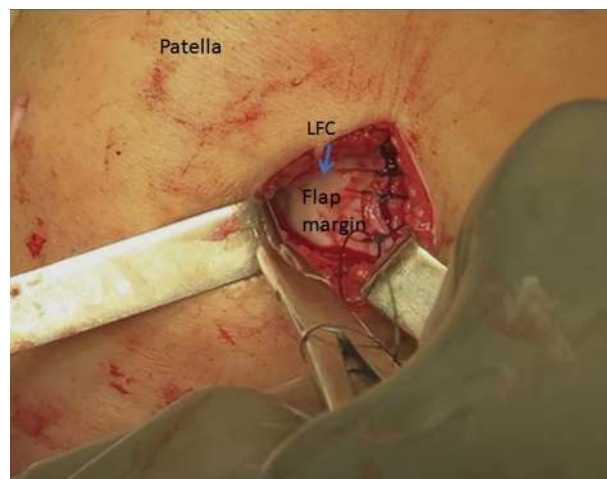


Fig 6. After arthroscopic confirmation of Lateral Femoral Condyle (LFC) osteochondral fracture (HSL, Hill-Sachs-like Lesion), anterolateral portal enlargement, separation and mobilization of LFC osteochondral flap and packing the bone pulp under the created flap, the next step is to close the LFC surface. To achieve this, bioabsorbable sutures are used to suture the lateral LFC recess periosteum with the osteochondral flap margin.

Table 1. Advantages and Disadvantages of Minimally Invasive Treatment of “Knee Hill-Sachs Lesions”

Advantages:	Disadvantages:
Bony stability is restored. Native hyaline cartilage is retained. Technique is minimally invasive, which allows for faster recovery. Technique is not very skill- demanding. No osteochondral grafts are needed. As cancellous allograft is used, no harvesting site morbidity occurs. No hardware is introduced, so there is no risk of its loosening or soft tissues irritation.	Possible only with good cartilage condition. A risk of cartilage damage exists. Postoperative scars are longer than after standard knee arthroscopy. Longer time of surgery and ischemia. The risk of arthrofibrosis is theoretically elevated due to bigger tissue traumatization. Greater quadriceps muscle mass loss due to no weight bearing in 6 postoperative weeks.

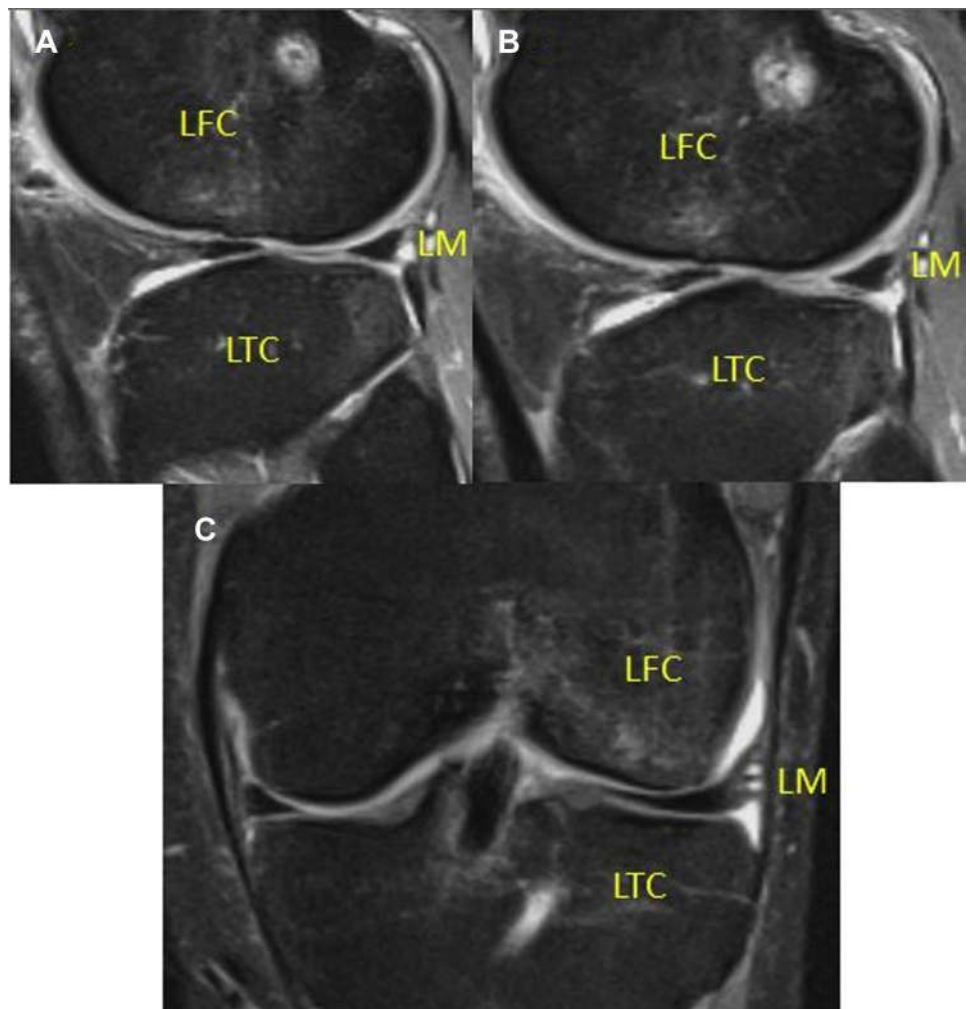
Advantages and disadvantages of the technique are summarized in the [Table 1](#).

[Fig. 7](#) and [Video 1](#) present the 6-month follow-up magnetic resonance imaging results. On the sagittal view articular surface can be seen to follow the convex contour of the LFC, with almost no sign of past subchondral compressive fracture. On the

coronal view, the LM can be seen to adhere to LFC and LTC.

To summarize, this is a safe, cost-effective technique to restore the articular LFC surface, improving functional and radiological outcomes. Bony knee stability is regained, lowering the risk of ACL reconstruction failure and lowering the risk of OA development.

Fig 7. MRI of the left knee at 6-months follow up: (A), (B): Sagittal views. Restored Lateral Femoral Condyle (LFC) convex contour and bone marrow oedema resolution can be seen. (C) Lengthened LFC and bone marrow oedema resolution can be seen. Lateral Meniscus (LM) is not elevated and remains in contact with LFC and Lateral Tibial Condyle (LTC). Bony knee stability is regained, lowering the risk of ACL reconstruction failure and lowering the risk of OA development.



References

1. Choi WR, Yang JH, Jeong SY, Lee JK. MRI comparison of injury mechanism and anatomical factors between sexes in noncontact anterior cruciate ligament injuries. *PLoS One* 2019;14:1-11.
2. Ciszowska-Lysoń B, Dominik B, Zdanowicz U, Śmigiełski R. Proposing an MRI-based classification system allowing proper assessment of the damage to the posterior edge of the tibia. Poster: European Congress of Radiology, February 28, 2018–March 4, 2018, Vien, Austria.
3. Patel S, Hageman J, Quatman C, Wordeman S, Hewett T. Prevalence and location of bone bruises associated with anterior cruciate ligament injury and implications for mechanism of injury: A systematic review. *Sport Med* 2014;44:281-293.
4. Bonadio MB, Ormond Filho AG, Helito CP, Stump XM, Demange MK. Bone marrow lesion: Image, clinical presentation, and treatment. *Magn Reson Insights* 10:1-6.
5. Depasquale R, Fotiadou A, Kumar DS, et al. Subchondral impaction fractures of the non-weight-bearing portion of the lateral femoral condyle. *Skeletal Radiol* 2013;42:177-185.
6. An VV, Broek M, van den, Oussedik S. Subchondral insufficiency fracture in the lateral compartment of the knee in a 64-year-old marathon runner. *Knee Surg Relat Res* 2017;29:325-328.
7. Grzelak P, Podgórski MT, Stefanczyk L, Krochmalski M, Domzalski M. Subchondral impaction fractures of the medial femoral condyle in weightlifters: A report of 5 cases. *Clin J Sport Med* 2016;26:e3-e5.
8. Yoo JH, Kim EH, Yim SJ, Lee BI. A case of compression fracture of medial tibial plateau and medial femoral condyle combined with posterior cruciate ligament and posterolateral corner injury. *Knee* 2009;16:83-86.
9. Verdonk R, Madry H, Shabshin N, et al. The role of meniscal tissue in joint protection in early osteoarthritis. *Knee Surg Sport Traumatol Arthrosc* 2016;24:1763-1774.
10. Hermanowicz K, Malinowski K, Góralczyk A, Guszczyn T, LaPrade RF, Sadlik B. All-arthroscopic treatment of schatzker type III lateral tibial plateau fracture without fluoroscopy. *Arthrosc Tech* 2019;8:e567-e574.
11. Link JM, Salinas EY, Hu JC, Athanasiou KA. The tribology of cartilage: Mechanisms, experimental techniques, and relevance to translational tissue engineering. *Clin Biomech* 2019;0-1. December 2018.