Qualitative and Quantitative Analyses of the Dynamic and Static Stabilizers of the Medial Elbow

An Anatomic Study

Salvatore J. Frangiamore,* MD, Gilbert Moatshe,*†‡ MD, Bradley M. Kruckeberg,§ BA, David M. Civitarese,§ BS, Kyle J. Muckenhirn,§ BA, Jorge Chahla,§ MD, PhD, Alex W. Brady,§ MSc, Mark E. Cinque,§ BS, Morten Lykke Oleson,‖ MD, Matthew T. Provencher,* MD, Thomas R. Hackett,* MD, and Robert F. LaPrade,*§¶ MD, PhD
Investigation performed at the Steadman Philippon Research Institute, Vail, Colorado, USA

Background: The anterior bundle of the medial ulnar collateral ligament (UCL) and the forearm flexors provide primary static and dynamic stability to valgus stress of the elbow in overhead-throwing athletes. Quantitative anatomic relationships between the dynamic and static stabilizers have not been described.

Purpose: To perform qualitative and quantitative anatomic evaluations of the medial elbow-UCL complex with specific attention to pertinent osseous and soft tissue landmarks.

Study Design: Descriptive laboratory study.

Methods: Ten nonpaired, fresh-frozen human cadaveric elbows (mean age, 54.1 years [range, 42-64 years]; all male) were utilized for this study. Quantitative analysis was performed with a 3-dimensional coordinate measuring device to quantify the location of pertinent bony landmarks and tendon and ligament footprints on the humerus, ulna, and radius.

Results: The anterior bundle of the UCL attached 8.5 mm (95% CI, 6.9-10.0) distal and 7.8 mm (95% CI, 6.6-9.1) lateral to the medial epicondyle, 1.5 mm (95% CI, 0.5-2.5) distal to the sublime tubercle, and 7.3 mm (95% CI, 6.1-8.5) distal to the joint line on the ulna along the ulnar ridge. The flexor digitorum superficialis (FDS) ulnar tendinous insertion was closely related and interposed within the anterior bundle of the UCL, overlapping with 45.6% (95% CI, 38.1-53.6) of the length of the anterior bundle of the UCL. The flexor carpi ulnaris (FCU) attached 1.9 mm (95% CI, 0.8-2.9) posterior and 1.3 mm (95% CI, 0.6-3.2) proximal to the sublime tubercle and overlapped with 20.9% (95% CI, 7.2-34.5) of the area of the distal footprint of the anterior bundle of the UCL.

Conclusion: The anterior bundle of the UCL had consistent attachment points relative to the medial epicondyle and sublime tubercle. The ulnar limb of the FDS and FCU tendons demonstrated consistent insertions onto the ulnar attachment of the anterior bundle of the UCL. These anatomic relationships are important to consider when evaluating distal UCL tears both operatively and nonoperatively. Excessive stripping of the sublime tubercle should be avoided during UCL reconstruction to prevent violation of these tendinous attachments.

Clinical Relevance: The findings of this study enhance the understanding of valgus restraint in throwing athletes and provide insight into the difference in nonoperative outcomes between proximal and distal tears of the UCL.

Keywords: elbow; ulnar collateral ligament; quantitative anatomy

The medial ulnar collateral ligament (UCL) is composed of 3 separate related structures—the anterior, posterior, and oblique bundles—and is the primary stabilizer to valgus stress in the elbow. The anterior bundle provides the majority of valgus restraint, while the entire UCL complex is essential for valgus stability in throwing athletes.[8,17,20,29] Specifically, the UCL provides critical valgus stability in athletes during the late cocking and early acceleration phases of throwing.[8] In addition, the UCL and medial joint capsule contribute to static stabilization of the elbow,[22] while the flexor pronator muscle mass has an important role in dynamic elbow valgus stability.[19,23,24,30]

Injuries to the distal insertion of the anterior bundle are associated with increased failure rates in professional pitchers compared with proximal bundle injuries when treated nonoperatively.[13,25] Numerous studies have reported concomitant

The American Journal of Sports Medicine
2018;46(3):687–694
DOI: 10.1177/0363546517743749

TABLE 1
Anatomic Points Measured on Quantitative Analysis[a]

Bony	Soft Tissue
Sublime tubercle	Pronator teres
Ulnar ridge	Common flexor (FCR, FCU, FDS)
Olecranon tip	Brachialis
Coronoid process	FCU
Medial humeral epicondyle	FDS
Lateral humeral epicondyle	Anterior bundle of UCL
Ulnohumeral joint line	Oblique bundle of UCL
	Posterior bundle of UCL

[a]FCR, flexor carpi radialis; FCU, flexor carpi ulnaris; FDS, flexor digitorum superficialis; UCL, ulnar collateral ligament.

flexor pronator mass injuries in patients with UCL tears.[3,4,8,10,21] Furthermore, early surgical techniques for UCL reconstruction involved disruption of the flexor pronator musculature and resulted in less than optimal outcomes[8] compared with modern surgical approaches, which have placed an increased emphasis on limiting dissection of the flexor pronator musculature during exposure.[1,28,31] Although biomechanical studies have evaluated the static and dynamic stabilizers in the elbow,[19,20,24,30] there is a paucity of literature describing the quantitative and clinically relevant anatomy between the UCL and related structures. This information is important in understanding the anatomic relationships between the static and dynamic valgus stabilizers of the elbow and for the surgical management of injuries related to these structures. Therefore, the purpose of this study was to perform qualitative and quantitative anatomic evaluations of the UCL attachment sites, with specific attention to their relationship with the dynamic stabilizers of the elbow and pertinent osseous and soft tissue landmarks. It was hypothesized that the UCL would have consistent parameters concerning its anatomic attachments and relationships to surgically relevant landmarks.

METHODS

Specimen Preparation

Ten nonpaired, fresh-frozen human cadaveric elbows (mean age, 54.1 years [range, 42-64 years]; all male) without prior surgery or evidence of previous injuries were utilized for this study. The cadaveric specimens were donated to a tissue bank for medical research and then purchased by our institution. All specimens were stored at –20°C and thawed at room temperature for 24 hours before preparation. Specimens were dissected to remove the skin and subcutaneous tissue, leaving the muscles and medial elbow structures intact. The forearm was fixed in extension and full supination using Steinmann pins across bony articulations and placed in a custom clamp for measurement consistency.

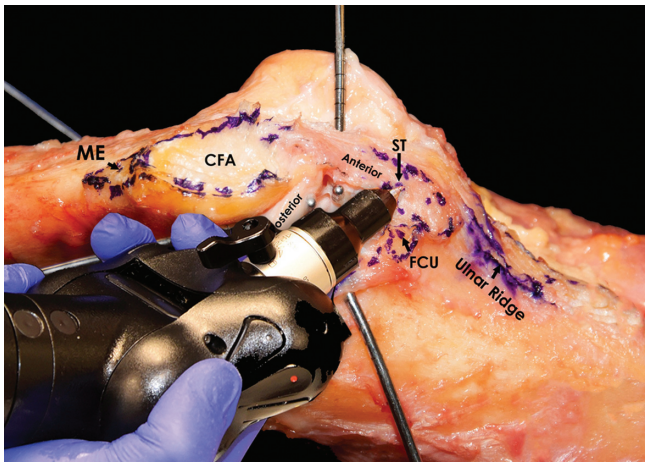

Figure 1. Data collection with the Romer device. The footprints were marked and data points collected on the perimeter and center. CFA, common flexor attachment; FCU, flexor carpi ulnaris; ME, medial epicondyle; ST, sublime tubercle.

Data Collection

Anatomic measurements were collected using a portable coordinate measuring device (7315 Romer Absolute Arm; Hexagon Metrology) and recorded as 3-dimensional (3D) point coordinates using Rhino 5 (McNeel North America) (Figure 1). Point data were transferred to Matlab (MathWorks), where they were analyzed using custom software. To ensure the consistency of point collection, both the specimen and 3D coordinate measuring device were rigidly fastened to the same table, and reference points on the humerus, ulna, and radius were measured before and after data collection to ensure that the specimen did not move during the dissection and measurement process. The list of measured structures is shown in Table 1.

¶Address correspondence to Robert F. LaPrade, MD, PhD, The Steadman Clinic, 181 West Meadow Drive, Suite 400, Vail, CO 81657, USA (email: drlaprade@sprivail.org).
*The Steadman Clinic, Vail, Colorado, USA.
†Oslo University Hospital, University of Oslo, Oslo, Norway.
‡Oslo Sports Trauma Research Center, Norwegian School of Sport Sciences, Oslo, Norway.
§Steadman Philippon Research Institute, Vail, Colorado, USA.
‖Århus University, Århus, Denmark.
One or more of the authors has declared the following potential conflict of interest or source of funding: R.F.L. receives royalties from Arthrex and Smith & Nephew; is a paid consultant for Arthrex, Ossur, and Smith & Nephew; and receives research support from Arthrex, Smith & Nephew, Ossur, and Linvatec. M.T.P. receives intellectual property royalties from Arthrex and is a paid consultant for Arthrex and the Joint Restoration Foundation. T.R.H. is a paid consultant and paid speaker for Arthrex and Sonoma Orthopedics, receives research support from Arthrex, and holds stock or stock options in Sonoma Orthopedics and NICE. G.M. receives research support from Arthrex and the South-Eastern Norway Regional Health Authority.

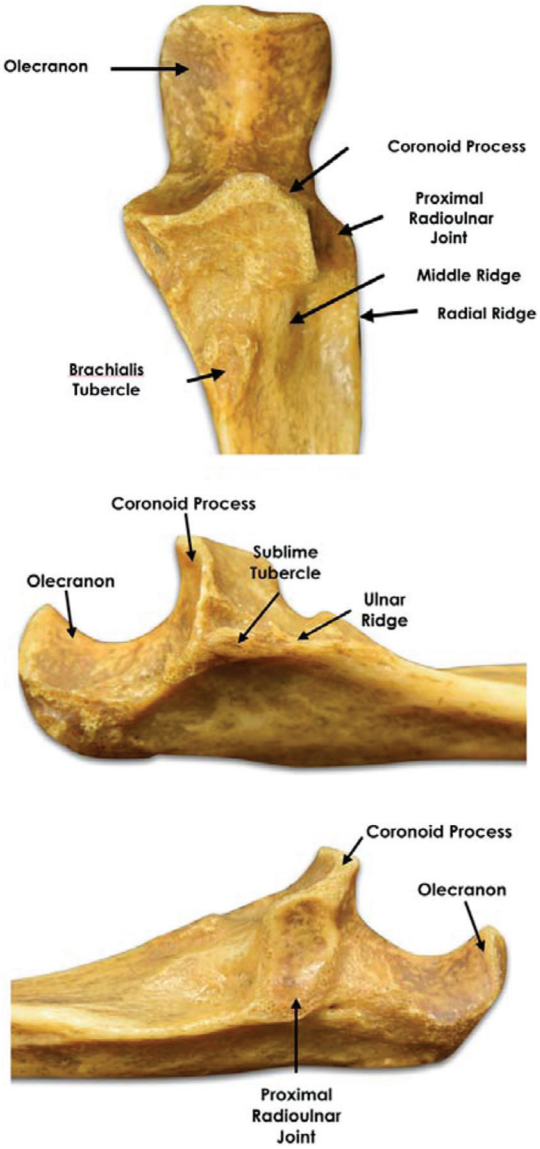

Figure 2. Relevant bony landmarks of the proximal ulna.

Anatomic Joint Coordinate Frame Definition

A joint coordinate frame was established to present distance data along the anatomic axes.[33,34] The superior direction was defined using the long axis of the humerus and calculated by interpolating a line through the centers of 3 rings of points collected around the humeral shaft. The anterior axis was defined as mutually perpendicular to the superior axis and to the axis passing through the medial and lateral humeral epicondyles. The lateral axis was defined as mutually perpendicular to the superior and anterior axes.

Quantitative Measurements and Statistical Analysis

The data collected were transferred to Matlab and analyzed using custom software. Footprint areas were calculated by creating a best-fit plane through the points taken along the circumference, projecting the points onto the plane, and computing the area of the resulting 2D polyhedron. Distance measurements were taken as the 3D linear distance between structures and deconstructed onto the 3 anatomic axes defined above. These measurements were taken between the centers of 2 structures, unless otherwise specified. Ligament lengths were estimated by calculating the direct 3D distance between the centers of the ligament's attachment sites. For each measurement, the mean of the 10 specimens and the 95% CI were computed.

RESULTS

Qualitative Anatomy

Three bundles of the UCL were consistently identified in all specimens. On the humerus, the anterior bundle of the UCL attached distal and lateral to the medial epicondyle. The posterior bundle of the UCL attached distal and lateral to the medial epicondyle, posterior to the anterior bundle, with the footprints of the 2 bundles separated by a bony ridge. On the ulna, the anterior bundle of the UCL attached just distal to the joint line on the sublime tubercle, with the footprint extending distally along the ulnar ridge (Figures 2 and 3). The posterior bundle of the UCL attached deep to the oblique bundle of the UCL, posterior to the joint line. Both of the oblique bundle attachments were located on the ulna, including the anterior attachment, closer to the ulnar ridge, and the posterior attachment located between the joint line and the olecranon (Figure 3).

The brachialis muscle had a broad attachment on the anterior surface of the proximal ulna, on the brachialis tubercle, distal to the coronoid process and lateral to both the sublime tubercle and ulnar ridge (Figure 3). It also extended proximally, with muscular insertions on the anterior capsule. The flexor digitorum superficialis (FDS) had a tendinous ulnar attachment, just medial to the ulnar ridge, with fibers attached to the anterior bundle of the UCL (Figure 3). Furthermore, the FDS extended proximally across the joint line, with a muscular attachment spanning the anteromedial capsule to its common insertion on the medial epicondyle (Figure 4). The pronator teres had 3 distinct attachments: one on the humerus, proximal to the common flexor attachment, and a thin tendinous band on the ulna between the brachialis and the anterior bundle of the UCL and on the radius shaft. The flexor carpi ulnaris (FCU) also had a distinct tendinous insertion on the sublime tubercle and ulnar ridge, with fibers inserting on the anterior and oblique bundles of the UCL and muscular fibers along the entire oblique bundle of the UCL (Figure 4).

Quantitative Anatomy

Ulnar Collateral Ligament. The center of the humeral footprint of the anterior bundle was 8.5 mm (95% CI, 6.9-10.0) distal and 7.8 mm (95% CI, 6.6-9.1) lateral to the

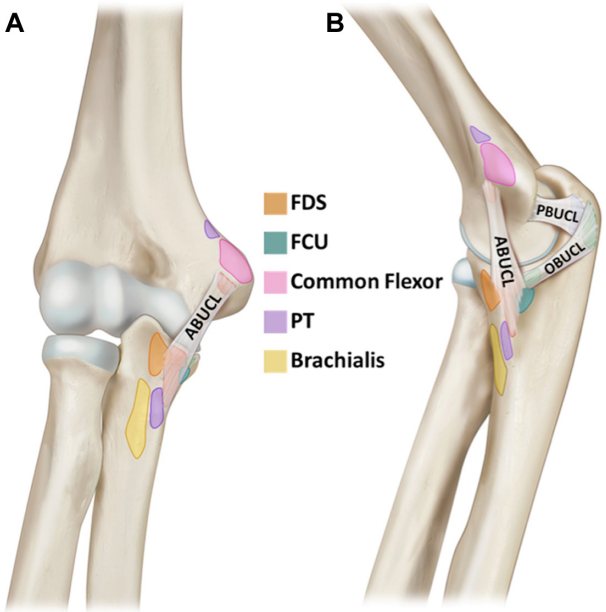

Figure 3. (A) Anterior and (B) medial views of an elbow, demonstrating the 3 bundles of the ulnar collateral ligament (UCL) and the relationship between the anterior bundle of the UCL and the musculotendinous insertions of the flexor pronator mass, with the footprints represented by different colors. ABUCL, anterior bundle of the UCL; FCU, ulnar carpi ulnaris; FDS, flexor digitorum superficialis; OBUCL, oblique bundle of the UCL; PBUCL, posterior bundle of the UCL.

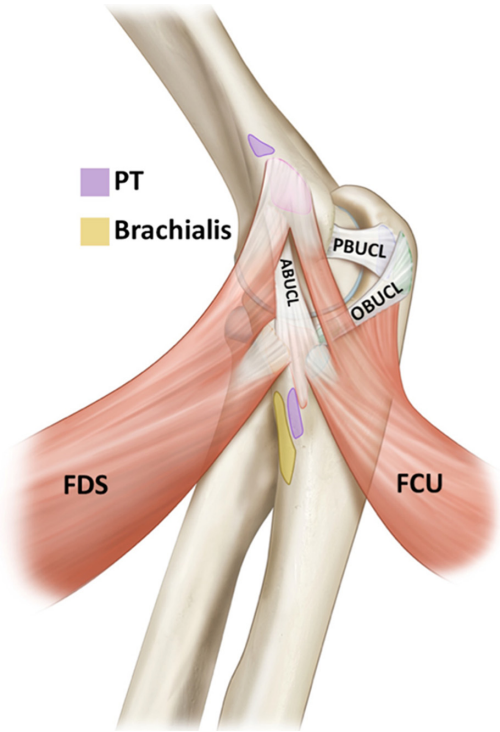

Figure 4. Medial view of an elbow, demonstrating the 3 bundles of the ulnar collateral ligament (UCL) and the relationship between the anterior bundle of the UCL and the musculotendinous insertions of the flexor pronator mass. ABUCL, anterior bundle of the UCL; FCU, ulnar carpi ulnaris; FDS, flexor digitorum superficialis; OBUCL, oblique bundle of the UCL; PBUCL, posterior bundle of the UCL.

medial epicondyle. The center of the anterior bundle's ulnar footprint was 1.5 mm (95% CI, 0.5-2.5) distal to the sublime tubercle along the ulnar ridge. The ulnar footprint of the anterior bundle attached closer to the joint line than the humeral attachment, with the center of the humeral and ulnar attachments 15.4 mm (95% CI, 13.9-16.9) and 7.3 mm (95% CI, 6.1-8.5) from the joint line, respectively.

The posterior bundle's humeral footprint was 7.2 mm (95% CI, 6.0-8.3) distal and 9.5 mm (95% CI, 8.4-10.7) lateral to the medial epicondyle. The posterior bundle's ulnar footprint was 1.6 mm (95% CI, –4.4 to 1.1) distal and 9.8 mm (95% CI, 8.0 to 11.6) anterior to the olecranon tip and 4.4 mm (95% CI, 3.4 to 5.4) posterior to the joint line. Ligament lengths and areas of the footprints are reported in Table 2. Additional measurements regarding the UCL can be found in Tables 3, 5, and 6.

Tendon Attachments on the Humerus. The pronator teres attached proximal to the common flexor footprint 9.4 mm (95% CI, 6.5-12.3) proximal to the medial epicondyle. The center of the common flexor pronator attachment was 4.4 mm (95% CI, 2.9-5.9) anterior to the medial epicondyle.

Tendon Attachments on the Ulna. The ulnar attachment of the pronator teres was 14.5 mm (95% CI, 11.9-17.2) distal to the center of the sublime tubercle and 24.3 mm (95% CI, 20.6-28.0) distal to the joint line, adjacent to the ulnar ridge. The ulnar head of the FDS had tendinous insertions on the radial aspect of the anterior bundle of the UCL, 6.8 mm (95% CI, 3.6-10.0) distal to the center of the sublime tubercle and 11.3 mm (95% CI, 8.7-13.9) distal to the joint line, adjacent to the ulnar ridge.

The FDS attachment onto the distal aspect of the anterior bundle spanned 45.6% (95% CI, 38.1-53.6) of the total length of that bundle. The FCU had a tendinous insertion with an area of 20.2 mm^2 (95% CI, 16.4-24.0) near the

TABLE 2
Footprint Areas of the Ulnar Collateral Ligament Bundles on the Humerus and Ulna[a]

	Footprint Area, mm^2	Ligament Length,[b] mm
Anterior		21.5 (20.0-23.0)
Ulnar	66.4 (54.0-78.7)	
Humeral	17.0 (14.9-19.1)	
Posterior		15.0 (13.5-16.5)
Ulnar	18.5 (13.6-23.4)	
Humeral	17.6 (14.7-20.6)	
Oblique		13.9 (12.0-15.8)
Anterior ulnar	15.9 (13.0-18.7)	
Posterior ulnar	16.1 (12.5-19.7)	

[a]Data are presented as mean (95% CI).
[b]Ligament lengths were calculated using the center of both footprints.

TABLE 3
Distances From the Medial Epicondyle to the Center of the Footprints and Distances Between the Ulnar Collateral Ligament Attachments on the Humerus[a]

	Total	Anterior	Proximal	Lateral
Distance from medial epicondyle, mm				
ABUCL	12.9 (11.4 to 14.5)	5.5 (4.7 to 6.2)	–8.5 (−10.0 to −6.9)	7.8 (6.6 to 9.1)
PBUCL	12.5 (11.2 to 13.7)	2.4 (1.0 to 3.8)	–7.2 (−8.3 to −6.0)	9.5 (8.4 to 10.7)
Pronator teres	12.7 (9.8 to 15.7)	2.4 (0.8 to 4.0)	9.4 (6.5 to 12.3)	7.4 (5.6 to 9.2)
Common flexor	6.3 (4.3 to 8.3)	4.4 (2.9 to 5.9)	–1.5 (−3.7 to 0.7)	2.6 (1.3 to 4.0)
Distance from center of ABUCL, mm				
PBUCL	21.5 (20.0 to 23.0)	–2.6 (−4.7 to −6.0)	–18.5 (−19.8 to −17.1)	10.1 (8.8 to 11.4)

[a]Data in parentheses are presented as 95% CI. ABUCL, anterior bundle of the ulnar collateral ligament; PBUCL, posterior bundle of the ulnar collateral ligament.

TABLE 4
Footprint Areas of the Medial Muscle Attachments[a]

	Area, mm^2		
	Ulnar Footprint	Humeral Footprint	Radial Footprint
FDS	40.7 (32.2-49.1)		
FCU	20.2 (16.4-24.0)		
Common flexor (FCR, FCU, FDS)		127.9 (89.5-166.3)	
Pronator teres	34.3 (25.1-43.5)	40.1 (33.3-47.0)	101.0 (75.6-126.5)
Brachialis	83.6 (64.1-103.1)		

[a]Data are presented as mean (95% CI). FCR, flexor carpi radialis; FCU, flexor carpi ulnaris; FDS, flexor digitorum superficialis.

sublime tubercle, 4.2 mm (95% CI, 3.4-5.0) distal to the joint line, and 1.7 mm (95% CI, 0.5-3.0) posterior to the ulnar ridge. The FCU attachment overlapped with 20.9% (95% CI, 7.2-34.5) of the total area of the anterior bundle of the UCL. Additional measurements of the muscular attachments to surgically relevant landmarks can be found in Tables 4, 5, and 6.

DISCUSSION

The most important findings of this study are the reproducible quantitative relationships of the UCL footprints and the direct tendinous insertions of the FCU and FDS onto the distal insertion of the anterior bundle of the UCL. This relationship supports previous clinical studies that reported concomitant flexor pronator mass injuries in patients with UCL tears.[3,4,8,10,21] In addition, this could explain the increased failure rates associated with the nonoperative management of ulnar-sided tears of the UCL in throwing athletes.[13]

In the present study, the FCU, pronator teres, and FDS had tendon fibers merging in close proximity to the anterior bundle of the UCL. Specifically, the FDS tendon attached along 45.6% of the distal length of the anterior bundle, and the FCU tendon overlapped with 20.9% of the distal (ulnar) footprint of the anterior bundle of the UCL. The pronator teres attached along the distal lateral border of the anterior bundle, along the ulnar ridge, just medial to the brachialis insertion. We believe that this intimate association of the dynamic stabilizers with the distal aspect of the anterior bundle may contribute to the increased failure rates seen with the nonoperative management of distal ulnar-sided UCL tears versus proximal humeral-sided tears in professional pitchers.[13] It could also contribute to the negative outcomes associated with flexor pronator morbidity in early UCL reconstruction techniques, which did not preserve the flexor pronator mass attachment.[17,31] When reviewing the technical aspects of each of the modern reconstruction techniques, there is no mention of the relationship of the ulnar insertions of the FDS, FCU, or pronator teres on the anterior bundle of the UCL.[1,5,7,11,18,26]

Regardless of the fixation method for UCL reconstruction, the identification of these structures in relation to the joint line and bony landmarks should be useful for determining the optimal position of reconstruction graft tunnels to reduce morbidity to surrounding structures. When interference screw fixation is utilized, a tunnel can be positioned at the center of the anterior bundle of the UCL, 0.3 mm anterior, 1.5 mm distal, and 1.4 mm lateral from the center of the sublime tubercle and 7.3 mm distal from the ulnohumeral joint line (Figure 5). The sublime tubercle provides a bony landmark on the proximal ulna and is often utilized to determine positioning of the UCL reconstruction tunnel. The sublime tubercle is a reliable landmark on the medial side of the proximal ulna. In an anatomic study, Farrow et al[12] identified the sublime tubercle and an osseous ridge in all 100 skeletally mature

TABLE 5
Distances From the Pertinent Landmarks on the Ulna to the Center of the Ulnar Collateral Ligament and Muscular Footprints[a]

Ulnar Bony Landmarks	Total	Anterior	Proximal	Lateral
Distance from sublime tubercle, mm				
ABUCL	2.5 (1.3 to 3.7)	0.3 (−0.4 to 1.0)	–1.5 (−2.5 to −0.5)	1.4 (0.4 to 2.4)
PBUCL	24.7 (22.8 to 26.6)	–13.1 (−15.0 to −11.2)	20.7 (18.8 to 22.6)	–1.0 (−2.0 to 0.0)
Anterior OBUCL	5.5 (4.0 to 7.0)	–4.0 (−5.4 to −2.7)	3.4 (2.4 to 4.3)	0.6 (−0.1 to 1.3)
Posterior OBUCL	19.2 (16.7 to 21.7)	–13.5 (−15.4 to −11.6)	13.2 (10.7 to 15.6)	1.3 (0.3 to 2.3)
Pronator teres	20.4 (16.8 to 23.9)	–1.5 (−4.3 to 1.3)	–14.5 (−17.2 to −11.9)	13.4 (10.7 to 16.1)
FDS	10.9 (7.2 to 14.5)	–0.1 (−2.0 to 1.8)	–6.8 (−10.0 to −3.6)	7.6 (5.5 to 9.8)
FCU	4.2 (2.7 to 5.7)	–1.9 (−2.9 to −0.8)	1.3 (−0.6 to 3.2)	0.5 (−1.2 to 2.2)
Brachialis	24.5 (23.2 to 25.7)	0.9 (−1.4 to 3.1)	–16.2 (−17.5 to −14.9)	17.9 (16.7 to 19.0)
Distance from ulnohumeral joint line, mm				
ABUCL	7.3 (6.1 to 8.5)	–2.3 (−3.3 to −1.3)	–6.3 (−7.4 to −5.2)	1.8 (0.6 to 3.0)
PBUCL	6.4 (4.1 to 8.8)	–4.4 (−5.4 to −3.4)	2.9 (0.3 to 5.5)	–1.3 (−2.9 to 0.3)
Anterior OBUCL	5.0 (4.0 to 6.1)	–3.4 (−5.0 to −1.9)	–2.8 (−3.4 to −2.1)	0.8 (−0.1 to 1.7)
Posterior OBUCL	6.4 (5.0 to 7.8)	–5.5 (−6.6 to −4.5)	–1.0 (−2.8 to 0.8)	–0.7 (−1.9 to 0.6)
Pronator teres	24.3 (20.6 to 28.0)	–5.7 (−9.9 to −1.5)	–19.1 (−21.8 to −16.3)	12.5 (10.2 to 14.8)
FDS	14.8 (11.4 to 18.2)	–3.8 (−6.3 to −1.3)	–11.3 (−13.9 to −8.7)	7.9 (5.7 to 10.0)
FCU	5.8 (4.8 to 6.9)	–2.8 (−4.0 to −1.7)	–4.2 (−5.0 to −3.4)	0.9 (−0.6 to 2.4)
Brachialis	27.6 (25.8 to 29.3)	–5.0 (−9.1 to −1.0)	–20.3 (−22.5 to −18.1)	16.6 (15.2 to 18.0)
Sublime tubercle	5.8 (4.5 to 7.0)	–1.8 (−2.4 to −1.1)	–5.2 (−6.4 to −4.0)	0.5 (−0.4 to 1.4)
Distance from ulnar ridge, mm				
ABUCL	3.7 (0.9 to 6.6)	0.5 (−0.5 to 1.4)	1.8 (−0.2 to 3.9)	–2.1 (−4.5 to 0.2)
PBUCL	25.9 (23.9 to 27.9)	–13.4 (−15.8 to −11.1)	21.1 (18.9 to 23.3)	–2.5 (−5.6 to 0.6)
Anterior OBUCL	8.1 (5.6 to 10.6)	–4.2 (−5.8 to −2.6)	4.6 (2.0 to 7.2)	–1.3 (−4.1 to 1.4)
Posterior OBUCL	20.3 (18.0 to 22.5)	–13.8 (−16.1 to −11.6)	13.6 (11.0 to 16.2)	–0.3 (−3.1 to 2.6)
Pronator teres	1.9 (1.1 to 2.8)	0.2 (−0.5 to 1.0)	0.4 (−0.4 to 1.1)	0.6 (−0.3 to 1.6)
FDS	2.9 (1.4 to 4.5)	0.7 (−0.3 to 1.7)	1.2 (−0.3 to 2.7)	–0.5 (−2.0 to 1.0)
FCU	6.0 (3.5 to 8.5)	–1.7 (−3.0 to −0.5)	3.7 (1.6 to 5.7)	–2.5 (−5.0 to 0.0)
Distance from coronoid process, mm				
ABUCL	20.6 (18.6 to 22.5)	–12.9 (−14.5 to −11.2)	–11.2 (−12.7 to −9.7)	–10.8 (−13.0 to −8.6)
PBUCL	31.8 (30.2 to 33.4)	–26.2 (−28.5 to −24.0)	10.9 (8.6 to 13.2)	–13.2 (−15.4 to −10.9)
Anterior OBUCL	22.0 (19.9 to 24.1)	–17.2 (−19.3 to −15.0)	–6.4 (−7.5 to −5.2)	–11.6 (−13.8 to −9.4)
Posterior OBUCL	29.4 (27.2 to 31.7)	–26.6 (−29.2 to −24.1)	3.4 (1.2 to 5.6)	–10.9 (−13.0 to −8.8)
Pronator teres	29.3 (25.7 to 32.9)	–14.6 (−17.6 to −11.6)	–24.3 (−27.5 to −21.0)	1.2 (−2.9 to 5.3)
FDS	22.7 (19.9 to 25.4)	–13.2 (−15.6 to −10.9)	–16.6 (−19.5 to −13.6)	–4.6 (−8.0 to −1.1)
FCU	21.4 (19.7 to 23.1)	–15.0 (−16.7 to −13.3)	–8.4 (−9.5 to −7.4)	–11.7 (−14.7 to −8.8)
Distance from olecranon, mm				
PBUCL	15.2 (11.4 to 18.9)	9.8 (8.0 to 11.6)	–1.6 (−4.4 to 1.1)	–8.7 (−13.9 to −3.5)
Posterior OBUCL	17.0 (13.4 to 20.5)	9.4 (7.0 to 11.8)	–9.2 (−12.0 to −6.3)	–6.5 (−12.0 to −0.9)

[a]Data in parentheses are presented as 95% CI. ABUCL, anterior bundle of the ulnar collateral ligament; FCU, flexor carpi ulnaris; FDS, flexor digitorum superficialis; OBUCL, oblique bundle of the ulnar collateral ligament; PBUCL, posterior bundle of the ulnar collateral ligament.

human cadaveric ulnae. The sublime tubercle and the medial UCL ridge were reported to be the attachment site for the anterior bundle of the UCL.[12] In the present study, the center of the sublime tubercle was 5.2 mm distal to the elbow joint line and 2.3 mm, 3.3 mm, 5.2 mm, and 14.6 mm from the nearest edge of the ulnar insertions of the FCU, oblique bundle of the UCL, FDS, and pronator teres, respectively. These relationships are useful references when deciding on the optimal placement of the ulnar tunnel in UCL reconstruction, especially when traction spurs on the sublime tubercle distort normal anatomic contours. In these cases, the relationship of surrounding structures can help guide osteophyte removal, reveal the native tubercle, and avoid a nonanatomic reconstruction tunnel position. The center of the anterior bundle UCL insertion was 3.8 mm, 2.6 mm, 4.6 mm, and 12.7 mm from the nearest edge of the ulnar insertions of the FDS, FCU, oblique bundle of the UCL, and pronator teres, respectively. Additionally, the proximity of these tendinous insertions should not be underestimated during medial elbow approaches and UCL reconstruction. There are several commercially available systems that utilize a drilling guide system for ulnar tunnel placement that require the release of most of the discussed attachments around the sublime tubercle to allow for guide placement. Excessive release in this case may compromise the dynamic component of stability postoperatively or become a pain generator during activation, especially in high-level throwing athletes.

TABLE 6
Distances Between the Centers of the Ulnar Collateral Ligaments and to Other Soft Tissue Footprints From the Ulnar Anterior Bundle Attachment[a]

Ulnar Attachments	Total	Anterior	Proximal	Lateral
Distance from center of ABUCL, mm				
PBUCL	26.2 (24.2 to 28.2)	–13.4 (−15.3 to −11.5)	22.1 (20.1 to 24.2)	–2.3 (−3.6 to −1.1)
Anterior OBUCL	7.0 (5.6 to 8.3)	–4.3 (−5.4 to −3.2)	4.8 (3.8 to 5.9)	–0.8 (−2.1 to 0.6)
Posterior OBUCL	20.4 (18.0 to 22.9)	–13.8 (−15.8 to −11.7)	14.6 (12.1 to 17.1)	–0.1 (−1.2 to 1.0)
FCU	4.6 (3.0 to 6.3)	–2.2 (−3.0 to −1.4)	2.8 (1.2 to 4.3)	–0.9 (−2.7 to 0.9)
Pronator teres	18.3 (13.9 to 22.8)	–1.8 (−4.3 to 0.7)	–13.1 (−16.2 to −9.9)	12.0 (8.6 to 15.4)
FDS	9.2 (5.7 to 12.7)	–0.4 (−2.2 to 1.4)	–5.4 (−8.3 to −2.4)	6.3 (3.6 to 8.9)
Brachialis	22.5 (20.7 to 24.2)	0.6 (−1.6 to 2.7)	–14.7 (−15.8 to −13.7)	16.5 (14.7 to 18.4)
Distance from center of anterior OBUCL, mm				
PBUCL	19.8 (18.0 to 21.5)	–9.1 (−10.6 to −7.6)	17.3 (15.6 to 19.0)	–1.6 (−2.5 to −0.6)
Distance from center of posterior OBUCL, mm				
PBUCL	8.0 (6.7 to 9.4)	0.4 (−0.5 to 1.3)	7.5 (6.2 to 8.9)	–2.2 (−2.8 to −1.7)

[a]Data in parentheses are presented as 95% CI. ABUCL, anterior bundle of the ulnar collateral ligament; FCU, flexor carpi ulnaris; FDS, flexor digitorum superficialis; OBUCL, oblique bundle of the ulnar collateral ligament; PBUCL, posterior bundle of the ulnar collateral ligament.

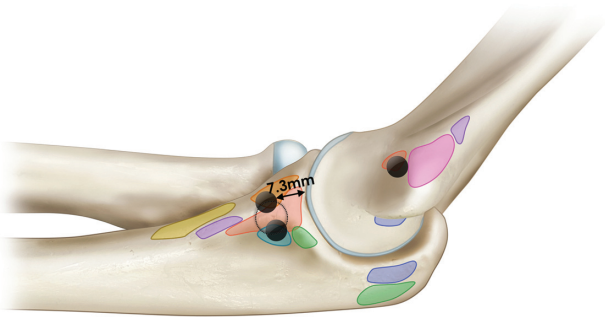

Figure 5. Tunnel positions for ulnar collateral ligament reconstruction. If a 2-tunnel technique is used, they can be placed on both sides of the ridge, 7.3 mm from the joint line (black circles). It is worth noting that for a 2-tunnel technique, muscle attachments on the anterior surface of the proximal ulna have to be released. If a single tunnel is used, it should be placed along the ridge, just distal to the sublime tubercle and 7.3 mm distal to the joint line.

The close anatomic proximity of the anterior bundle of the UCL to the insertions of the FCU, FDS, and pronator teres found in this study supports previous biomechanical studies that demonstrated the importance of the flexor pronator musculature for dynamic stability of the elbow.[19,23] Davidson et al[9] reported that the FCU and FDS were optimally oriented in line with the UCL to contribute to dynamic elbow valgus stability.[30] The combination of large valgus loads with rapid elbow extension produces tensile stress along the medial compartment restraints (UCL, flexor pronator mass) and forms the basic pathophysiological model behind the most common elbow injuries in the throwing athlete.[6,19,32] Injuries to the flexor pronator mass are common and present as a spectrum of abnormalities from mild muscular overuse to chronic tendinitis or acute muscle tears. In this regard, Park and Ahmad[23] evaluated the role of the flexor pronator group in UCL-deficient elbows and reported that contraction of the FCU and FDS resulted in the greatest stability to the UCL-deficient elbow compared with the other surrounding musculature. Clinical electromyography studies aimed at defining the flexor contraction pattern during the pitching motion have reported that pitchers with symptomatic valgus instability have decreased flexor pronator mass activity.[14,16]

A recent study evaluated the failure of the nonoperative management of UCL injuries in professional pitchers and found an increased failure rate in distal tears compared with proximal tears.[13] The nonoperative management of these injuries usually involves a period of immobilization, followed by a gradual return to a throwing program. Contractile forces of the flexor pronator musculature have been reported to resist valgus stress during early arm acceleration and help produce wrist flexion during ball release.[27] Because of the activation of the flexor pronator musculature during the throwing motion, ulnar-sided tears could be at risk for increased stress during throwing because of the attachments of the FDS, FCU, and pronator teres on the distal part of the ligament. This micromotion could impede healing of distal UCL injuries. Finally, regardless of surgical or nonoperative intervention, this relationship of the UCL and the surrounding flexor pronator attachments becomes important when considering rehabilitation and preventative strategies. A primary focus should be directed on strengthening the musculature surrounding the UCL for injury prevention and stability of the capsule and underlying ligaments.

We recognize that the present study has some limitations inherent to a cadaveric study design. Although a detailed dissection was performed to clearly visualize the anatomic attachments, fiber direction, and attachment sites, distances were calculated as 2D distances, which may have resulted in an underestimation of structure lengths. However, the method used for data collection has been demonstrated to

be highly repeatable.[2,15] Two board-certified orthopaedic surgeons with experience in anatomic dissections performed all the dissections and data collection.

CONCLUSION

The most important findings of this study are the quantitative anatomy of the UCL bundle attachments and its relationship to surgically relevant bony landmarks. The ulnar limb of the FDS and FCU tendons demonstrated consistent insertions onto the ulnar attachment of the anterior bundle of the UCL. Excessive stripping of the sublime tubercle should be avoided during UCL reconstruction to prevent violation of these tendinous attachments. The data allow for reproducible landmarks to be established from previously known bony and soft tissue structures and provide a clear understanding of the anatomic relationships of the static and dynamic stabilizers of the elbow, which could ultimately influence the operative and nonoperative management of injuries to these structures in throwing athletes.

ACKNOWLEDGMENT

The authors acknowledge Andy Evansen for the medical illustrations and Carly Lockard and Daniel Marchetti for their assistance with anatomic imaging.

REFERENCES

1. Ahmad CS, Lee TQ, ElAttrache NS. Biomechanical evaluation of a new ulnar collateral ligament reconstruction technique with interference screw fixation. *Am J Sports Med*. 2003;31(3):332-337.
2. Anavian J, Marchetti DC, Moatshe G, et al. The forgotten joint: quantifying the anatomy of the proximal tibiofibular joint [published online March 20, 2017]. *Knee Surg Sports Traumatol Arthrosc*. doi:10.1007/s00167-017-4508-8.
3. Andrews JR, Jost PW, Cain EL. The ulnar collateral ligament procedure revisited: the procedure we use. *Sports Health*. 2012;4(5):438-441.
4. Barnes DA, Tullos HS. An analysis of 100 symptomatic baseball players. *Am J Sports Med*. 1978;6(2):62-67.
5. Bowers AL, Dines JS, Dines DM, Altchek DW. Elbow medial ulnar collateral ligament reconstruction: clinical relevance and the docking technique. *J Shoulder Elbow Surg*. 2010;19(2 Suppl):110-117.
6. Centers for Disease Control and Prevention. Trends in strength training: United States, 1998-2004. *MMWR Morb Mortal Wkly Rep*. 2006;55(28):769-772.
7. Conway JE. The DANE TJ procedure for elbow medial ulnar collateral ligament insufficiency. *Tech Shoulder Elbow Surg*. 2006;7(1):36-43.
8. Conway JE, Jobe FW, Glousman RE, Pink M. Medial instability of the elbow in throwing athletes: treatment by repair or reconstruction of the ulnar collateral ligament. *J Bone Joint Surg Am*. 1992;74(1):67-83.
9. Davidson PA, Pink M, Perry J, Jobe FW. Functional anatomy of the flexor pronator muscle group in relation to the medial collateral ligament of the elbow. *Am J Sports Med*. 1995;23(2):245-250.
10. Dodson CC, Altchek DW. Ulnar collateral ligament reconstruction revisited: the procedure I use and why. *Sports Health*. 2012;4(5):433-437.
11. Dugas JR, Ostrander RV, Cain EL, Kingsley D, Andrews JR. Anatomy of the anterior bundle of the ulnar collateral ligament. *J Shoulder Elbow Surg*. 2007;16(5):657-660.
12. Farrow LD, Mahoney AJ, Stefancin JJ, Taljanovic MS, Sheppard JE, Schickendantz MS. Quantitative analysis of the medial ulnar collateral ligament ulnar footprint and its relationship to the ulnar sublime tubercle. *Am J Sports Med*. 2011;39(9):1936-1941.
13. Frangiamore SJ, Lynch TS, Vaughn MD, et al. Magnetic resonance imaging predictors of failure in the nonoperative management of ulnar collateral ligament injuries in professional baseball pitchers. *Am J Sports Med*. 2017;45(8):1783-1789.
14. Glousman RE, Barron J, Jobe FW, Perry J, Pink M. An electromyographic analysis of the elbow in normal and injured pitchers with medial collateral ligament insufficiency. *Am J Sports Med*. 1992;20(3):311-317.
15. Godin JA, Chahla J, Moatshe G, et al. A comprehensive reanalysis of the distal iliotibial band: quantitative anatomy, radiographic markers, and biomechanical properties. *Am J Sports Med*. 2017;45(11):2595-2603.
16. Hamilton CD, Glousman RE, Jobe FW, Brault J, Pink M, Perry J. Dynamic stability of the elbow: electromyographic analysis of the flexor pronator group and the extensor group in pitchers with valgus instability. *J Shoulder Elbow Surg*. 1996;5(5):347-354.
17. Jobe FW, Stark H, Lombardo SJ. Reconstruction of the ulnar collateral ligament in athletes. *J Bone Joint Surg Am*. 1986;68(8):1158-1163.
18. Lee GH, Limpisvasti O, Park MC, McGarry MH, Yocum LA, Lee TQ. Revision ulnar collateral ligament reconstruction using a suspension button fixation technique. *Am J Sports Med*. 2010;38(3):575-580.
19. Lin F, Kohli N, Perlmutter S, Lim D, Nuber GW, Makhsous M. Muscle contribution to elbow joint valgus stability. *J Shoulder Elbow Surg*. 2007;16(6):795-802.
20. Morrey BF, An KN. Articular and ligamentous contributions to the stability of the elbow joint. *Am J Sports Med*. 1983;11(5):315-319.
21. Norwood LA, Shook JA, Andrews JR. Acute medial elbow ruptures. *Am J Sports Med*. 1981;9(1):16-19.
22. Otoshi K, Kikuchi S, Shishido H, Konno S. Ultrasonographic assessment of the flexor pronator muscles as a dynamic stabilizer of the elbow against valgus force. *Fukushima J Med Sci*. 2014;60(2):123-128.
23. Park MC, Ahmad CS. Dynamic contributions of the flexor-pronator mass to elbow valgus stability. *J Bone Joint Surg Am*. 2004;86(10):2268-2274.
24. Regan WD, Korinek SL, Morrey BF, An KN. Biomechanical study of ligaments around the elbow joint. *Clin Orthop Relat Res*. 1991;271:170-179.
25. Rettig AC, Sherrill C, Snead DS, Mendler JC, Mieling P. Nonoperative treatment of ulnar collateral ligament injuries in throwing athletes. *Am J Sports Med*. 2001;29(1):15-17.
26. Rohrbough JT, Altchek DW, Hyman J, Williams RJ 3rd, Botts JD. Medial collateral ligament reconstruction of the elbow using the docking technique. *Am J Sports Med*. 2002;30(4):541-548.
27. Sisto DJ, Jobe FW, Moynes DR, Antonelli DJ. An electromyographic analysis of the elbow in pitching. *Am J Sports Med*. 1987;15(3):260-263.
28. Smith GR, Altchek DW, Pagnani MJ, Keeley JR. A muscle-splitting approach to the ulnar collateral ligament of the elbow: neuroanatomy and operative technique. *Am J Sports Med*. 1996;24(5):575-580.
29. Sojbjerg JO, Ovesen J, Nielsen S. Experimental elbow instability after transection of the medial collateral ligament. *Clin Orthop Relat Res*. 1987;218:186-190.
30. Udall JH, Fitzpatrick MJ, McGarry MH, Leba TB, Lee TQ. Effects of flexor-pronator muscle loading on valgus stability of the elbow with an intact, stretched, and resected medial ulnar collateral ligament. *J Shoulder Elbow Surg*. 2009;18(5):773-778.
31. Watson JN, McQueen P, Hutchinson MR. A systematic review of ulnar collateral ligament reconstruction techniques. *Am J Sports Med*. 2014;42(10):2510-2516.
32. Wilson FD, Andrews JR, Blackburn TA, McCluskey G. Valgus extension overload in the pitching elbow. *Am J Sports Med*. 1983;11(2):83-88.
33. Wu G, Cavanagh PR. ISB recommendations for standardization in the reporting of kinematic data. *J Biomech*. 1995;28(10):1257-1261.
34. Wu G, van der Helm FC, Veeger HE, et al. ISB recommendation on definitions of joint coordinate systems of various joints for the reporting of human joint motion, part II: shoulder, elbow, wrist and hand. *J Biomech*. 2005;38(5):981-992.