

# Anterolateral Knee Extra-articular Stabilizers

## A Robotic Study Comparing Anterolateral Ligament Reconstruction and Modified Lemaire Lateral Extra-articular Tenodesis

Andrew G. Geeslin,\* MD, Gilbert Moatshe,\*<sup>†‡</sup> MD, Jorge Chahla,\* MD, PhD, Bradley M. Kruckeberg,\* BA, Kyle J. Muckenhirn,\* BA, Grant J. Dornan,\* MSc, Ashley Coggins,\* BS, Alex W. Brady,\* MSc, Alan M. Getgood,<sup>§</sup> MD, Jonathan A. Godin,\* MD, MBA, and Robert F. LaPrade,\*<sup>||¶</sup> MD PhD  
*Investigation performed at Steadman Philippon Research Institute, Vail, Colorado, USA*

---

**Background:** Persistent clinical instability after anterior cruciate ligament (ACL) reconstruction may be associated with injury to the anterolateral structures and has led to renewed interest in anterolateral extra-articular procedures. The influence of these procedures on knee kinematics is controversial.

**Purpose/Hypothesis:** The purpose was to investigate the biomechanical properties of anatomic anterolateral ligament (ALL) reconstruction and a modified Lemaire procedure (lateral extra-articular tenodesis [LET]) in combination with ACL reconstruction as compared with isolated ACL reconstruction in the setting of deficient anterolateral structures (ALL and Kaplan fibers). It was hypothesized that both techniques would reduce tibial internal rotation when combined with ACL reconstruction in the setting of anterolateral structure deficiency.

**Study Design:** Controlled laboratory study.

**Methods:** A 6 degrees of freedom robotic system was used to assess tibial internal rotation, a simulated pivot-shift test, and anterior tibial translation in 10 paired fresh-frozen cadaveric knees. The following states were tested: intact; sectioned ACL, ALL, and Kaplan fibers; ACL reconstruction; and an anterolateral extra-articular procedure (various configurations of ALL reconstruction and LET). Knees within a pair were randomly assigned to either ALL reconstruction or LET with a graft tension of 20 N and a randomly assigned fixation angle (30° or 70°). ALL reconstruction was then repeated and secured with a graft tension of 40 N.

**Results:** In the setting of deficient anterolateral structures, ACL reconstruction was associated with significantly increased residual laxity for tibial internal rotation (up to 4°) and anterior translation (up to 2 mm) laxity as compared with the intact state. The addition of ALL reconstruction or LET after ACL reconstruction significantly reduced tibial internal rotation in most testing scenarios to values lower than the intact state (ie, overconstraint). Significantly greater reduction in laxity with internal rotation and pivot-shift testing was found with the LET procedure than ALL reconstruction when compared with the intact state. Combined with ACL reconstruction alone, both extra-articular procedures restored anterior tibial translation to values not significantly different from the intact state with most testing scenarios (usually within 1 mm).

**Conclusion:** Residual laxity was identified after isolated ACL reconstruction in the setting of ALL and Kaplan fiber deficiency, and the combination of ACL reconstruction in this setting with either ALL reconstruction or the modified Lemaire LET procedure resulted in significant reductions in tibiofemoral motion at most knee flexion angles, although overconstraint was also identified. ALL reconstruction and LET restored anterior tibial translation to intact values with most testing states.

**Clinical Relevance:** ALL reconstruction and lateral extra-articular tenodesis have been described in combination with intra-articular ACL reconstruction to address rotational laxity. This study demonstrated that both procedures resulted in significant reductions of tibial internal rotation versus the intact state independent of graft tension or fixation angle, although anterior tibial translation was generally restored to intact values. The influence of overconstraint with anterolateral knee reconstruction

procedures has not been fully evaluated in the clinical setting and warrants continued evaluation based on the findings of this biomechanical study.

**Keywords:** anterior cruciate ligament; anterolateral rotational laxity; lateral extra-articular tenodesis; anterolateral ligament; iliotibial band (ITB); Kaplan fibers

Despite improved understanding of knee anatomy and the development of advanced reconstructive techniques, rotational knee instability may persist after anterior cruciate ligament (ACL) reconstruction. Several factors may account for this less-than-optimal outcome, including malpositioned tunnels,<sup>14</sup> missed meniscal root tears,<sup>13</sup> medial meniscal ramp lesions,<sup>2</sup> or injury to the anterolateral structures of the knee.<sup>27</sup>

Historically, lateral extra-articular tenodesis (LET) procedures were performed to treat knee laxity in the ACL-deficient knee, although this was before popularization of intra-articular ACL reconstructions.<sup>21</sup> In a systematic review of the biomechanical effects of several LET procedures, Slette et al<sup>21</sup> reported reduced tibial internal rotation as compared with the intact state. Although there has been concern for knee overconstraint and possible increased risk of osteoarthritis, a recent systematic review of clinical studies revealed no supporting evidence that LET procedures lead to osteoarthritis.<sup>4</sup> Thus, further correlation of time-zero biomechanical studies and clinical studies is necessary. Medium- and long-term follow-up clinical studies of modern combined ACL reconstruction and LET procedures will be necessary given these concerns.

Intra-articular ACL reconstructions have been augmented with LET procedures to address residual anterolateral rotational laxity, specifically the pivot-shift phenomenon. Hewison et al<sup>9</sup> performed a systematic review and meta-analysis to assess the influence of a combined ACL reconstruction and LET procedure. A reduction in pivot shift with the combined procedure was reported, although there were no significant differences in International Knee Documentation Committee (IKDC) scores when compared with ACL reconstruction alone in knees with short-term follow-up.

In recent years, there has been increasing interest in anterolateral ligament (ALL) reconstruction as a supplemental procedure to augment ACL reconstruction in patients with a high-grade pivot shift; however, biomechanical analyses have yielded conflicting results. Schon et al<sup>20</sup> reported that ALL reconstruction resulted in significant reduction of internal rotation to less than the intact state (ie, overconstraint), while other studies reported that ALL reconstruction did not

significantly reduce internal rotation or anterior translation and thus did not overconstrain knee kinematics (or aid in the control of persistent rotatory laxity).<sup>24,26</sup>

The purpose of this study was to investigate the kinematic influence of 2 procedures—*anatomic ALL reconstruction* and *modified Lemaire LET*—in combination with ACL reconstruction as compared with isolated ACL reconstruction in the setting of deficient anterolateral structures. We hypothesized that both techniques would reduce tibial internal rotation when combined with ACL reconstruction in the setting of anterolateral structure deficiency.

## METHODS

### Specimen Preparation

Ten paired ( $n = 20$ ) male cadaveric knees (mean age, 56 years; range, 48-62 years) were utilized for this study. The specimens were obtained from a tissue bank donated for the purpose of medical research. Institutional review board approval was not required for this laboratory investigation, which utilized de-identified cadaver specimens. Specimens without evidence of prior injury, surgical history, or gross anatomic abnormality were selected. Specimens were stored at  $-20^{\circ}\text{C}$  and thawed at room temperature for 24 hours before preparation. The femoral and tibial diaphyses were sectioned 20 cm from the joint line; all soft tissues within 10 cm of the joint line were preserved; and the remaining soft tissues were removed to allow potting in polymethyl methacrylate.

### Robotic Testing

Specimens were mounted in an inverted orientation in a custom fixture to a universal force-torque sensor (Delta F/T Transducer; ATI Industrial Automation) attached to the robotic end effector of a 6 degrees of freedom robotic system (KUKA KR 60-3; KUKA Robotics).<sup>20</sup> Knee kinematics were analyzed with measurement of internal rotation, pivot shift, and anterior tibial translation. An internal rotation torque of 5 N·m was applied at  $15^{\circ}$  increments

\*Address correspondence to Robert F. LaPrade, MD, PhD, Steadman Philippon Research Institute, The Steadman Clinic, 181 West Meadow Drive, Suite 400, Vail, CO 81657, USA (email: drlaprade@sprivail.org).

<sup>†</sup>Steadman Philippon Research Institute, Vail, Colorado, USA.

<sup>‡</sup>Oslo University Hospital and University of Oslo, Oslo, Norway.

<sup>§</sup>OSTRC, Norwegian School of Sports Sciences, Oslo, Norway.

<sup>¶</sup>Fowler Kennedy Sport Medicine Clinic, University of Western Ontario, London, Ontario, Canada.

<sup>||</sup>The Steadman Clinic, Vail, Colorado, USA.

One or more of the authors has declared the following potential conflict of interest or source of funding: Internal funding for this study was received from the Steadman Philippon Research Institute. A.G.G. has received educational support from Arthrex, Smith and Nephew, and DJO. G.M. has received research support from South Eastern Norway Health Authority and Arthrex Inc. A.M.G. has received research support from Arthrex Inc and Smith & Nephew and has been a consultant for Smith & Nephew, Conmed, Ossur, DePuy Synthes, and Ferring. R.F.L. has received research support from Arthrex Inc, Linvatec, Ossur, and Smith & Nephew; is a paid consultant for Arthrex Inc, Ossur, and Smith & Nephew; and has received intellectual property royalties from Arthrex Inc and Smith & Nephew.

from 0° to 90° of knee flexion to evaluate tibial internal rotation. The pivot-shift test was simulated by a combined 5-N·m internal rotation torque and a 10-N·m valgus torque<sup>6</sup> and performed at 15° and 30° of knee flexion, and anterior tibial translation and tibial internal rotation were measured. Anterior tibial translation was evaluated at 30° and 90° of knee flexion under an 88-N anterior tibial load.

### Surgical Technique

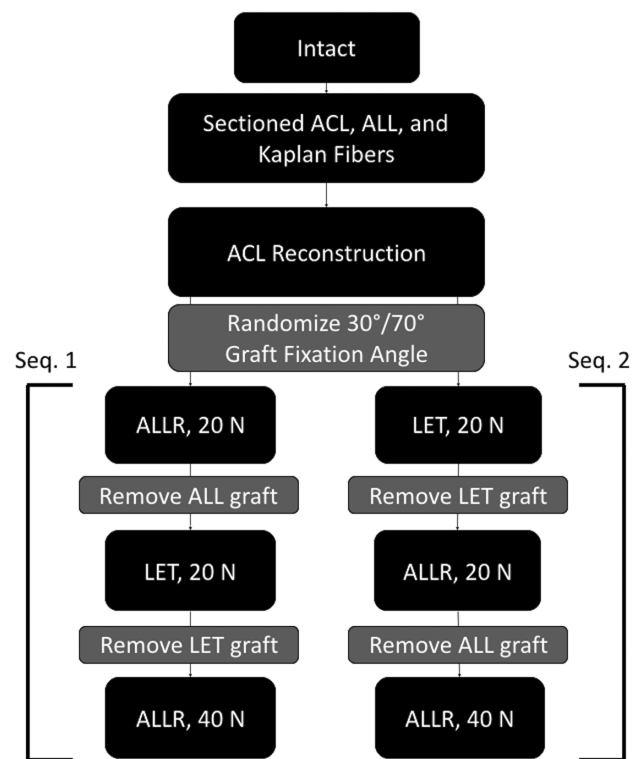
The ACL was sectioned midsubstance through an antero-medial arthrotomy. ALL sectioning was performed with the knee positioned at 75°, and a longitudinal incision was made on the posterior aspect of the superficial layer of the iliotibial band to identify the ALL attachment site on the tibia, midway between the Gerdy tubercle and the fibular head. The ALL was released from its tibial attachment at this location in accordance with previously described techniques.<sup>12,20</sup> The proximal and distal Kaplan fibers were identified and sectioned at the posterolateral aspect of the distal femur. The proximal fibers were identified approximately 7 cm proximal to the joint line at the proximal ridge found along the diaphyseal-metaphyseal transition, while the distal fibers were found approximately 5 cm proximal to the joint line at the distal ridge at the terminal extension of the supracondylar flare.<sup>7,11</sup>

Reconstruction procedures were performed while the knee remained secured within the robot; rotation was controlled by the robot with a precision of 0.1°. After sectioning of the anterolateral structures, each knee then underwent a single-bundle ACL reconstruction. Paired knees were randomized to then undergo further reconstruction and testing according to ALL reconstruction (sequence 1) or LET reconstruction (sequence 2) as outlined in the flowchart (Figure 1). Additionally, the fixation angle for ALL reconstruction and the LET procedure was randomly assigned to either 30° or 70° of flexion for the first specimen of each pair, and the grafts in the contralateral knee were secured at the other angle.

The fixation angles of 30° and 70° for ALL reconstruction and the LET procedure were selected after a thorough review of the relevant literature.<sup>3</sup> Schon et al<sup>20</sup> reported a range of fixation angles for the ALL, from full extension to 90° of flexion, although most authors reported fixation nearer extension, and 30° was selected as 1 flexion angle to test. Spencer et al<sup>24</sup> compared ALL reconstruction and the LET procedure when fixation was performed at 70°; LET graft fixation with the knee at 30° has also been described.<sup>21</sup> To allow comparison of ALL reconstruction and LET at low and high fixation angles and to provide clinically meaningful results, fixation of the ALL and LET grafts was performed at 30° and 70° of knee flexion.

### ACL Reconstruction

Anatomic single-bundle ACL reconstruction with a bone-patellar tendon–bone allograft (AlloSource) was performed according to a previously reported technique.<sup>8,18</sup> Backup tibial fixation was performed with a screw-washer technique if there were concerns for tibial interference screw

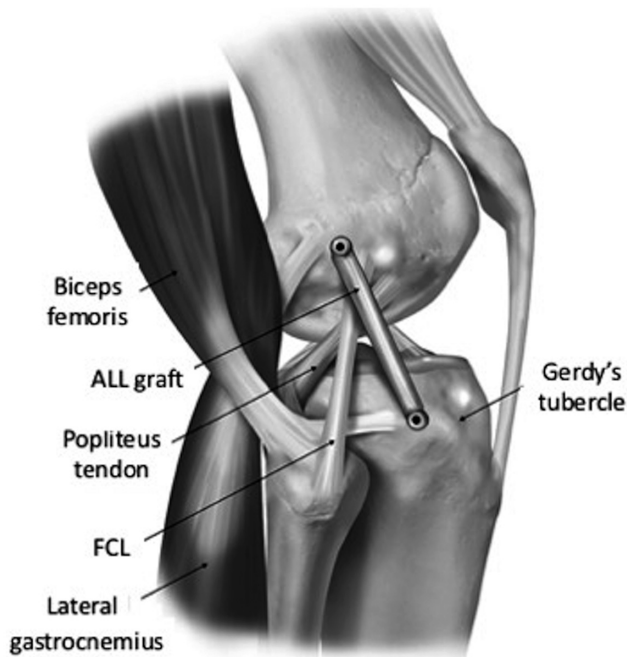


**Figure 1.** The testing states, including sectioning protocol, ACL reconstruction (all knees), and anterolateral extra-articular procedures for sequence 1 (1 knee from each pair) and sequence 2 (contralateral knee). A graft fixation angle of 30° or 70° was randomly assigned to sequences 1 and 2. ACL, anterior cruciate ligament; ALL, anterolateral ligament; ALLR, ALL reconstruction; Kaplan fibers, iliotibial band Kaplan fibers; LET, modified Lemaire lateral extra-articular tenodesis.

purchase owing to potentially compromised bone quality in the cadaveric specimens.

### ALL Reconstruction

ALL reconstruction was performed via anatomic landmarks<sup>12</sup> with the technique described by Chahla et al<sup>1</sup> (Figure 2). The femoral attachment was located proximal and posterior to the fibular collateral ligament (FCL).<sup>12</sup> A validated experimental protocol for ALL reconstruction was utilized.<sup>18,20</sup> A 6-mm semitendinosus allograft was used for ALL reconstruction (AlloSource). Each ALL graft was whipstitched 2.5 cm on each end of the graft with a No. 2 nonabsorbable suture (FiberWire; Arthrex Inc). To minimize variability associated with repeated use of the same graft or variable properties with an alternate graft, the semitendinosus graft was cut in 2. This allowed a new graft for the initial test at 20 N as well as the subsequent test at 40 N. The graft was secured in the tibia with a biointerference screw (Arthrex Inc). The ALL graft sutures were secured in the femur with the custom fixation clamp during application of 20 N of tension with the knee at 30° or 70° of flexion. The clamp was validated against



**Figure 2.** Lateral aspect of a right knee demonstrating anterolateral ligament (ALL) reconstruction of a right knee, performed with a 6-mm-diameter semitendinosus allograft. FCL, fibular collateral ligament. Modified with permission from Nitri et al.<sup>16</sup>

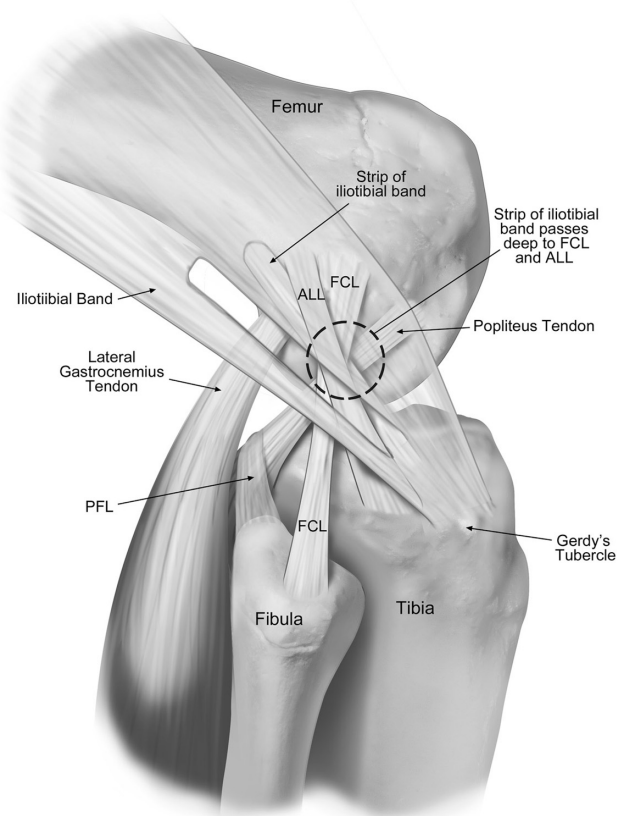
slippage and sufficient load to failure with a dynamic tensile testing machine (ElectroPuls E10000; Instron).

#### Lateral Extra-articular Tenodesis Procedure

The LET procedure was performed with the modified Lemaire technique described by Spencer et al<sup>24</sup> (Figure 3). First, an iliotibial band (ITB) autograft (1 cm wide  $\times$  8 cm long) was harvested 1 cm anterior to the posterior border of the ITB. The distal end was left attached to the Gerdy tubercle, and the proximal end was prepared with a No. 2 nonabsorbable suture in a running-locked pattern (FiberWire; Arthrex Inc). The ITB graft was then passed deep to the FCL. The femoral attachment site was positioned at the center of the distal Kaplan fibers, proximal to the FCL on the metaphyseal flare of the lateral femoral condyle. The custom fixation clamp was used to secure the sutures for the LET graft, allowing for variation of the graft fixation angle,<sup>20</sup> and the LET graft was secured with 20 N of tension with the knee at 30° or 70° of flexion.

#### Statistical Analysis

The primary aims of this study were to compare ALL reconstruction versus a LET procedure, 30° versus 70° fixation, and 20- versus 40-N fixation tension (ALL reconstruction only), both relative to the ACL reconstruction state and in comparison with the intact knee. To address these goals, 1-factor linear mixed effects models were constructed to

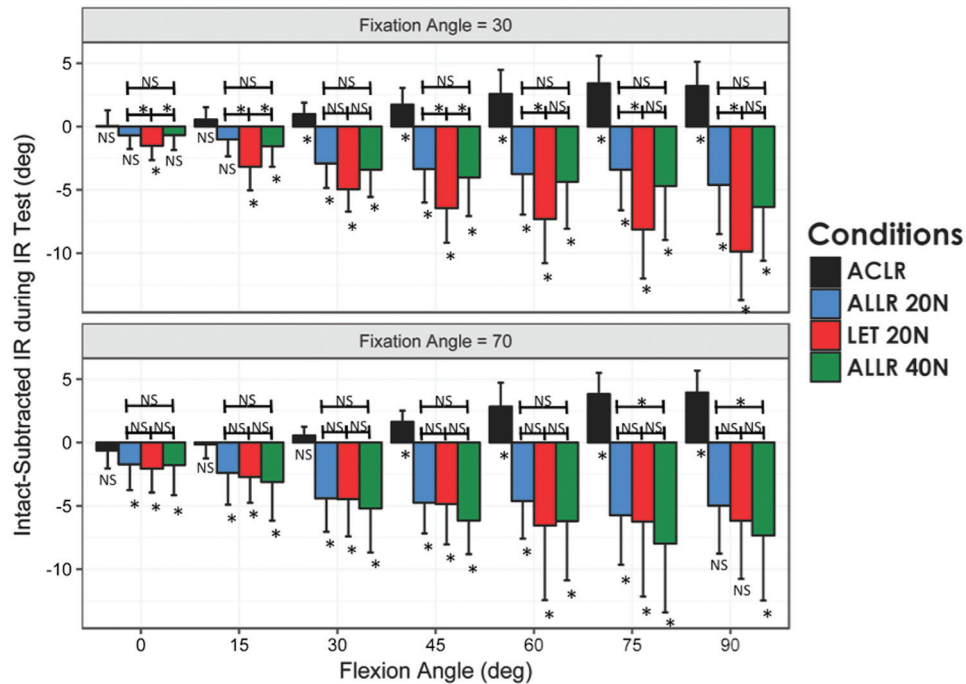


**Figure 3.** Lateral aspect of a right knee demonstrating a modified Lemaire lateral extra-articular tenodesis procedure, with the iliotibial band autograft passed deep to the fibular collateral ligament (FCL) and secured at the center of the distal Kaplan fibers. ALL, anterolateral ligament; PFL, popliteofibular ligament.

compare conditions at each combination of flexion angle and fixation angle. Random intercepts were allowed for each specimen to match the repeated measures design of the study. Tukey post hoc comparisons were performed. The covariance structure for these models was chosen with the Bayesian information criterion, and confirmation of model assumptions and fit was assessed via residual diagnostics. Additionally, paired *t* tests compared contralateral knees that underwent reconstruction fixation at 30° or 70° of flexion. A power calculation was performed with a simplification of the linear mixed effects model for comparison of means in a repeated measures context.<sup>17</sup> Based on 2-tailed *t* testing ( $\alpha = 0.05$ ), 9 matched pairs of knees were sufficient to detect an effect size of 1.07 with 80% statistical power. The statistical software R was used for all analyses (R Foundation for Statistical Computing with ggplot2, nlme, and multcomp).

#### RESULTS

Although not part of the formal statistical analysis, the intact and ACL reconstruction states were compared between paired knees to ensure that a matched pair



**Figure 4.** Mean intact-subtracted tibial internal rotation (IR) is shown for tested conditions at knee flexion angles 0° to 90°. A negative value represents overconstraint. One standard deviation is displayed above and below the bars. Comparisons with  $P < .05$  are marked with an asterisk (\*), and those with  $P > .05$  are marked “NS” for “not significant.” Findings for comparison with the intact state are indicated below the axis; additional selected comparisons are noted with a horizontal line connecting the 2 bars above the axis. ACLR, anterior cruciate ligament reconstruction with sectioned ALL and Kaplan fibers; ALLR 20N and 40N, anterolateral ligament reconstruction tensioned at 20 and 40 N; LET 20N, lateral extra-articular tenodesis tensioned at 20 N.

analysis would be appropriate, and no significant differences were found for any of the kinematic tests. Note that ACL reconstruction and subsequent testing were performed with concurrent ALL and Kaplan fiber deficiency owing to the experimental design.

Flexion angles, kinematic values, and statistical results are presented graphically because of the complexity of the study design and the number of comparisons made. Key findings are highlighted in the following sections. Paired knees from this study were utilized in an associated investigation comparing the effect of sectioning the ALL and Kaplan fibers; 1 pair was excluded from data analysis in the associated study after identification of substantial outliers for tibial internal rotation, anterior translation, and pivot-shift testing and was therefore also excluded in this investigation.

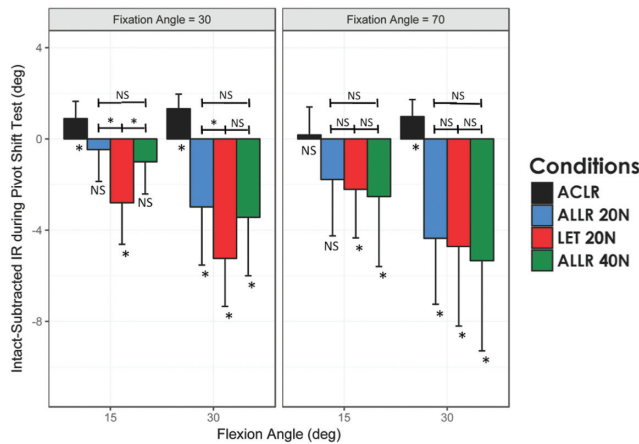
#### Tibial Internal Rotation Attributed to an Applied Internal Rotation Torque

Near full extension, ACL reconstruction was successful at restoring tibial internal rotation to values not significantly different from the intact state even when performed in knees with sectioned ALL and Kaplan fibers. However, significantly increased tibial internal rotation after ACL reconstruction remained at higher flexion angles in both groups as compared with the intact state (45°, 60°, 75°, and 90°). When compared with the intact and ACL-reconstructed

states, ALL reconstruction and the LET procedure significantly reduced internal rotation at nearly all flexion angles (Figure 4). Comparison between ALL reconstruction and the LET procedure with fixation at 30° of flexion and with 20 N of tension revealed significantly less internal rotation with LET at all tested knee flexion angles except 30° (Figure 4).

#### Tibial Internal Rotation During a Simulated Pivot Shift

ACL reconstruction in knees with sectioned ALL and Kaplan fibers did not restore tibial internal rotation during a simulated pivot shift to intact values in most cases. ALL reconstruction and the LET procedure both significantly reduced internal rotation as compared with the isolated ACL-reconstructed state. ALL reconstruction tensioned at 20 N restored the intact state for 30° and 70° fixation angles when tested at 15° knee flexion but significantly reduced internal rotation to less than the intact state at 30° of knee flexion. LET led to significantly decreased internal rotation for the 30° and 70° fixation angles as compared with the intact and isolated ACL-reconstructed states at 15° and 30° (Figure 5). In a comparison between ALL and LET graft fixation at 30° of knee flexion (20-N graft tension), significantly decreased internal rotation was observed for LET. However, no significant differences were found between the techniques with graft fixation at 70° (Figure 5).



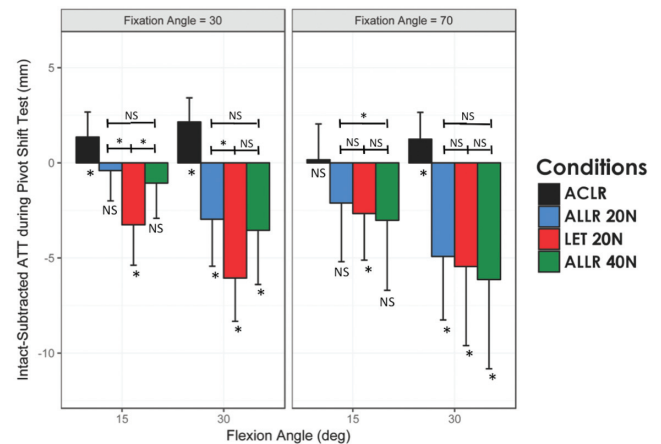
**Figure 5.** Mean intact-subtracted tibial internal rotation (IR) is shown for a simulated pivot shift for tested conditions at knee flexion angles of 15° and 30°. One standard deviation is displayed above and below the bars. Comparisons with  $P < .05$  are marked with an asterisk (\*), and those with  $P > .05$  are marked “NS” for “not significant.” Findings for comparison with the intact state are indicated below the axis; additional selected comparisons are noted with a horizontal line connecting the 2 bars above the axis. ACLR, anterior cruciate ligament reconstruction; ALLR 20N and 40N, anterolateral ligament reconstruction tensioned at 20 and 40 N; LET 20N, lateral extra-articular tenodesis tensioned at 20 N.

### Anterior Tibial Translation During a Simulated Pivot-Shift Test

Isolated ACL reconstruction in knees with sectioned ALL and Kaplan fibers did not restore anterior tibial translation during a simulated pivot shift to intact values in most cases. ALL reconstruction and the LET procedure significantly reduced anterior tibial translation as compared with the ACL-reconstructed state alone. ALL reconstruction tensioned at 20 N and 40 N restored the intact state for anterior tibial translation during a simulated pivot shift for 30° and 70° graft fixation angles when tested at 15°, although it significantly decreased anterior tibial translation when compared with the intact state with testing at 30°. Compared with the intact state, the LET procedure led to significantly decreased anterior tibial translation with testing at 15° and 30° for 30° and 70° graft fixation angles. In comparison between ALL and LET graft fixation at 30° (20-N graft tension), a significantly greater reduction in internal rotation was observed for the LET procedure with testing at 15° and 30°. However, there was no significant difference between the techniques with graft fixation at 70° (Figure 6).

### Anterior Tibial Translation Based on an Applied Anterior Load

Isolated ACL reconstruction did not restore anterior tibial translation during an applied anterior tibial load to the



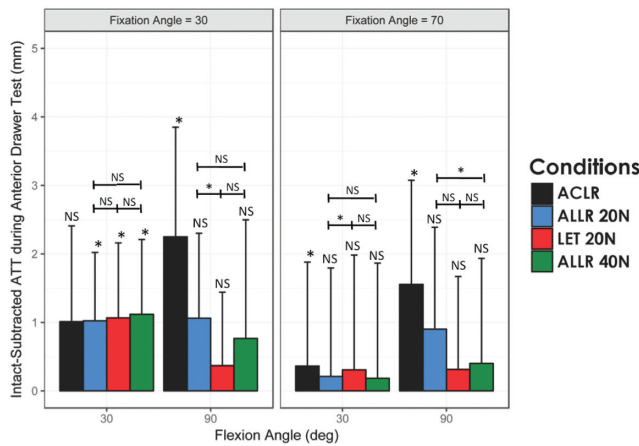
**Figure 6.** Mean intact-subtracted anterior tibial translation (ATT) is shown during a simulated pivot shift for tested conditions at knee flexion angles of 15° and 30°. One standard deviation is displayed above and below the bars. Comparisons with  $P < .05$  are marked with an asterisk (\*), and those with  $P > .05$  are marked “NS” for “not significant.” Findings for comparison with the intact state are indicated below the axis; additional selected comparisons are noted with a horizontal line connecting the 2 bars above the axis. ACLR, anterior cruciate ligament reconstruction; ALLR 20N and 40N, anterolateral ligament reconstruction tensioned at 20 and 40 N; LET 20N, lateral extra-articular tenodesis tensioned at 20 N.

intact state in most testing states. Furthermore, ALL reconstruction and LET both restored anterior tibial translation to the intact state with testing at 30° and 90°, with the exception of testing at 30° with a 30° fixation angle for the LET procedure and ALL reconstruction (at 20 N and 40 N of graft tension). Anterior tibial translation during an applied anterior tibial load was not reduced to levels less than the intact state with ALL reconstruction or the LET procedure (Figure 7).

### Selected Clinically Relevant Comparisons

**ALL Reconstruction Graft Tension, 20 or 40 N.** The influence of ALL graft fixation tension (20 N, 40 N) was investigated during each of the 4 testing scenarios. It was found that graft tension had a limited role for ALL reconstruction kinematics, except for internal rotation testing at high flexion angles (75° and 90°) with graft fixation at 70° (Figure 4). There was no significant difference in the kinematic properties for internal rotation during simulated pivot-shift testing with any scenario (Figure 5). Anterior tibial translation during simulated pivot-shift testing revealed no significant differences with ALL graft tensioning at 40 N versus 20 N, except with testing at 15° and graft fixation at 70°, which revealed significantly greater reduction in anterior tibial translation for graft tensioning at 40 N (Figure 6). Similarly, isolated anterior tibial translation revealed no significant differences with ALL graft tensioning at 40 N versus





**Figure 7.** Mean intact-subtracted anterior tibial translation (ATT) is shown for tested conditions at knee flexion angles of 30° and 90°. One standard deviation is displayed above the bars. Comparisons with  $P < .05$  are marked with an asterisk (\*), and those with  $P > .05$  are marked “NS” for “not significant.” Findings for comparison to the intact state are indicated above the axis; additional selected comparisons are noted with a horizontal line connecting the 2 bars above the axis. ACLR, anterior cruciate ligament reconstruction; ALLR 20N and 40N, anterolateral ligament reconstruction tensioned at 20 and 40 N; LET 20N, lateral extra-articular tenodesis tensioned at 20 N.

20 N, except with testing at 90° and graft fixation at 70°, which revealed significantly greater reduction in anterior tibial translation for graft tensioning at 40 N (Figure 7).

**LET Procedure Graft Fixation, 30° or 70°.** The influence of graft fixation angle for the LET procedure was investigated during each of the 4 testing scenarios. There was no difference in tibial internal rotation during an applied internal rotation torque in comparison of LET graft fixation at 30° or 70° except at 90°, where nearly 4° of additional reduction in internal rotation was observed with graft fixation at 30°; although no other statistical differences were observed with these fixation angles, visual comparison of the plots supports graft fixation at 70° rather than 30° (Figure 4). In addition, no significant differences were found for either graft fixation angle for a simulated pivot shift (internal rotation and anterior tibial translation) or anterior drawer testing (Figures 5-7).

**Selection of Optimal Anterolateral Extra-articular Procedure.** Although few statistical differences were identified during comparison of either ALL graft tension or LET fixation angle, we believe that it was important to compare the most clinically relevant techniques tested. Therefore, ALL reconstruction graft fixation at 20 N and 30° was compared with LET graft fixation at 20 N and 70°. No significant differences were identified on internal rotation testing, simulated pivot-shift testing, or anterior drawer testing between these conditions (Figures 4-7).

## DISCUSSION

The most important findings of this study are that residual laxity was identified after isolated ACL reconstruction in the setting of ALL and Kaplan fiber deficiency and that anatomic ALL reconstruction and the modified Lemaire LET procedure in conjunction with ACL reconstruction resulted in significantly reduced tibiofemoral motion versus the intact state on isolated tibial internal rotation and pivot-shift testing (tibial internal rotation and anterior translation) at most knee flexion angles. Greater reductions in isolated internal rotation and pivot shift were found with the LET procedure than with ALL reconstruction. No consistent significant differences were observed between graft tension for ALL reconstruction (ie, 20 vs 40 N) or graft fixation angles for the LET procedure (ie, 30° vs 70°). When combined with ACL reconstruction, ALL reconstruction and the LET procedure restored anterior tibial translation to intact values at most testing states for knees with deficient ALL and Kaplan fibers. Without substantial differences between the kinematic influences of ALL reconstruction and the LET procedure, this study was unable to select 1 procedure as the optimal technique to address anterolateral rotational laxity in patients with combined ACL tears and anterolateral capsular deficiency.

Many investigators have recommended augmenting ACL reconstruction with anterolateral knee extra-articular reconstruction in select cases.<sup>15</sup> The present study was undertaken to attempt to answer clinically relevant issues regarding the indications for augmenting ACL reconstruction with either ALL reconstruction or a LET procedure in the setting of deficient anterolateral structures. The ALL and Kaplan fibers were sectioned to replicate a clinical setting where there is a concomitant anterolateral knee injury with an ACL tear. Terry et al<sup>27</sup> reported that the anterolateral structures were commonly injured in knees with ACL tears and may result in a high-grade pivot shift. The present study revealed that isolated ACL reconstruction did not restore tibial internal rotation and anterior translation to intact values in the setting of ALL and Kaplan fiber deficiency, supporting consideration for anterolateral extra-articular reconstruction with concurrent ACL reconstruction in select patients. However, overconstraint on isolated internal rotation and pivot-shift testing was identified, and this must be reconciled with clinical results to allow appropriate patient selection.

In this context, *overconstraint* is generally meant to refer to reduced tibial internal rotation and anterior translation as compared with the intact state, and it has long been a concern of anterolateral knee extra-articular reconstruction procedures. This is relevant because of a potential role in early failure of LET procedures based on nonisometric reconstructions and subsequent graft elongation.<sup>9</sup> Theoretical concerns of accelerated degenerative changes have been suggested,<sup>21</sup> although a recent systematic review<sup>4</sup> revealed no clinical evidence to support this and there are no known biomechanical studies revealing increased tibiofemoral contact pressure after combined ACL and anterolateral extra-articular reconstruction procedures.

Several biomechanical studies have been performed to assess the kinematics of such procedures, often with conflicting results. Schon et al<sup>20</sup> reported that anatomic ALL reconstruction resulted in significant overconstraint with an ALL graft tensioned at 88 N, regardless of the knee flexion angle at fixation. There was concern that increased graft tension may have led to overconstraint, so this was evaluated in the present study, which revealed that decreased ALL graft tension (20 N and 40 N vs 88 N) also significantly overconstrained the knee.

Inderhaug et al<sup>10</sup> reported that isolated ACL reconstruction resulted in residual tibial translational and rotational laxity in the setting of combined ACL and anterolateral structure deficiency, and the influence of ALL reconstruction and LET procedures was evaluated. They reported significant overconstraint with the Lemaire LET passed superficial to the FCL at several flexion angles when tensioned at 20 N and 40 N, although this was not observed when the graft was passed deep to the FCL. However, in contrast to our study, their study revealed that ALL reconstruction was associated with residual laxity rather than overconstraint. Anatomic graft fixation points were similar, although graft selection differed (gracilis vs semitendinosus tendon), which may explain inconsistent findings when the ALL reconstruction results from Inderhaug et al are compared with those in the present study. However, it is unlikely that, though not directly measured, the force per unit area (ie, stress) experienced by the grafts approached the tensile strength of the grafts. Varying techniques for positioning the knee during graft tensioning and fixation may offer an alternative explanation for somewhat inconsistent findings among various biomechanical laboratories. The present study was performed according to previously described techniques with an established testing protocol; the neutral position was defined as the position with zero or minimal forces acting on the knee in the intact state and was determined before sectioning at all flexion angles tested.

Samuelson et al<sup>19</sup> also evaluated the ability of isolated ACL reconstruction to restore normal internal rotation stability to knees with combined ACL and anterolateral capsular deficiency. They reported restoration of anterior translation with isolated ACL reconstruction, but internal rotation was not restored to normal. However, the addition of a LET procedure to ACL reconstruction led to overconstraint in most scenarios with 0 N and 22 N of LET graft tension (secured in neutral rotation). These findings of incomplete restoration of rotational control in combined lesions with isolated ACL reconstruction, as well as reduced internal rotation as compared with the intact state after the addition of a LET procedure, are consistent with the findings of the present study.

In a recent systematic review of the biomechanical results, Slette et al<sup>21</sup> reported that isolated LET procedures in the ACL-deficient knee overconstrained the knee and did not restore anterior tibial translation stability to the intact state. Spencer et al<sup>24</sup> compared a LET procedure and ALL reconstruction in an ACL-deficient knee model and reported improved kinematics with the former but not the latter (although the ALL graft was secured at the lateral epicondyle).

However, it is important to evaluate these procedures in the appropriate context that best replicates the clinical scenario. Engebretsen et al<sup>5</sup> evaluated the role of a LET procedure in the setting of ACL reconstruction; ACL graft forces were decreased by a mean 43% when a subsequent LET procedure was performed, suggesting a possible role for protection of an ACLR graft. The present study revealed that ALL reconstruction and the modified Lemaire procedure may play an important role in restoring anterior tibial translation to intact states with concurrent ACL reconstruction in the setting of combined ACL and anterolateral structure deficiency, consistent with a potential ACL graft-protective role in this injury pattern.

Anterolateral extra-articular procedures combined with ACL reconstruction have been supported in an effort to address the pivot shift (usually described as occurring at low flexion angles) and to reduce graft failure rate.<sup>15</sup> The present study revealed that LET produced overconstraint with fixation at 30° of knee flexion, where it may have more of an effect on the pivot shift, as well as at 70°, where the anterolateral structures had a greater influence on rotational laxity. A significantly greater reduction in tibial internal rotation was demonstrated with the LET procedure than ALL reconstruction, most notably with graft fixation at 30°. However, no consistent significant differences were observed between the LET procedure and ALL reconstruction with graft fixation at 70°. Although infrequent significant differences were found between LET graft fixation at 30° and 70°, careful review of the figures and comparison with ALL reconstruction support LET graft fixation at 70° if this technique is selected. The indications for these procedures should therefore be considered carefully and be utilized in select cases.

As reviewed, most biomechanical studies revealed excessive tibial internal rotation after isolated ACL reconstruction in the setting of anterolateral structure deficiency. However, this has not been replicated with in vivo studies. Tashman et al<sup>25</sup> reported greater tibial external rotation after ACL reconstruction for isolated lesions, rather than excessive internal rotation, as may be expected on the basis of biomechanical studies. However, biomechanical studies of combined lesions are unlikely to represent all clinical scenarios and may overestimate the laxity that occurs with isolated ACL injuries. This underscores the importance of accurately diagnosing combined injuries that occur clinically and defining appropriate indications for combined intra- and extra-articular reconstruction.

There is a relative paucity of clinical studies on combined ACL reconstruction with a LET procedure or ALL reconstruction, although some studies have recently emerged. In a systematic review, Hewison et al<sup>9</sup> reported a decrease in the pivot-shift grade but no difference in IKDC scores. Song et al<sup>22</sup> also performed a systematic review of studies in which patients underwent combined ACL reconstruction and LET; the combined procedure effectively eliminated a high-grade pivot shift, although no differences in IKDC scores were observed as compared with isolated ACL reconstruction. Sonnery-Cottet et al<sup>23</sup> reported the results of a level II study revealing a lower ACL graft failure rate with the addition of ALL



reconstruction. The lower incidence of ACL graft failure may be explained by a shielding effect of the anterolateral extra-articular procedure on the ACL graft. However, the duration of follow-up in this study does not allow evaluation of a possible relationship between this procedure and the development of osteoarthritis attributed to potential overconstraint with ALL reconstruction.

With extrapolation of our findings to the clinical setting, we suggest that the indications for concurrent ALL or LET reconstruction with ACL reconstruction be selected primarily for those patients with biological or physiologic compromise (eg, ACL reconstruction with allograft, revision ACL reconstructions, patients with genu recurvatum, or patients with increased sagittal plane tibial slope) because the overconstraint may protect the ACL graft. Further consideration can be given to patients at high risk for ACL re-tear because of their participation in high-level cutting and pivoting sports. However, before these procedures are performed in all patients with an ACL tear, further study is needed to determine whether overconstraint causes the anterolateral extra-articular reconstruction grafts to elongate or if overconstraint may contribute to accelerated degenerative changes and subsequent early osteoarthritis.

There were limitations associated with this study. This was a biomechanical time-zero study with surgically created defects that may not fully reflect laxity associated with acute injuries or soft tissue attenuation that may occur in chronic injuries. In addition, the application of multiple testing conditions at each flexion angle and graft fixation tension may result in laxity of the surrounding soft tissue structures; however, this effect was limited by randomizing the order of graft fixation angles and procedures during testing, and the effect of dependent variables was limited by using commercially prepared allografts for every reconstruction. The influence of biomechanical laxity after ACL reconstruction versus overconstraint after lateral extra-articular procedures must be carefully considered with the potential clinical implications of both scenarios. Combined with the biomechanical findings reported in this study, in vivo testing (eg, with biplane fluoroscopy) and longer-term clinical follow-up are necessary to select appropriate indications and monitor complications, such as the potential accelerated degeneration attributed to overconstraint that has been demonstrated biomechanically with anterolateral extra-articular reconstruction procedures.

## CONCLUSION

Residual laxity was identified after isolated ACL reconstruction in the setting of ALL and Kaplan fiber deficiency, and combination of ACL reconstruction in this setting with either ALL reconstruction or the modified Lemaire LET procedure resulted in significant reductions in tibiofemoral motion at most knee flexion angles, although overconstraint was also identified. ALL reconstruction and LET restored anterior tibial translation to intact values with most testing states.

## REFERENCES

1. Chahla J, Menge TJ, Mitchell JJ, Dean CS, LaPrade RF. Anterolateral ligament reconstruction technique: an anatomic-based approach. *Arthrosc Tech*. 2016;5(3):e453-e457.
2. DePhillipo NN, Cinque ME, Chahla J, Geeslin AG, Engebretsen L, LaPrade RF. Incidence and detection of meniscal ramp lesions on magnetic resonance imaging in patients with anterior cruciate ligament reconstruction. *Am J Sports Med*. 2017;45(10):2233-2237.
3. DePhillipo NN, Cinque ME, Chahla J, Geeslin AG, LaPrade RF. Anterolateral ligament reconstruction techniques, biomechanics, and clinical outcomes: a systematic review. *Arthroscopy*. 2017;33(8):1575-1583.
4. Devitt BM, Bouguennec N, Barford KW, Porter T, Webster KE, Feller JA. Combined anterior cruciate ligament reconstruction and lateral extra-articular tenodesis does not result in an increased rate of osteoarthritis: a systematic review and best evidence synthesis. *Knee Surg Sports Traumatol Arthrosc*. 2017;25(4):1149-1160.
5. Engebretsen L, Lew WD, Lewis JL, Hunter RE. The effect of an iliotibial tenodesis on intraarticular graft forces and knee joint motion. *Am J Sports Med*. 1990;18(2):169-176.
6. Engebretsen L, Wijdicks CA, Anderson CJ, Westerhaus B, LaPrade RF. Evaluation of a simulated pivot shift test: a biomechanical study. *Knee Surg Sports Traumatol Arthrosc*. 2012;20(4):698-702.
7. Godin JA, Chahla J, Moatshe G, et al. A comprehensive reanalysis of the distal iliotibial band: quantitative anatomy, radiographic markers, and biomechanical properties. *Am J Sports Med*. 2017;45(11):2595-2603.
8. Goldsmith MT, Jansson KS, Smith SD, Engebretsen L, LaPrade RF, Wijdicks CA. Biomechanical comparison of anatomic single- and double-bundle anterior cruciate ligament reconstructions: an in vitro study. *Am J Sports Med*. 2013;41(7):1595-1604.
9. Hewison CE, Tran MN, Kaniki N, Remtulla A, Bryant D, Getgood AM. Lateral extra-articular tenodesis reduces rotational laxity when combined with anterior cruciate ligament reconstruction: a systematic review of the literature. *Arthroscopy*. 2015;31(10):2022-2034.
10. Inderhaug E, Stephen JM, Williams A, Amis AA. Biomechanical comparison of anterolateral procedures combined with anterior cruciate ligament reconstruction. *Am J Sports Med*. 2017;45(2):347-354.
11. Kaplan EB. The iliotibial tract; clinical and morphological significance. *J Bone Joint Surg Am*. 1958;40(4):817-832.
12. Kennedy MI, Claes S, Fuso FA, et al. The anterolateral ligament: an anatomic, radiographic, and biomechanical analysis. *Am J Sports Med*. 2015;43(7):1606-1615.
13. LaPrade RF, Matheny LM, Moulton SG, James EW, Dean CS. Posterior meniscal root repairs: outcomes of an anatomic transtibial pull-out technique. *Am J Sports Med*. 2017;45(4):884-891.
14. Morgan JA, Dahm D, Levy B, Stuart MJ, Group MS. Femoral tunnel malposition in ACL revision reconstruction. *J Knee Surg*. 2012;25(5):361-368.
15. Musahl V, Getgood A, Neyret P, et al. Contributions of the anterolateral complex and the anterolateral ligament to rotatory knee stability in the setting of ACL injury: a roundtable discussion. *Knee Surg Sports Traumatol Arthrosc*. 2017;25(4):997-1008.
16. Nitri M, Rasmussen MT, Williams BT, et al. An in vitro robotic assessment of the anterolateral ligament, part 2: anterolateral ligament reconstruction combined with anterior cruciate ligament reconstruction. *Am J Sports Med*. 2016;44(3):593-601.
17. Pinheiro JC, Bates DM. Linear mixed-effects models: basic concepts and examples. In: *Mixed-Effects Models in S and S-Plus*. New York, NY: Springer-Verlag; 2000:3-56.
18. Rasmussen MT, Nitri M, Williams BT, et al. An in vitro robotic assessment of the anterolateral ligament, part 1: secondary role of the anterolateral ligament in the setting of an anterior cruciate ligament injury. *Am J Sports Med*. 2016;44(3):585-592.
19. Samuelson M, Draganich LF, Zhou X, Kruminis P, Reider B. The effects of knee reconstruction on combined anterior cruciate ligament and anterolateral capsular deficiencies. *Am J Sports Med*. 1996;24(4):492-497.

20. Schon JM, Moatshe G, Brady AW, et al. Anatomic anterolateral ligament reconstruction of the knee leads to overconstraint at any fixation angle. *Am J Sports Med.* 2016;44(10):2546-2556.
21. Slette EL, Mikula JD, Schon JM, et al. Biomechanical results of lateral extra-articular tenodesis procedures of the knee: a systematic review. *Arthroscopy.* 2016;32(12):2592-2611.
22. Song GY, Hong L, Zhang H, Zhang J, Li Y, Feng H. Clinical outcomes of combined lateral extra-articular tenodesis and intra-articular anterior cruciate ligament reconstruction in addressing high-grade pivot-shift phenomenon. *Arthroscopy.* 2016;32(5):898-905.
23. Sonnery-Cottet B, Saithna A, Cavalier M, et al. Anterolateral ligament reconstruction is associated with significantly reduced ACL graft rupture rates at a minimum follow-up of 2 years: a prospective comparative study of 502 patients from the SANTI Study Group. *Am J Sports Med.* 2017;45(7):1547-1557.
24. Spencer L, Burkhart TA, Tran MN, et al. Biomechanical analysis of simulated clinical testing and reconstruction of the anterolateral ligament of the knee. *Am J Sports Med.* 2015;43(9):2189-2197.
25. Tashman S, Kolowich P, Collon D, Anderson K, Anderst W. Dynamic function of the ACL-reconstructed knee during running. *Clin Orthop Relat Res.* 2007;454:66-73.
26. Tavlo M, Eljaja S, Jensen JT, Siersma VD, Krogsgaard MR. The role of the anterolateral ligament in ACL insufficient and reconstructed knees on rotatory stability: a biomechanical study on human cadavers. *Scand J Med Sci Sports.* 2016;26(8):960-966.
27. Terry GC, Norwood LA, Hughston JC, Caldwell KM. How iliotibial tract injuries of the knee combine with acute anterior cruciate ligament tears to influence abnormal anterior tibial displacement. *Am J Sports Med.* 1993;21(1):55-60.