Current Concepts Review

Meniscal Repair

Reconsidering Indications, Techniques, and Biologic Augmentation

Jarret M. Woodmass, MD, FRCS(C), Robert F. LaPrade, MD, PhD, Nicholas A. Sgaglione, MD, Norimasa Nakamura, MD, PhD, and Aaron J. Krych, MD

Investigation performed at the Department of Orthopedic Surgery and Sports Medicine, Mayo Clinic, Rochester, Minnesota

- The medial and lateral menisci have an important role in load-bearing and shock absorption and contribute to knee stability, with meniscectomy resulting in increased anterior translation of the femoral condyle on the tibia.
- Meniscal repair provides improved long-term outcomes, better clinical outcome scores, and less severe degenerative changes seen radiographically compared with partial meniscectomy.
- Given the potential long-term sequelae of meniscal pathology, patients with symptomatic meniscal tears warrant a thorough assessment with surgical consultation to determine the optimal treatment strategy.
- Advancements in surgical techniques and biologic augmentation have expanded the indications for meniscal repair to include tear patterns previously considered irreparable.

The meniscus was once considered a functionless remnant of muscle[1] that should be removed in its entirety at any sign of abnormality[2]. Its role in load distribution[3], knee stability[4], and arthritis prevention[5] has since been well established. The medial and lateral menisci are now considered vital structures in the healthy knee[6,7]. Advancements in surgical techniques and biologic augmentation methods have expanded the indications for meniscal repair, with documented healing in tears previously deemed unsalvageable[8-11]. In this article, we review the anatomy and function of the meniscus, evaluate the implications of meniscectomy, and assess the techniques of, and outcomes following, meniscal repair.

Anatomy and Biomechanics of the Meniscus

The medial and lateral menisci are unique cartilaginous structures located between the femoral condyle and the tibial plateau that contribute to knee stability[4] and load distribution[12] (Fig. 1). The medial meniscus is a C-shaped structure measuring approximately 45.7 mm in length and 27.4 mm in width. The lateral meniscus is U-shaped, with dimensions of 35.7 mm in length and 29.3 mm in width[13], and demonstrates greater variability in its shape, size, and mobility[13]. The menisci are stabilized by their anterior and posterior roots, the anterior intermeniscal (transverse) ligament, the medial collateral ligament, the meniscofemoral ligaments, and the coronary ligaments[14].

The blood supply to the meniscus is provided through the perimeniscal capillary plexus originating in the capsular and synovial tissues (Fig. 2)[15]. The vascularized peripheral rim of the meniscus is defined as the vascular zone, while the more central zone, devoid of microvasculature, is defined as the avascular zone[16]. The collagen-fiber configuration of the meniscus is ideal for transferring compressive loads into circumferential "hoop" stresses (Fig. 3)[17].

The menisci have an important role in load-bearing and shock absorption[12]. Meniscectomy decreases the contact area by 75%, increases the peak local contact stresses by 235%, and allows for increased anterior translation of the femoral condyle on the tibia[4]. This combination of increased shear forces and compressive loads is thought to result in arthritic changes[18].

Disclosure: No external funding was received for this work. On the **Disclosure of Potential Conflicts of Interest** forms, *which are provided with the online version of the article,* one or more of the authors checked "yes" to indicate that the author had a relevant financial relationship in the biomedical arena outside the submitted work (http://links.lww.com/JBJS/E270).

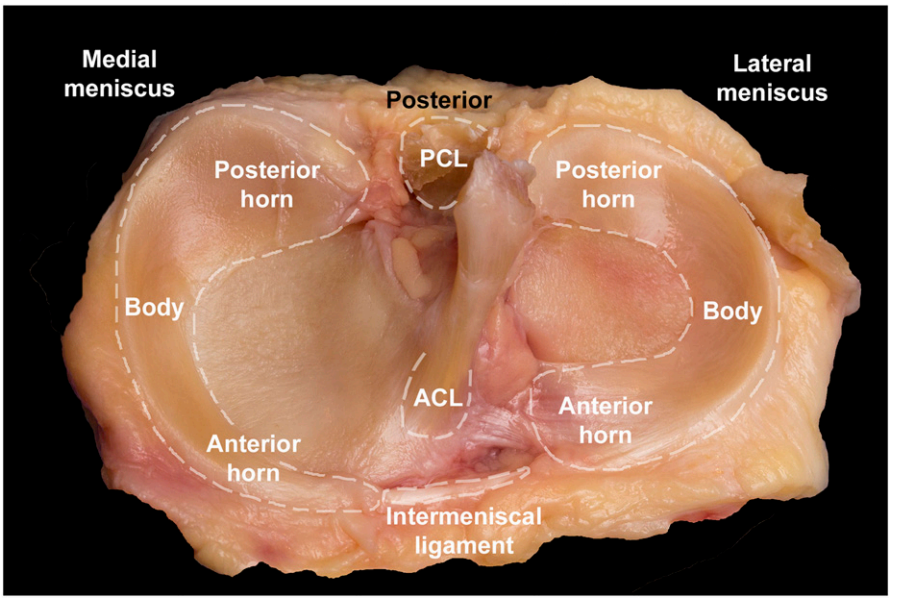

Fig. 1
A cadaveric image of the tibial plateau, menisci, and cruciate ligaments. ACL = anterior cruciate ligament, and PCL = posterior cruciate ligament. (By permission of Mayo Foundation for Medical Education and Research. © Mayo 2017. All rights reserved.)

Biochemistry and Biomarkers

The meniscus is a relatively acellular structure with predominantly fibroblast-like cells in the vascular zone and chondrocyte-like cells in the avascular zone[19]. The biomarker composition within the synovial fluid differs substantially in normal knees compared with those with traumatic or degenerative meniscal tears[20,21]. Furthermore, these conditions persist months after injury, suggesting a chronic inflammatory state resulting in meniscal degeneration and the initiation of osteoarthritis[22,23]. Degradative enzymes, including metalloproteinases and aggrecanases, contribute to meniscal degeneration through proteoglycan and collagen degradation[24]. Biologic augmentation strategies are designed to promote a healing environment around the relatively acellular meniscus and disrupt the degradative cascade.

Repair Indications

While biomechanical data suggest that repair should always be performed, laboratory testing does not consider the implications of persistent pain, decreased functional scores, poor healing response, and the increased reoperation rate that can result from a failed meniscal repair[25]. As a result, factors associated with successful meniscal healing continue to drive the surgical decision-making process and indications for repair. Furthermore, it should be recognized that *healing* is also not well defined. The resolution of clinical symptoms (clinically healed), magnetic resonance imaging (MRI) evidence of continuity (healed on imaging), and second-look arthroscopy (visually healed) do not always correlate[26]. A thorough understanding of the many factors affecting a patient's expected clinical outcome is necessary to determine the optimal treatment for each individual patient.

Vascular Versus Avascular

The meniscus has limited healing capacity, most notably in its central two-thirds, which is avascular and aneural[16]. In contrast, the outer third of the meniscus contains the perimeniscal capillary plexus, thought to promote healing[15]. This has been validated by an animal model in which peripheral-third meniscal tears healed in approximately 10 weeks, similar to other soft-tissue injuries[27]. Clinically, multiple studies



Fig. 2
Microvasculature of the medial meniscus, following vascular perfusion with India ink and tissue clearing using a modified Spalteholz technique. The perimeniscal capillary plexus (PCP) can be seen penetrating the peripheral border of the medial meniscus. F = femur, and T = tibia. (Reproduced from: Arnoczky SP, Warren RF. Microvasculature of the human meniscus. Am J Sports Med. 1982 Mar-Apr;10(2):90-5. SAGE Publications.)

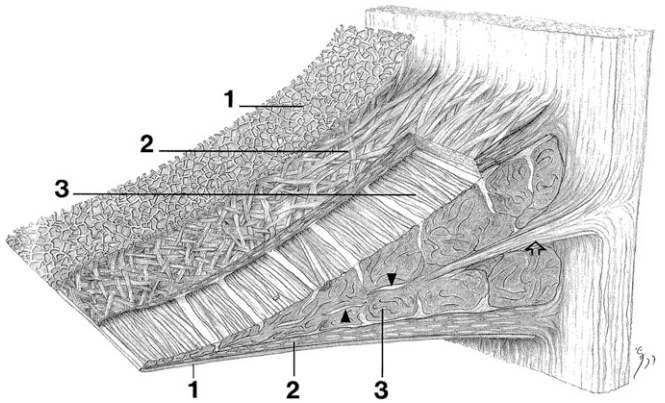

Fig. 3

Schematic diagram demonstrating the collagen fiber ultrastructure and orientation within the meniscus: the superficial network (1), the lamellar layer (2), the central, main layer (3), radial interwoven fibers (arrowheads), and loose connective tissue (arrow). (Reproduced, with permission of Springer, from: Petersen W, Tillmann B. Collagenous fibril texture of the human knee joint menisci. Anat Embryol [Berl]. 1998 Apr;197[4]:317-24. © Springer-Verlag Berlin Heidelberg 1998.)

have demonstrated excellent healing of peripheral tears[28-30], and the distance of the tear from the meniscocapsular junction (0 to 2 mm) has been identified as the greatest predictor for healing[26]. However, repair of tears in the avascular zone can also have clinical benefit. Noyes and Barber-Westin[31,32] reported that 75% of patients <20 years of age and 87% of those ≥40 years of age were asymptomatic with respect to tibiofemoral joint symptoms after avascular zone repairs at a mean postoperative follow-up of 51 months and 34 months, respectively.

Pattern and Location

Vertical longitudinal tears are more likely to heal than are other tear patterns[33,34]. Radial, oblique, and horizontal cleavage tears, by definition, involve the avascular zone of the meniscus[35]. Tear length also affects the meniscal healing rate[36]. If the tear extends from the anterior horn to the posterior horn, allowing the meniscal fragment to flip on itself (a bucket-handle tear), the rate of healing is reduced[36]. Anterior and posterior horn root avulsion injuries are beyond the scope of this article and have been previously described by LaPrade et al.[37,38].

Isolated Versus Combined Ligament Reconstruction

Cannon and Vittori compared the healing rate of menisci repaired in conjunction with an anterior cruciate ligament (ACL) reconstruction (68 patients, group 1) with that of menisci undergoing isolated meniscal repair (22 patients, group 2)[36]. The overall healing rate was 82%. However, healing was demonstrated in 91% of the patients in group 1 compared with 50% in group 2. This finding has been verified by other authors[31,39] and is thought to result from the release of growth factors and pluripotent cells after bone-tunnel drilling that results in biologic augmentation at the repair site[9]. An alternative theory is that the meniscus is otherwise normal but tears as a result of the tibiofemoral subluxation in these traumatic cases, whereas menisci that tear in isolation are inherently susceptible[33,36].

Traumatic Versus Degenerative Tears

Traumatic tears occur as a result of supraphysiologic forces applied to the knee, often resulting in concomitant ligamentous disruption. In contrast, degenerative tears result from repetitive physiologic forces leading to gradual wear of the meniscus[40]. Degenerative tears are commonly horizontal cleavage or complex tears accompanied by osteoarthritic changes of the tibiofemoral joint (chondral changes of Outerbridge II or greater), as was noted in >85% of 44 knees in a previous study, compared with only 12% of knees with radial tears and 0% with vertical longitudinal tears[40,41]. Nonoperative therapy focusing on nonsteroidal anti-inflammatory drugs and physical therapy has been shown to provide pain relief and improve mechanical function of the knee joint for degenerative meniscal tears[40,42].

TABLE I Grades of Recommendation

Clinical Care Recommendation	Grade*
Degenerative meniscal tears identified in patients with osteoarthritis should be treated nonoperatively.	A
Meniscal repair provides improved long-term outcomes, better clinical outcome scores, and less severe degenerative changes seen radiographically than does partial meniscectomy.	B
Inside-out and all-inside meniscal repair techniques demonstrate no difference in failure rates, functional outcome scores, or complications.	C
Biologic augmentation strategies improve the rate of meniscal healing.	C
Weight-bearing and terminal flexion should be limited following meniscal repair.	I

*Grade A indicates good evidence (Level-I studies with consistent findings) for or against recommending intervention; Grade B, fair evidence (Level-II or III studies with consistent findings) for or against recommending intervention; Grade C, conflicting or poor-quality evidence (Level-IV or V studies with consistent findings) for or against recommending intervention; and Grade I, insufficient or conflicting evidence not allowing a recommendation for or against intervention[108].

Nonoperative Treatment

The role of nonoperative management has been studied extensively for degenerative meniscal tears. Nonoperative treatment is a cost-effective means of obtaining equivalent functional outcomes at 1 year while avoiding the potential risks of surgery (Table I)[43,44]. However, the role of nonoperative management for simple tear patterns in younger patients is less clear. Over one-third of patients (mean age of 43 years) investigated for a meniscal tear had an asymptomatic tear on the contralateral side[45]. Furthermore, >95% of small peripheral tears left in situ at the time of ACL reconstruction did not require further surgical intervention[39]. Thus, it is clear that not all meniscal tears require surgical intervention. However, given the potential long-term sequelae of meniscal pathology, patients with symptomatic meniscal tears warrant a thorough assessment with surgical consultation.

Surgical Intervention

A healed meniscal repair results in improved long-term functional outcome scores when compared with partial meniscectomy[25,46]. Furthermore, meniscal repair has been shown to be protective against the development and progression of arthritis, which correlates closely with declining functional outcomes scores[47]. In order to maximize healing potential, we follow the "ABCs" of meniscal repair: anatomic reduction, biologic augmentation, and circumferential compression across the tear site. Considerable technologic advances have occurred over the past 2 decades. Open repairs have been largely replaced by arthroscopic techniques, which can generally be classified as "outside-in," "inside-out," or "all-inside" repairs. While the outside-in technique is a useful option for repairing the anterior horn or midbody of the meniscus, it is difficult to obtain a perpendicular trajectory in the posterior third, favoring either an inside-out or all-inside repair[48]. The inside-out technique remains the gold-standard technique for meniscal repair and is especially useful for repair of large tears (>3 cm) or bucket-handle tears for which multiple sutures are required[49]. In an effort to reduce the risk of neurologic injury and avoid the additional incision, all-inside techniques have evolved. The authors of a recent systematic review compared the clinical outcomes of inside-out and all-inside meniscal repair techniques and found equal healing rates, functional outcomes, and complications[29]. Currently, both techniques are commonly utilized, with similar indications and results[29].

Tear-Specific Biomechanics, Repair Techniques, and Outcomes

Meniscal tears are typically classified on the basis of their orientation, such as vertical longitudinal, horizontal, radial, oblique, and complex[50]. The biomechanical implications of each type of tear relate to the orientation of collagen-fiber disruption identified in the meniscal microstructure (Fig. 3)[17].

Vertical Longitudinal Tears

Biomechanics

Vertical longitudinal tears result from disruption of the superficial radial collagen fibers in line with the circumferential collagen fibers (Fig. 3). Larger tears can allow the inner meniscus to flip on itself, a condition commonly referred to as a "bucket-handle" meniscal tear[51]. When a vertical longitudinal tear is resected, a partial or complete meniscectomy can result, causing the contact pressures to nearly triple[52].

Repair Techniques and Outcomes

Acute, peripheral, vertical longitudinal tears demonstrate an exceptional capacity for healing. In 1 study, tears of <10 mm identified at the time of ACL reconstruction left in situ had a reoperation rate of 3.2% at an average of 6 years postoperatively, while in contrast, tears of >10 mm had a reoperation rate of 11.5%[39]. These are traditionally repaired using an inside-out technique (Fig. 4-A). Stacked vertical mattress sutures positioned every 3 to 5 mm provide biomechanical superiority over horizontal mattress configurations[53]. Concerns for increased neurovascular injury, needle-stick injury, and surgical time have led to the development and implementation of all-inside

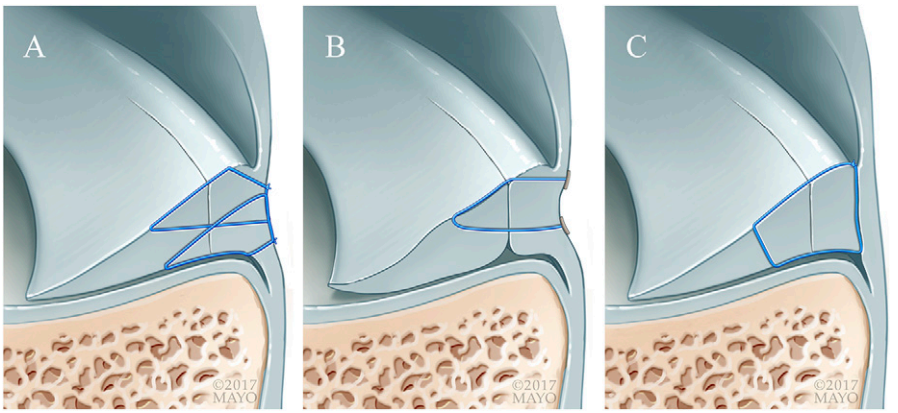

Fig. 4

Schematic diagrams demonstrating the suture configuration that results following surgical repair of a vertical longitudinal meniscal tears using an inside-out repair with knots tied over the capsule (**Fig. 4-A**), all-inside anchor-based construct (**Fig. 4-B**), and all-inside knot-tying technique (**Fig. 4-C**). (By permission of Mayo Foundation for Medical Education and Research. All rights reserved.)

techniques[28-30]. These techniques utilize anchor-based constructs with pretied slip knots (Fig. 4-B), or self-retrieving suture-passing devices followed by intra-articular knot tying (Fig. 4-C). Biomechanical testing has demonstrated similar loads to failure using all-inside techniques when compared with traditional inside-out meniscal repair[54]. Clinically, no difference in failure rate, functional outcomes, or complications has been identified[29]. The optimal repair technique should be determined on an individual basis by surgeon preference and familiarity.

Horizontal Tears

Biomechanics

Horizontal cleavage tears are unique in that the circumferential fibers remain intact from anterior to posterior meniscal roots (Fig. 3). Horizontal cleavage tears do not result in notable changes to the total contact surface area or contact pressures[55]. However, single leaflet resection was found to significantly reduce the contact area (by 59%), resulting in peak contact pressures similar to those measured following dual leaflet resection[56]. Repair of horizontal meniscal tears returns contact pressures to near-normal levels[55].

Repair Techniques and Outcomes

Since horizontal tears were once thought to have minimal healing capacity, either nonoperative strategies or meniscectomy were recommended[35]. However, with increasing recognition of the long-term implications of meniscectomy, attempts have been made to preserve both leaflets during repair. Video 1 demonstrates repair of a horizontal cleavage tear of the meniscus with circumferential compression stitches; see also Figure 5. Deteriorating outcomes have been demonstrated for meniscal repair with increasing age[57]. In younger patients, horizontal cleavage tear repair can provide excellent outcomes with healing rates similar to those noted for other tear patterns[58]. These tears should be differentiated from degenerative meniscal tears that occur in patients >50 years of age with associated arthritis[57-59]. The authors of a recent systematic review of horizontal cleavage tear repair reported on 98 patients from 9 independent studies[58]. The overall clinical healing rate was 78.6%. They concluded that the literature does not support the hypothesis that repair of horizontal cleavage tears has an unacceptably low rate of success. Biologic augmentation strategies may further improve healing rates[10,57,59-61].

Radial Tears

Biomechanics

Radial tears transect the circumferential collagen fibers of the central meniscus (Fig. 3). Radial meniscal tears of up to and including 60% of the central zone had no effect on pressure magnitude or location in both medial and lateral meniscal specimens[62,63], making them potential candidates for partial meniscectomy. However, tears involving 90% of the meniscus demonstrated significant increases in peak pressures[62,63]. Meniscal repair decreases peak pressures to near-normal levels[6].

Repair Techniques and Outcomes

Radial tears can be repaired using inside-out, all-inside, or transtibial techniques[64-66]. Video 2 demonstrates the repair of a radial tear of the meniscus; see also Figures 6-A, 6-B, and 6-C. Inside-out and anchor-based all-inside techniques generate tension against the periphery of the meniscus or capsule, creating horizontal mattress-suture configurations at the radial tear site. In contrast, all-inside sutures placed with self-retrieving suture-passing devices produce a vertical mattress-suture configuration that applies direct compression at the tear

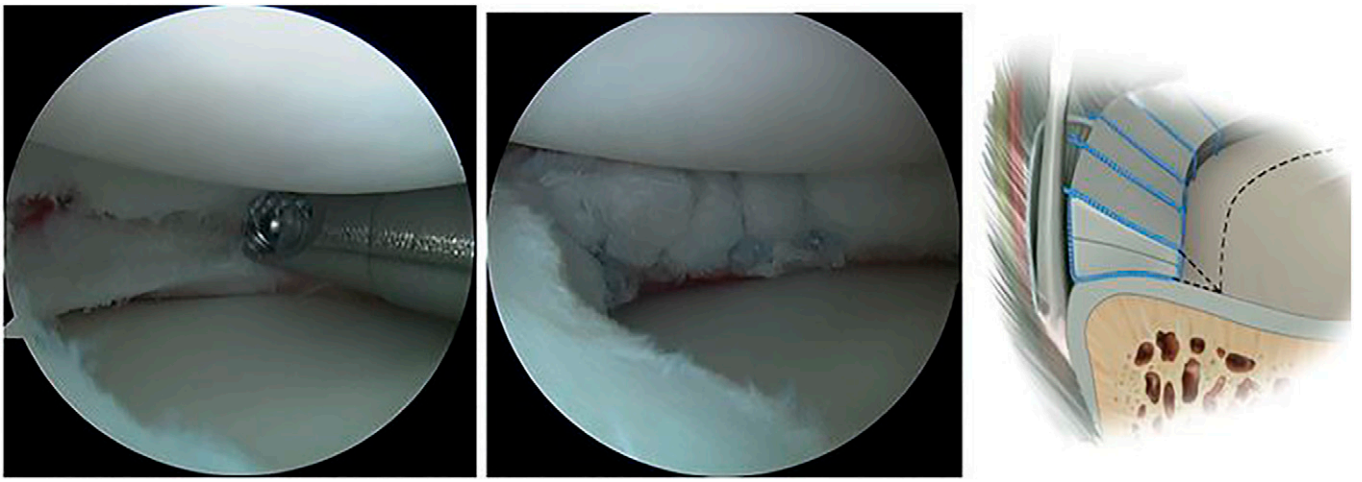

Fig. 5

Horizontal cleavage tear of the lateral meniscus. **Left panel** Arthroscopic image demonstrating tear site preparation with an arthroscopic shaver to stimulate peripheral bleeding. **Center panel** Arthroscopic image after placement of serial circumferential compression sutures. **Right panel** Schematic image demonstrating multiple all-inside circumferential compression sutures placed with a self-retrieving suture-passing device followed by arthroscopic knot tying. (By permission of Mayo Foundation for Medical Education and Research. All rights reserved.)

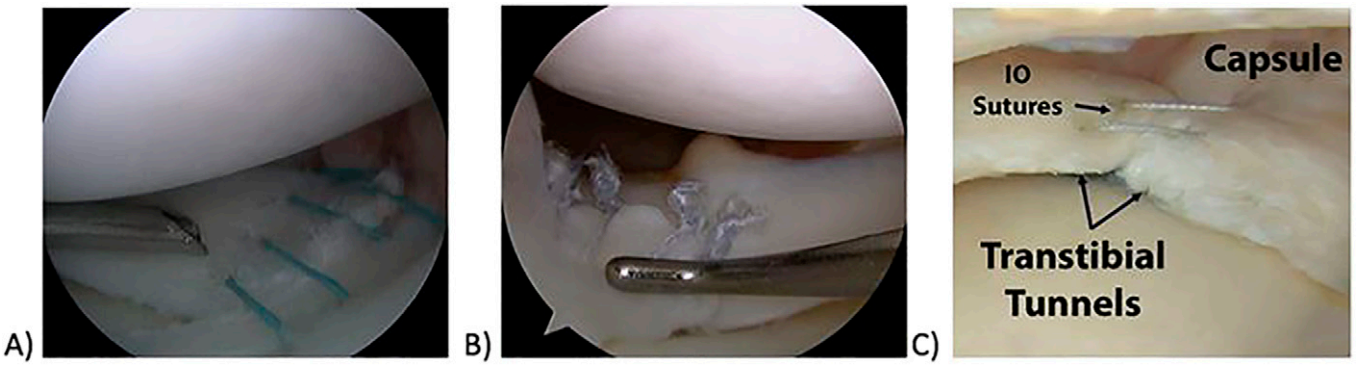

Fig. 6
Radial meniscal tear repair techniques. **Fig. 6-A** Arthroscopic image following inside-out repair of a right radial medial meniscal tear with horizontal mattress sutures. **Fig. 6-B** Arthroscopic image following all-inside repair with knot tying of a right radial medial meniscal tear. **Fig. 6-C** Arthroscopic image following a transtibial repair with inside-out (IO) horizontal mattress sutures of a radial tear of the left lateral meniscus.

site. The all-inside technique with a vertical-suture configuration demonstrated lower displacement, higher load to failure, and greater stiffness compared with the inside-out technique[67]. Chronic radial meniscal tears can introduce further complexity because of tear retraction. An anatomic transtibial meniscal repair technique encourages tear mobilization and crossed traction stitches through tibial tunnels (Fig. 6-C)[65]. This technique demonstrated significantly less gapping distance and significantly higher load to failure when compared with an inside-out technique[65]. Clinically, outcomes similar to those of vertical longitudinal meniscal tears repaired with an inside-out technique have been observed[68]. Biologic augmentation may enable healing of meniscal tears in the avascular zone[69].

Repair Enhancement and Biologic Augmentation

Healing of the meniscus following repair is affected by its inherently poor vascularity and acellularity[16]. While meniscectomy results in fewer reoperations, a successful repair leads to improved long-term clinical and radiographic outcomes[70]. Biologic augmentation strategies attempt to promote chemotaxis, cellular proliferation, and/or matrix production at the site of meniscal repair to help overcome healing limitations[8]. Extensive research is currently under way at the clinical, in vitro, and in vivo levels to improve healing rates following meniscal repair[71]. Current clinical applications include mechanical stimulation, marrow venting procedures, the use of fibrin clots, platelet-rich plasma injections, and stem cell-based therapies.

Mechanical Stimulation

Abrasion of the adjacent synovium or trephination of the meniscus has been proposed as a means to improve the healing response[71]. Synovial rasping is thought to promote neovascularization, with documented increases in interleukin-1-alpha, proliferating cell nuclear antigen, transforming growth factor β1, and platelet-derived growth factor in a rabbit model[72]. Trephination is the creation of a channel between a region of increased vascularity and an avascular region[73,74]. In a goat model, improved healing (even in the avascular zone) was demonstrated when trephination was added to meniscal repair[73]. Clinically, trephination of symptomatic incomplete meniscal tears has demonstrated >90% good to excellent

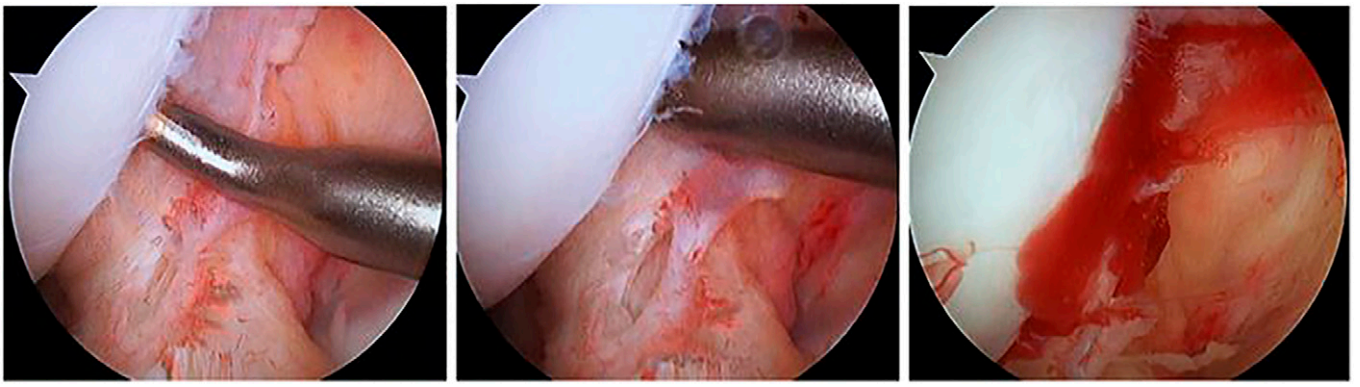

Fig. 7
Arthroscopic images demonstrating a marrow venting procedure. **Left panel** An awl is placed against the cortex within the femoral notch. **Center panel** The awl after mallet-assisted advancement through the outer cortex. **Right panel** Marrow elements being released after removal of the awl.

TABLE II Standardized Meniscal Repair Rehabilitation Protocol for All Meniscal Tear Repairs

Time *(wk)*	Knee Immobilizer	Weight-Bearing	Active/Passive Range of Motion	Loaded Range of Motion
0-4	During ambulation	Toe-touch*	0°-90°	0°
>4-6	No	Partial*	0°-90°	0°-90°
>6-8	No	Full	0°-90°	0°-90°
>8-16	No	Full	No restrictions	0°-90°
>16	No	Full	No restrictions	No restrictions

*If a concomitant ACL reconstruction was performed, immediate full weight-bearing is allowed for vertical longitudinal and horizontal tear patterns. If an isolated repair for a vertical longitudinal or horizontal tear pattern was performed, then partial weight-bearing is allowed immediately.

results[75]. The degree of mechanical stimulation achieved through trephination is balanced by the recognition that normal circumferential fibers are disrupted, which can affect the hoop-stress distribution properties of the meniscus.

Marrow Venting Procedures

Marrow venting procedures are performed in an attempt to replicate the biologic environment created by ACL tunnel drilling[76] (Fig. 7). In a goat model, the addition of marrow venting significantly improved the rate of meniscal healing[77]. Dean et al. performed a Level-II comparative cohort study of patients who underwent an isolated meniscal tear repair with a marrow venting procedure (intercondylar notch) or meniscal repair in conjunction with an ACL reconstruction[78]. There was no significant difference in the rate of failed meniscal repair between the 2 cohorts at a minimum of 2 years follow-up.

Use of Fibrin Clot

Clinical studies have demonstrated the effectiveness of the use of a fibrin clot at the site of meniscal repair[69,79,80]. Jang et al. obtained a fibrin clot from autologous blood and implanted it using an inside-out suture technique[79]. A success rate of 95% (39 of 41) was reported after second-look arthroscopy or MRI at a mean of 8.3 months. Similarly, Ra et al. performed an inside-out suture repair technique with the use of a fibrin clot and demonstrated that 11 of 12 patients had complete healing on postoperative clinical assessment[69]. To our knowledge, there has been no comparative study showing the superiority of adding fibrin clot use to meniscal repair.

Platelet-Rich Plasma Injections

Platelet-rich plasma is currently being used for many indications, including lateral epicondylitis[81], partial-thickness rotator cuff tears[82], and Achilles tendon ruptures[83]. However, we are aware of only 2 trials (Level III) that have assessed the effectiveness of platelet-rich plasma injections for meniscal pathology[84,85]. Both studies found no difference in reoperation rate between meniscal repairs performed in isolation and those that received treatment with platelet-rich plasma. However, Pujol et al.[85] reported improved pain and functional scores at a minimum of 24 months in the cohort in which platelet-rich plasma was introduced into the lesion following meniscal repair. As a future option of biologic therapy, the feasibility of introducing growth factors to enhance meniscal repair has been tested in animal studies[86-88]. While promising data have been provided by these studies, the role of platelet-rich plasma as an adjuvant in meniscal repair in humans needs further investigation.

Stem Cell-Based Therapy

Preclinical porcine studies demonstrated that implantation of mesenchymal stem cell (MSC)-based tissue-engineered constructs or repetitive intra-articular injection of MSCs improves the quality of meniscal repair while protecting articular cartilage from degenerative change[89,90], suggesting the feasibility of MSC-based therapy in meniscal repair. Vangsness et al. assessed the safety and response of the knee to MSC injections following partial meniscectomy[91]. Volumetric assessment of the meniscus revealed that 25% of the patients had a significant increase in meniscal volume (defined threshold of >15%). The authors concluded that treatment with MSCs demonstrated evidence of meniscal regeneration and supported its use for future meniscal research. Piontek et al. subsequently treated a consecutive series of meniscal tears involving the avascular zone with all-inside suture repair, wrapping with a collagen membrane, and bone marrow blood injection[92]. At 2 years of follow-up, 86.8% of the patients demonstrated clinical improvement and 76% had nonhomogeneous MRI signal with no evidence of a meniscal tear. While these results are promising, further investigation is needed to determine the role of stem cell therapy in treating meniscal repairs.

Biomaterial Augmentation

Henning et al. demonstrated that the use of a fascia sheath to cover the repaired area improved healing rates of complex meniscal tears, including double-flap, double-longitudinal, and radial tears, with the exception of tears in the middle third of the lateral meniscus[93]. The potential use of a nanofibrous, woven biomaterial-based membrane for meniscal repair has been investigated[94], with promising results. With the confirmation of safety and efficacy, such biologic membranes could increase the opportunities to treat complex meniscal tears, without the risk of donor-site morbidity or disease transmission.

Rehabilitation

A variety of rehabilitation protocols have been advocated, with no current consensus regarding weight-bearing status, range-of-motion restrictions, bracing, or the rate of progression through each stage of the protocol[95]. Biomechanical testing has demonstrated that meniscal-tear patterns react differently under physiologic loads. Vertical longitudinal tears are reduced and compressed during weight-bearing in extension through the redistribution of hoop stresses[96]. In contrast, radial tear patterns are exposed to distraction forces at the repair site during loading, which may compromise healing[97]. Similarly, terminal flexion increases the compressive stresses on the meniscus[98,99]. While accelerated rehabilitation protocols (allowing early weight-bearing and unrestricted range of motion) have demonstrated results equivalent to restricted protocols for vertical longitudinal tears[100], to our knowledge, there is currently no evidence for their use for horizontal or radial tear patterns. Given the absence of the superiority of using an accelerated protocol, the frequency of combined tear pattern injuries, the implications of a failed repair, and to prevent misinterpretation among therapists, a standardized protocol designed to protect all meniscal repairs throughout healing should be considered (Table II).

The Failed Meniscal Repair

The reported rate of failed meniscal repair ranges from 0% to 43.5%, with a mean of 15%[101]. Failure is commonly defined as meniscectomy following meniscal repair[102]. While the volume of meniscus resected at revision is rarely increased when compared with the initial lesion[103], the effects of repeat surgery, prolonged immobilization, muscle atrophy, and associated costs to the individual, employer, and health-care system are important considerations.

In carefully selected patients, revision meniscal repair can provide good results. Krych et al.[104] evaluated 34 patients following revision meniscal repair and demonstrated that 79% of the patients remained pain-free with no mechanical symptoms or further surgery at 72 months. Degenerative changes at the time of repair have been identified as a potential risk factor for failure[105]. Prospective analysis of this patient population is needed to better define which patients should undergo a revision meniscal repair. Irreparable tears should undergo partial meniscectomy, preserving as much meniscus as possible[5].

Meniscal Deficiency

Patients who develop pain in the involved compartment in the absence of arthritis, malalignment, or ligamentous instability warrant consideration for meniscal allograft transplantation[106]. Collagen meniscal implants and synthetic-based meniscal scaffolds have also demonstrated improved functional outcomes when implanted in patients with focal meniscal deficiency[107].

Conclusions

Meniscal repair provides improved long-term outcomes, better clinical outcome scores, and less severe degenerative changes seen radiographically compared with partial meniscectomy. Advancements in surgical techniques have expanded the capability for meniscal repair, while the implementation of biologic augmentation appears to improve healing rates. However, clinical data remain sparse, and prospective randomized trials are needed. It is critical that surgeons treating meniscal tears be familiar with the evolving repair techniques to optimize the health and longevity of the knee joint. ■

Jarret M. Woodmass, MD, FRCS(C)[1]
Robert F. LaPrade, MD, PhD[2]
Nicholas A. Sgaglione, MD[3]
Norimasa Nakamura, MD, PhD[4]
Aaron J. Krych, MD[1]

[1]Department of Orthopedic Surgery and Sports Medicine, Mayo Clinic, Rochester, Minnesota

[2]The Steadman Clinic, Steadman Philippon Research Institute, Vail, Colorado

[3]Department of Orthopedics, Northwell Health System, Great Neck, New York

[4]Institute for Medical Science in Sports, Osaka Health Science University, Osaka, Japan

ORCID iD for A.J. Krych: 0000-0003-3248-8007

References

1. Sutton JB. Ligaments: their nature and morphology. London: MK Lewis; 1987.
2. Dandy DJ, Jackson RW. The diagnosis of problems after meniscectomy. J Bone Joint Surg Br. 1975 Aug;57(3):349-52.
3. Nelson CG, Bonner KF. Inside-out meniscus repair. Arthrosc Tech. 2013 Nov 1;2(4):e453-60.
4. Shoemaker SC, Markolf KL. The role of the meniscus in the anterior-posterior stability of the loaded anterior cruciate-deficient knee. Effects of partial versus total excision. J Bone Joint Surg Am. 1986 Jan;68(1):71-9.
5. Hede A, Larsen E, Sandberg H. Partial versus total meniscectomy. A prospective, randomised study with long-term follow-up. J Bone Joint Surg Br. 1992 Jan;74(1):118-21.
6. Zhang AL, Miller SL, Coughlin DG, Lotz JC, Feeley BT. Tibiofemoral contact pressures in radial tears of the meniscus treated with all-inside repair, inside-out repair and partial meniscectomy. Knee. 2015 Oct;22(5):400-4. Epub 2015 Jun 14.
7. Hede A, Larsen E, Sandberg H. The long term outcome of open total and partial meniscectomy related to the quantity and site of the meniscus removed. Int Orthop. 1992;16(2):122-5.
8. Moran CJ, Busilacchi A, Lee CA, Athanasiou KA, Verdonk PC. Biological augmentation and tissue engineering approaches in meniscus surgery. Arthroscopy. 2015 May;31(5):944-55. Epub 2015 Feb 14.
9. Hutchinson ID, Moran CJ, Potter HG, Warren RF, Rodeo SA. Restoration of the meniscus: form and function. Am J Sports Med. 2014 Apr;42(4):987-98. Epub 2013 Aug 12.
10. Kamimura T, Kimura M. Repair of horizontal meniscal cleavage tears with exogenous fibrin clots. Knee Surg Sports Traumatol Arthrosc. 2011 Jul;19(7):1154-7. Epub 2011 Feb 3.
11. Choi NH, Kim TH, Son KM, Victoroff BN. Meniscal repair for radial tears of the midbody of the lateral meniscus. Am J Sports Med. 2010 Dec;38(12):2472-6. Epub 2010 Sep 8.

12. McDermott ID, Amis AA. The consequences of meniscectomy. J Bone Joint Surg Br. 2006 Dec;88(12):1549-56.

13. McDermott ID, Sharifi F, Bull AM, Gupte CM, Thomas RW, Amis AA. An anatomical study of meniscal allograft sizing. Knee Surg Sports Traumatol Arthrosc. 2004 Mar;12(2):130-5. Epub 2003 May 20.

14. Kusayama T, Harner CD, Carlin GJ, Xerogeanes JW, Smith BA. Anatomical and biomechanical characteristics of human meniscofemoral ligaments. Knee Surg Sports Traumatol Arthrosc. 1994;2(4):234-7.

15. Arnoczky SP, Warren RF. Microvasculature of the human meniscus. Am J Sports Med. 1982 Mar-Apr;10(2):90-5.

16. Makris EA, Hadidi P, Athanasiou KA. The knee meniscus: structure-function, pathophysiology, current repair techniques, and prospects for regeneration. Biomaterials. 2011 Oct;32(30):7411-31. Epub 2011 Jul 18.

17. Petersen W, Tillmann B. Collagenous fibril texture of the human knee joint menisci. Anat Embryol (Berl). 1998 Apr;197(4):317-24.

18. Lanzer WL, Komenda G. Changes in articular cartilage after meniscectomy. Clin Orthop Relat Res. 1990 Mar;252:41-8.

19. Nakata K, Shino K, Hamada M, Mae T, Miyama T, Shinjo H, Horibe S, Tada K, Ochi T, Yoshikawa H. Human meniscus cell: characterization of the primary culture and use for tissue engineering. Clin Orthop Relat Res. 2001 Oct;391(Suppl): S208-18.

20. Cook JL, Kuroki K, Stoker AM, Monibi FA, Roller BL. Meniscal biology in health and disease. Connect Tissue Res. 2017 May - Jul;58(3-4):225-37. Epub 2016 Oct 7.

21. Brophy RH, Sandell LJ, Rai MF. Traumatic and degenerative meniscus tears have different gene expression signatures. Am J Sports Med. 2017 Jan;45 (1):114-20. Epub 2016 Oct 1.

22. Bigoni M, Turati M, Sacerdote P, Gaddi D, Piatti M, Castelnuovo A, Franchi S, Gandolla M, Pedrocchi A, Omeljaniuk RJ, Bresciani E, Locatelli V, Torsello A. Characterization of synovial fluid cytokine profiles in chronic meniscal tear of the knee. J Orthop Res. 2017 Feb;35(2):340-6. Epub 2016 May 2.

23. Larsson S, Englund M, Struglics A, Lohmander LS. Interleukin-6 and tumor necrosis factor alpha in synovial fluid are associated with progression of radiographic knee osteoarthritis in subjects with previous meniscectomy. Osteoarthritis Cartilage. 2015 Nov;23(11):1906-14.

24. Goldring MB, Otero M. Inflammation in osteoarthritis. Curr Opin Rheumatol. 2011 Sep;23(5):471-8.

25. Paxton ES, Stock MV, Brophy RH. Meniscal repair versus partial meniscectomy: a systematic review comparing reoperation rates and clinical outcomes. Arthroscopy. 2011 Sep;27(9):1275-88. Epub 2011 Aug 6.

26. Scott GA, Jolly BL, Henning CE. Combined posterior incision and arthroscopic intra-articular repair of the meniscus. An examination of factors affecting healing. J Bone Joint Surg Am. 1986 Jul;68(6):847-61.

27. Arnoczky SP, Warren RF. The microvasculature of the meniscus and its response to injury. An experimental study in the dog. Am J Sports Med. 1983 May-Jun;11(3):131-41.

28. Grant JA, Wilde J, Miller BS, Bedi A. Comparison of inside-out and all-inside techniques for the repair of isolated meniscal tears: a systematic review. Am J Sports Med. 2012 Feb;40(2):459-68. Epub 2011 Jul 7.

29. Fillingham YA, Riboh JC, Erickson BJ, Bach BR Jr, Yanke AB. Inside-out versus all-inside repair of isolated meniscal tears. Am J Sports Med. 2017 Jan;45(1):234-42. Epub 2016 Jul 21.

30. Ayeni O, Peterson D, Chan K, Javidan A, Gandhi R. Suture repair versus arrow repair for symptomatic meniscus tears of the knee: a systematic review. J Knee Surg. 2012 Nov;25(5):397-402. Epub 2012 May 15.

31. Noyes FR, Barber-Westin SD. Arthroscopic repair of meniscus tears extending into the avascular zone with or without anterior cruciate ligament reconstruction in patients 40 years of age and older. Arthroscopy. 2000 Nov;16(8):822-9.

32. Noyes FR, Barber-Westin SD. Arthroscopic repair of meniscal tears extending into the avascular zone in patients younger than twenty years of age. Am J Sports Med. 2002 Jul-Aug;30(4):589-600.

33. Krych AJ, Pitts RT, Dajani KA, Stuart MJ, Levy BA, Dahm DL. Surgical repair of meniscal tears with concomitant anterior cruciate ligament reconstruction in patients 18 years and younger. Am J Sports Med. 2010 May;38(5):976-82. Epub 2010 Mar 18.

34. Krych AJ, McIntosh AL, Voll AE, Stuart MJ, Dahm DL. Arthroscopic repair of isolated meniscal tears in patients 18 years and younger. Am J Sports Med. 2008 Jul;36(7):1283-9. Epub 2008 Mar 4.

35. Yim JH, Seon JK, Song EK, Choi JI, Kim MC, Lee KB, Seo HY. A comparative study of meniscectomy and nonoperative treatment for degenerative horizontal tears of the medial meniscus. Am J Sports Med. 2013 Jul;41(7):1565-70. Epub 2013 May 23.

36. Cannon WD Jr, Vittori JM. The incidence of healing in arthroscopic meniscal repairs in anterior cruciate ligament-reconstructed knees versus stable knees. Am J Sports Med. 1992 Mar-Apr;20(2):176-81.

37. LaPrade CM, LaPrade MD, Turnbull TL, Wijdicks CA, LaPrade RF. Biomechanical evaluation of the transtibial pull-out technique for posterior medial meniscal root repairs using 1 and 2 transtibial bone tunnels. Am J Sports Med. 2015 Apr;43 (4):899-904. Epub 2015 Jan 8.

38. LaPrade RF, Matheny LM, Moulton SG, James EW, Dean CS. Posterior meniscal root repairs: outcomes of an anatomic transtibial pull-out technique. Am J Sports Med. 2017 Mar;45(4):884-91. Epub 2016 Dec 5.

39. Duchman KR, Westermann RW, Spindler KP, Reinke EK, Huston LJ, Amendola A, Wolf BR; MOON Knee Group. The fate of meniscus tears left in situ at the time of anterior cruciate ligament reconstruction: a 6-year follow-up study from the MOON cohort. Am J Sports Med. 2015 Nov;43(11):2688-95. Epub 2015 Oct 1.

40. Howell R, Kumar NS, Patel N, Tom J. Degenerative meniscus: Pathogenesis, diagnosis, and treatment options. World J Orthop. 2014 Nov 18;5(5):597-602.

41. Mesiha M, Zurakowski D, Soriano J, Nielson JH, Zarins B, Murray MM. Pathologic characteristics of the torn human meniscus. Am J Sports Med. 2007 Jan;35 (1):103-12. Epub 2006 Nov 7.

42. Katz JN, Brophy RH, Chaisson CE, de Chaves L, Cole BJ, Dahm DL, Donnell-Fink LA, Guermazi A, Haas AK, Jones MH, Levy BA, Mandl LA, Martin SD, Marx RG, Miniaci A, Matava MJ, Palmisano J, Reinke EK, Richardson BE, Rome BN, Safran-Norton CE, Skoniecki DJ, Solomon DH, Smith MV, Spindler KP, Stuart MJ, Wright J, Wright RW, Losina E. Surgery versus physical therapy for a meniscal tear and osteoarthritis. N Engl J Med. 2013 May 2;368(18):1675-84. Epub 2013 Mar 18.

43. Sihvonen R, Paavola M, Malmivaara A, Itälä A, Joukainen A, Nurmi H, Kalske J, Järvinen TL; Finnish Degenerative Meniscal Lesion Study (FIDELITY) Group. Arthroscopic partial meniscectomy versus sham surgery for a degenerative meniscal tear. N Engl J Med. 2013 Dec 26;369(26):2515-24.

44. Marsh JD, Birmingham TB, Giffin JR, Isaranuwatchai W, Hoch JS, Feagan BG, Litchfield R, Willits K, Fowler P. Cost-effectiveness analysis of arthroscopic surgery compared with non-operative management for osteoarthritis of the knee. BMJ Open. 2016 Jan 12;6(1):e009949.

45. Zanetti M, Pfirrmann CW, Schmid MR, Romero J, Seifert B, Hodler J. Patients with suspected meniscal tears: prevalence of abnormalities seen on MRI of 100 symptomatic and 100 contralateral asymptomatic knees. AJR Am J Roentgenol. 2003 Sep;181(3):635-41.

46. Nepple JJ, Dunn WR, Wright RW. Meniscal repair outcomes at greater than five years: a systematic literature review and meta-analysis. J Bone Joint Surg Am. 2012 Dec 19;94(24):2222-7.

47. Lutz C, Dalmay F, Ehkirch FP, Cucurulo T, Laporte C, Le Henaff G, Potel JF, Pujol N, Rochcongar G, Salledechou E, Seil R, Gunepin FX, Sonnery-Cottet B, French Arthroscopy Society. Meniscectomy versus meniscal repair: 10 years radiological and clinical results in vertical lesions in stable knee. Orthop Traumatol Surg Res. 2015 Dec;101(8 Suppl):S327-31.

48. Cho JH. A modified outside-in suture technique for repair of the middle segment of the meniscus using a spinal needle. Knee Surg Relat Res. 2014 Mar;26(1):43-7. Epub 2014 Feb 27.

49. Lembach M, Johnson DL. Meniscal repair techniques required for the surgeon performing anterior cruciate ligament reconstruction. Orthopedics. 2014 Sep;37 (9):617-21.

50. Klimkiewicz JJ, Shaffer B. Meniscal surgery 2002 update: indications and techniques for resection, repair, regeneration, and replacement. Arthroscopy. 2002 Nov-Dec;18(9)(Suppl 2):14-25.

51. Dandy DJ. The bucket handle meniscal tear: a technique detaching the posterior segment first. Orthop Clin North Am. 1982 Apr;13(2):369-85.

52. Baratz ME, Fu FH, Mengato R. Meniscal tears: the effect of meniscectomy and of repair on intraarticular contact areas and stress in the human knee. A preliminary report. Am J Sports Med. 1986 Jul-Aug;14(4):270-5.

53. Rankin CC, Lintner DM, Noble PC, Paravic V, Greer E. A biomechanical analysis of meniscal repair techniques. Am J Sports Med. 2002 Jul-Aug;30(4):492-7.

54. Barber FA, Herbert MA, Richards DP. Load to failure testing of new meniscal repair devices. Arthroscopy. 2004 Jan;20(1):45-50.

55. Koh JL, Yi SJ, Ren Y, Zimmerman TA, Zhang LQ. Tibiofemoral contact mechanics with horizontal cleavage tear and resection of the medial meniscus in the human knee. J Bone Joint Surg Am. 2016 Nov 2;98(21):1829-36.

56. Haemer JM, Wang MJ, Carter DR, Giori NJ. Benefit of single-leaf resection for horizontal meniscus tear. Clin Orthop Relat Res. 2007 Apr;457:194-202.

57. Pujol N, Bohu Y, Boisrenoult P, Macdes A, Beaufils P. Clinical outcomes of open meniscal repair of horizontal meniscal tears in young patients. Knee Surg Sports Traumatol Arthrosc. 2013 Jul;21(7):1530-3. Epub 2012 Jun 14.

58. Kurzweil PR, Lynch NM, Coleman S, Kearney B. Repair of horizontal meniscus tears: a systematic review. Arthroscopy. 2014 Nov;30(11):1513-9. Epub 2014 Aug 6.

59. Ahn JH, Kwon OJ, Nam TS. Arthroscopic repair of horizontal meniscal cleavage tears with marrow-stimulating technique. Arthroscopy. 2015 Jan;31(1):92-8. Epub 2014 Sep 18.

60. Kamimura T, Kimura M. Meniscal repair of degenerative horizontal cleavage tears using fibrin clots: clinical and arthroscopic outcomes in 10 cases. Orthop J Sports Med. 2014 Nov 10;2(11):2325967114555678.

61. Sallé de Chou E, Pujol N, Rochcongar G, Cucurulo T, Potel JF, Dalmay F, Ehkirch FP, Laporte C, Le Henaff G, Seil R, Lutz C, Gunepin FX, Sonnery-Cottet B; Société

Française d'Arthroscopie. Analysis of short and long-term results of horizontal meniscal tears in young adults. Orthop Traumatol Surg Res. 2015 Dec;101(8)(Suppl): S317-22. Epub 2015 Oct 23.

62. Bedi A, Kelly N, Baad M, Fox AJ, Ma Y, Warren RF, Maher SA. Dynamic contact mechanics of radial tears of the lateral meniscus: implications for treatment. Arthroscopy. 2012 Mar;28(3):372-81. Epub 2011 Nov 9.

63. Bedi A, Kelly NH, Baad M, Fox AJ, Brophy RH, Warren RF, Maher SA. Dynamic contact mechanics of the medial meniscus as a function of radial tear, repair, and partial meniscectomy. J Bone Joint Surg Am. 2010 Jun;92(6):1398-408.

64. Branch EA, Milchteim C, Aspey BS, Liu W, Saliman JD, Anz AW. Biomechanical comparison of arthroscopic repair constructs for radial tears of the meniscus. Am J Sports Med. 2015 Sep;43(9):2270-6. Epub 2015 Aug 5.

65. Bhatia S, Civitarese DM, Turnbull TL, LaPrade CM, Nitri M, Wijdicks CA, LaPrade RF. A novel repair method for radial tears of the medial meniscus: biomechanical comparison of transtibial 2-tunnel and double horizontal mattress suture techniques under cyclic loading. Am J Sports Med. 2016 Mar;44(3):639-45. Epub 2015 Dec 8.

66. Pareek A, O'Malley MP, Levy BA, Stuart MJ, Krych AJ. Inside-out repair for radial meniscus tears. Arthrosc Tech. 2016 Jul 25;5(4):e793-7.

67. Beamer BS, Masoudi A, Walley KC, Harlow ER, Manoukian OS, Hertz B, Haeussler C, Olson JJ, Deangelis JP, Nazarian A, Ramappa AJ. Analysis of a new all-inside versus inside-out technique for repairing radial meniscal tears. Arthroscopy. 2015 Feb;31(2):293-8. Epub 2014 Oct 11.

68. Cinque ME, Geeslin AG, Chahla J, Dornan GJ, LaPrade RF. Two-tunnel transtibial repair of radial meniscus tears produces comparable results to inside-out repair of vertical meniscus tears. Am J Sports Med. 2017 May 1:363546517704425. Epub 2017 May 1.

69. Ra HJ, Ha JK, Jang SH, Lee DW, Kim JG. Arthroscopic inside-out repair of complete radial tears of the meniscus with a fibrin clot. Knee Surg Sports Traumatol Arthrosc. 2013 Sep;21(9):2126-30. Epub 2012 Sep 22.

70. Xu C, Zhao J. A meta-analysis comparing meniscal repair with meniscectomy in the treatment of meniscal tears: the more meniscus, the better outcome? Knee Surg Sports Traumatol Arthrosc. 2015 Jan;23(1):164-70. Epub 2013 May 14.

71. Taylor SA, Rodeo SA. Augmentation techniques for isolated meniscal tears. Curr Rev Musculoskelet Med. 2013 Jun;6(2):95-101.

72. Ochi M, Uchio Y, Okuda K, Shu N, Yamaguchi H, Sakai Y. Expression of cytokines after meniscal rasping to promote meniscal healing. Arthroscopy. 2001 Sep;17(7):724-31.

73. Zhang Z, Arnold JA, Williams T, McCann B. Repairs by trephination and suturing of longitudinal injuries in the avascular area of the meniscus in goats. Am J Sports Med. 1995 Jan-Feb;23(1):35-41.

74. Zhang Z, Arnold JA. Trephination and suturing of avascular meniscal tears: a clinical study of the trephination procedure. Arthroscopy. 1996 Dec;12(6):726-31.

75. Fox JM, Rintz KG, Ferkel RD. Trephination of incomplete meniscal tears. Arthroscopy. 1993;9(4):451-5.

76. McNulty AL, Weinberg JB, Guilak F. Inhibition of matrix metalloproteinases enhances in vitro repair of the meniscus. Clin Orthop Relat Res. 2009 Jun;467 (6):1557-67. Epub 2008 Oct 31.

77. Howarth WR, Brochard K, Campbell SE, Grogan BF. Effect of microfracture on meniscal tear healing in a goat (Capra hircus) model. Orthopedics. 2016 Mar-Apr;39 (2):105-10. Epub 2016 Jan 25.

78. Dean CS, Chahla J, Matheny LM, Mitchell JJ, LaPrade RF. Outcomes after biologically augmented isolated meniscal repair with marrow venting are comparable with those after meniscal repair with concomitant anterior cruciate ligament reconstruction. Am J Sports Med. 2017 May;45(6):1341-8. Epub 2017 Feb 1.

79. Jang SH, Ha JK, Lee DW, Kim JG. Fibrin clot delivery system for meniscal repair. Knee Surg Relat Res. 2011 Sep;23(3):180-3. Epub 2011 Sep 26.

80. Henning CE, Lynch MA, Yearout KM, Vequist SW, Stallbaumer RJ, Decker KA. Arthroscopic meniscal repair using an exogenous fibrin clot. Clin Orthop Relat Res. 1990 Mar;252:64-72.

81. Gosens T, Peerbooms JC, van Laar W, den Oudsten BL. Ongoing positive effect of platelet-rich plasma versus corticosteroid injection in lateral epicondylitis: a double-blind randomized controlled trial with 2-year follow-up. Am J Sports Med. 2011 Jun;39(6):1200-8. Epub 2011 Mar 21.

82. Shams A, El-Sayed M, Gamal O, Ewes W. Subacromial injection of autologous platelet-rich plasma versus corticosteroid for the treatment of symptomatic partial rotator cuff tears. Eur J Orthop Surg Traumatol. 2016 Dec;26(8):837-42. Epub 2016 Aug 20.

83. Zou J, Mo X, Shi Z, Li T, Xue J, Mei G, Li X. A prospective study of platelet-rich plasma as biological augmentation for acute Achilles tendon rupture repair. Biomed Res Int. 2016;2016:9364170. Epub 2016 Dec 28.

84. Griffin JW, Hadeed MM, Werner BC, Diduch DR, Carson EW, Miller MD. Platelet-rich plasma in meniscal repair: does augmentation improve surgical outcomes? Clin Orthop Relat Res. 2015 May;473(5):1665-72. Epub 2015 Feb 6.

85. Pujol N, Salle De Chou E, Boisrenoult P, Beaufils P. Platelet-rich plasma for open meniscal repair in young patients: any benefit? Knee Surg Sports Traumatol Arthrosc. 2015 Jan;23(1):51-8. Epub 2014 Nov 7.

86. Forriol F, Longo UG, Duart J, Ripalda P, Vaquero J, Loppini M, Romeo G, Campi S, Khan WS, Muda AO, Denaro V. VEGF, BMP-7, Matrigel(TM), hyaluronic acid, in vitro cultured chondrocytes and trephination for healing of the avascular portion of the meniscus. An experimental study in sheep. Curr Stem Cell Res Ther. 2015;10 (1):69-76.

87. Parrish WR, Byers BA, Su D, Geesin J, Herzberg U, Wadsworth S, Bendele A, Story B. Intra-articular therapy with recombinant human GDF5 arrests disease progression and stimulates cartilage repair in the rat medial meniscus transection (MMT) model of osteoarthritis. Osteoarthritis Cartilage. 2017 Apr;25(4):554-60. Epub 2016 Nov 13.

88. Cucchiarini M, McNulty AL, Mauck RL, Setton LA, Guilak F, Madry H. Advances in combining gene therapy with cell and tissue engineering-based approaches to enhance healing of the meniscus. Osteoarthritis Cartilage. 2016 Aug;24(8):1330-9. Epub 2016 Apr 5.

89. Moriguchi Y, Tateishi K, Ando W, Shimomura K, Yonetani Y, Tanaka Y, Kita K, Hart DA, Gobbi A, Shino K, Yoshikawa H, Nakamura N. Repair of meniscal lesions using a scaffold-free tissue-engineered construct derived from allogenic synovial MSCs in a miniature swine model. Biomaterials. 2013 Mar;34(9):2185-93. Epub 2012 Dec 20.

90. Hatsushika D, Muneta T, Nakamura T, Horie M, Koga H, Nakagawa Y, Tsuji K, Hishikawa S, Kobayashi E, Sekiya I. Repetitive allogeneic intraarticular injections of synovial mesenchymal stem cells promote meniscus regeneration in a porcine massive meniscus defect model. Osteoarthritis Cartilage. 2014 Jul;22(7):941-50. Epub 2014 May 2.

91. Vangsness CT Jr, Farr J 2nd, Boyd J, Dellaero DT, Mills CR, LeRoux-Williams M. Adult human mesenchymal stem cells delivered via intra-articular injection to the knee following partial medial meniscectomy: a randomized, double-blind, controlled study. J Bone Joint Surg Am. 2014 Jan 15;96(2):90-8.

92. Piontek T, Ciemniewska-Gorzela K, Naczk J, Jakob R, Szulc A, Grygorowicz M, Slomczykowski M. Complex meniscus tears treated with collagen matrix wrapping and bone marrow blood injection: a two-year clinical follow-up. Cartilage. 2016 Apr;7 (2):123-39. Epub 2015 Nov 30.

93. Henning CE, Yearout KM, Vequist SW, Stallbaumer RJ, Decker KA. Use of the fascia sheath coverage and exogenous fibrin clot in the treatment of complex meniscal tears. Am J Sports Med. 1991 Nov-Dec;19(6):626-31.

94. Shimomura K, Bean AC, Lin H, Nakamura N, Tuan RS. In vitro repair of meniscal radial tear using aligned electrospun nanofibrous scaffold. Tissue Eng Part A. 2015 Jul;21(13-14):2066-75. Epub 2015 May 4.

95. O'Donnell K, Freedman KB, Tjoumakaris FP. Rehabilitation protocols after isolated meniscal repair. Am J Sports Med. 2016 Oct 1:363546516667578. Epub 2016 Oct 1. [Epub ahead of print].

96. Richards DP, Barber FA, Herbert MA. Compressive loads in longitudinal lateral meniscus tears: a biomechanical study in porcine knees. Arthroscopy. 2005 Dec;21 (12):1452-6.

97. Gao J, Wei X, Messner K. Healing of the anterior attachment of the rabbit meniscus to bone. Clin Orthop Relat Res. 1998 Mar;348:246-58.

98. Johal P, Williams A, Wragg P, Hunt D, Gedroyc W. Tibio-femoral movement in the living knee. A study of weight bearing and non-weight bearing knee kinematics using 'interventional' MRI. J Biomech. 2005 Feb;38(2):269-76.

99. Becker R, Wirz D, Wolf C, Göpfert B, Nebelung W, Friederich N. Measurement of meniscofemoral contact pressure after repair of bucket-handle tears with biodegradable implants. Arch Orthop Trauma Surg. 2005 May;125(4):254-60. Epub 2004 Sep 7.

100. Barber FA. Accelerated rehabilitation for meniscus repairs. Arthroscopy. 1994 Apr;10(2):206-10.

101. Lozano J, Ma CB, Cannon WD. All-inside meniscus repair: a systematic review. Clin Orthop Relat Res. 2007 Feb;455:134-41.

102. Popescu D, Sastre S, Caballero M, Lee JW, Claret I, Nuñez M, Lozano L. Meniscal repair using the FasT-Fix device in patients with chronic meniscal lesions. Knee Surg Sports Traumatol Arthrosc. 2010 Apr;18(4):546-50. Epub 2009 Sep 26.

103. Pujol N, Barbier O, Boisrenoult P, Beaufils P. Amount of meniscal resection after failed meniscal repair. Am J Sports Med. 2011 Aug;39(8):1648-52. Epub 2011 Apr 6.

104. Krych AJ, Reardon P, Sousa P, Levy BA, Dahm DL, Stuart MJ. Clinical outcomes after revision meniscus repair. Arthroscopy. 2016 Sep;32(9):1831-7. Epub 2016 Apr 29.

105. Imade S, Kumahashi N, Kuwata S, Kadowaki M, Ito S, Uchio Y. Clinical outcomes of revision meniscal repair: a case series. Am J Sports Med. 2014 Feb;42 (2):350-7. Epub 2013 Nov 12.

106. Noyes FR, Barber-Westin SD. Long-term survivorship and function of meniscus transplantation. Am J Sports Med. 2016 Sep;44(9):2330-8. Epub 2016 May 20.

107. Bulgheroni E, Grassi A, Campagnolo M, Bulgheroni P, Mudhigere A, Gobbi A. Comparative study of collagen versus synthetic-based meniscal scaffolds in treating meniscal deficiency in young active population. Cartilage. 2016 Jan;7(1):29-38.

108. Wright JG. Revised grades of recommendation for summaries or reviews of orthopaedic surgical studies. J Bone Joint Surg Am. 2006 May;88(5):1161-2.