Online version at http://www.minervamedica.it

Minerva Ortopedica e Traumatologica 2017 June;68(2):81-90
DOI: 10.23736/S0394-3410.17.03805-X

REVIEW

An evidence-based approach to the diagnosis and treatment of meniscal root tears

Evan W. JAMES, Adam M. JOHANNSEN, Mark E. CINQUE, Jorge CHAHLA, Robert F. LAPRADE *

Steadman Philippon Research Institute, Vail, CO, USA

*Corresponding author: Robert F. LaPrade, Complex Knee and Sports Medicine Surgery, The Steadman Clinic, Steadman Philippon Research Institute, 181 W. Meadow Drive, Suite 400, Vail, Colorado 81657, USA. E-mail: rlaprade@thesteadmanclinic.com

ABSTRACT

The purpose of this review was to summarize recent advances in the diagnosis and treatment of meniscus root tears. Over the past decade, meniscal root tears have become increasingly recognized as a significant source of pain and disability. Meniscal root tears are often caused by chronic degenerative changes or acute trauma to the knee. When left untreated, root tears lead to meniscal extrusion, increased contact pressures and decreased contact areas on the articular cartilage, and rapidly progressive osteoarthritis. Meniscal root repairs may be performed in active individuals with mild to no osteoarthritis. Biomechanical studies have shown that anatomic root repairs result in decreased contact stresses and increased contact areas on the articular cartilage. While multiple root repair techniques have been described, the authors' preferred technique is a two tunnel transtibial pullout repair that allows for reduction of the root under direct arthroscopic visualization. Short and mid-term outcome studies show improvement in pain and function. Additional studies are needed to investigate the long-term outcomes, particularly with respect to the slowing of the progression of knee osteoarthritis, in patients following meniscal root repair.

(*Cite this article as*: James EW, Johannsen AM, Cinque ME, Chahla J, LaPrade RF. An evidence-based approach to the diagnosis and treatment of meniscal root tears. Minerva Ortop Traumatol 2017;68:81-90. DOI: 10.23736/S0394-3410.17.03805-X)

Key words: Menisci, tibial - Ligaments - Osteoarthritis, knee.

The meniscal roots have garnered increased scientific interest in recent years due to better understanding of their anatomy and critical function in knee biomechanics. Menisci are crescent shaped triangular fibrocartilaginous structures, which contain longitudinal fibers that allow for significant force dissipation when the knee joint is loaded. The anterior and posterior meniscal roots serve as anchors to distribute the axial force from the tibiofemoral joint to the tibial plateau through meniscal hoop stresses.[1, 2] Each meniscus has anterior and posterior root attachments.[3, 4] Prior research has quantitatively and qualitatively described the anatomic relationships of the root attachments and their importance to knee kinematics.[1, 3, 5] Johannsen *et al.* reported that the medial meniscus posterior root was located 8 mm anteromedial from the margin of the PCL, and 1 cm posterior to the apex of the medial tibial eminence (Figure 1). The lateral meniscus posterior root was a broad insertion 4 mm medial and 1.5 mm posterior to the lateral tibial eminence apex, and 12.7 mm anterior to the PCL margin.[3] The anterior meniscal roots have been described in detail.[6] The anteromedial meniscal root is located 27 mm lateral and distal to the tibial tuberosity and 27.5 mm directly posterior from the medial tibial eminence apex (Figure 2). The anterolateral

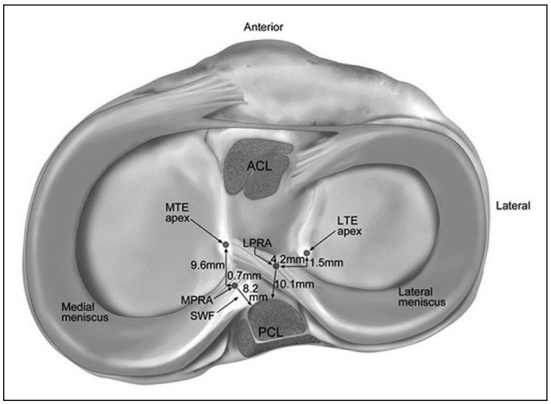

Figure 1.—Anatomy of posterior roots.
MTE: medial tibial eminence; LTE: lateral tibial eminence; MPRA: medial posterior root attachment; LPRA: lateral posterior root attachment; SWF: shiny white fibers of medial meniscus; PCL: posterior cruciate ligament; ACL: anterior cruciate ligament.

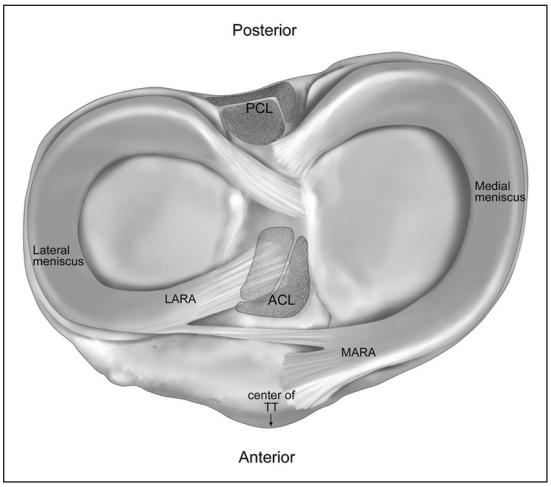

Figure 2.—Anatomy of anterior meniscal roots.
LARA: lateral anterior root attachment; MARA: medial anterior root attachment; ACL: anterior cruciate ligament; PCL: posterior cruciate ligament; TT: tibial tuberosity.

meniscus root was 14 mm anteromedial from the apex of the lateral tibial eminence and 5 mm anterolateral from the center of the ACL footprint. However, it has been well described that the anterolateral meniscus root has supplementary fibers that overlap with the ACL footprint.

Several studies have determined the importance of the meniscus roots on the function of the meniscus and kinematic knee forces. Padalecki *et al.* showed that a complete medial meniscus posterior radial root tears resulted in increased mean contact pressure on the medial compartment, and decreased the functional contact area.[2] This point loading of the medial compartment can lead to chondral damage and earlier onset of osteoarthritis.[2] Allaire *et al.* showed that a complete posterior medial meniscus root tear was functionally similar to a total medial meniscectomy.[1] Research has demonstrated that the meniscofemoral ligaments provide additional stability to the posterolateral root, and therefore isolated injuries to the posterior root of the lateral meniscus are not as detrimental to joint contact forces. Joint pressures are more likely to increase if both the posterior root of the lateral meniscus and the meniscofemoral ligaments are torn.[7] In addition, pathology at the anterior root has been shown to increase meniscal extrusion and has been linked to articular cartilage damage.[8] However, tears of the anterior roots are less frequent, and therefore are not as well understood in the literature.[4]

Etiology of meniscal root tears

Meniscal root tears are bimodal in their age distribution and their mechanism.[9] Younger patients are more likely to suffer meniscal root tears in an acute, traumatic event, while older patients may have a tear which occurs with minimal trauma. Injuries are often rotatory or in knee flexion, and are often accompanied by other ligamentous pathology. Research demonstrated that 60% of patients with a meniscal root tear had a concomitant ACL tear. Lateral meniscus root tears were 10 times more likely occur with an ACL tear than medial meniscus posterior root tears.[10] Medial meniscus root tears were 6 times more likely to have chondral defects.[10] Other studies have demonstrated that medial meniscus root tears were more likely to happen in patients with varus alignment and were associated with Kellgren-Lawrence grade 2 or higher chondral damage. Hwang *et al.* also demonstrated a relationship between medial meniscus root tears and increased age and BMI.[11]

Diagnosis

Proper diagnosis is critical to ensuring a good outcome in meniscal root tears. The clinical history and physical exam may be unreliable, because the symptoms of meniscal body injury are often different from meniscal root pathology. For example, prior research has demonstrated that only 10-15% of posterior root medial meniscus tear patients report their knee locking or giving way.[12] In addition, up to 70% of patients cannot recall a serious inciting event or major knee injury.[13] Physical examination is only moderately effective in diagnosis. Pain in deep knee flexion (posterior tears), a positive McMurray's test, and a palpable meniscal extrusion, have positive findings in 50-60% of root tear patients. Seil *et al.* reports a specific maneuver for posteromedial meniscal root tears. With the knee in full extension, a varus force is applied and anteromedial meniscal extrusion is visualized and palpated.[14] They reported that after root repair, the clinical sign returned to normal. These specific physical exam maneuvers have yet to gain widespread acceptance.

Magnetic resonance imaging (MRI) and arthroscopy remain the gold standards for the proper diagnosis of meniscal root tears. MRI in the past had only moderate efficacy in detecting meniscal root lesions, with previous studies demonstrating 70% specificity.[15] However, new diagnostic approaches using MRI have allowed for predicative values >90%.[16-18] Correlated findings on MRI include fluid accumulation in the meniscal roots, meniscal extrusion >3 mm from the tibial articular cartilage on coronal MRI, or absence of an identifiable meniscus on sagittal MRI, known as the ghost sign (Figure 3).[19] The variation in the reported predictive value of MRI is likely secondary to varying image quality and radiologist musculoskeletal experience, and these factors should be considered when making a diagnosis. Arthroscopy is the gold standard for diagnostic confirmation of a meniscal root tear at the time of surgical intervention. Anterior roots are clearly visualized through standard medial or lateral anterior portals. For optimal visualization of the posterior meniscal roots, some surgeons prefer a drive through intercondylar notch view [20] or accessory posteromedial or posterolateral accessory portals. Root integrity should be confirmed under tensile stress with a probe or other arthroscopic device.

Classification

Several classification schemes have been proposed to characterize tears at the anterior and posterior roots of the medial and lateral menisci. The goal of these classification schemes is generally to improve communication among surgeons and across centers, guide treatment decisions, and improve reporting of outcomes based on tear type. Classification is typically performed either during review of

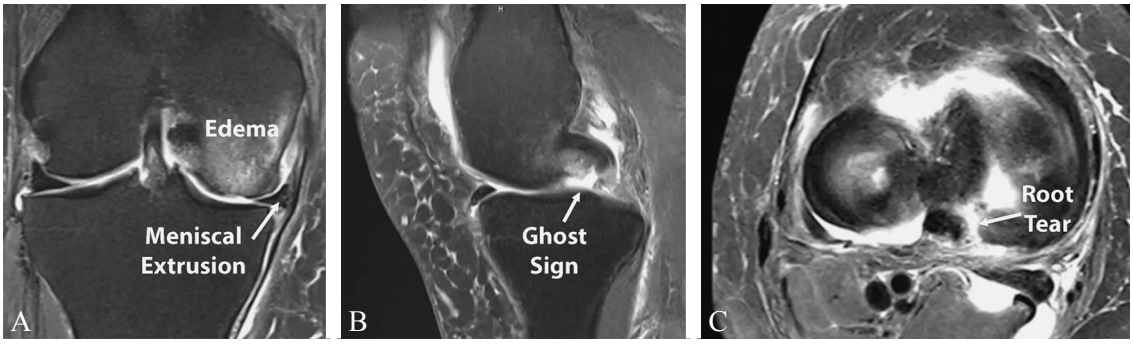

Figure 3.—Magnetic resonance image (MRI) demonstrating a postern horn medial meniscal root tear. A) Coronal MRI showing medial femoral condyle bone bruise and medial meniscus extrusion; B) sagittal MRI showing missing medial meniscus density and increased signal at the medial meniscal root attachment site; C) axial MRI showing medial meniscal root tear.

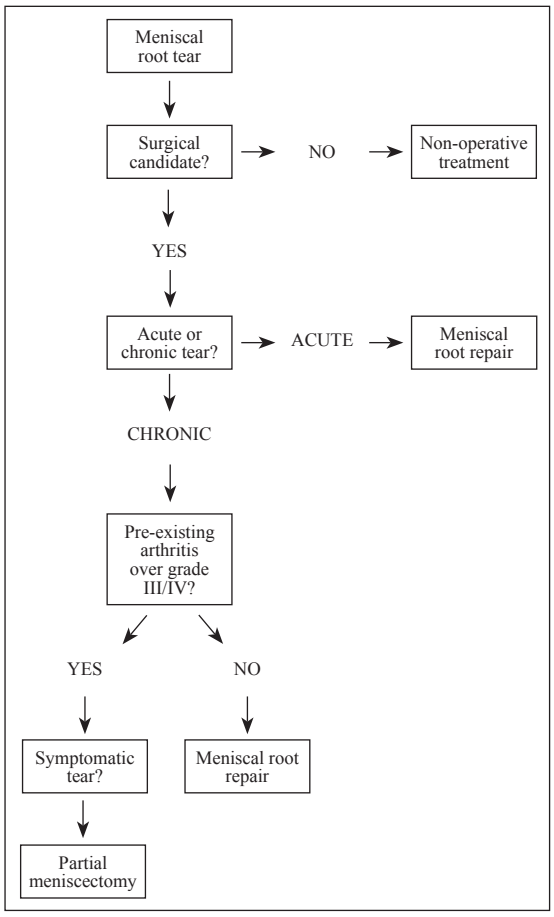

Figure 4.—Meniscal root tear treatment algorithm.

a MRI series or during arthroscopy. In a retrospective review of 419 knee MRIs, Choi *et al.* proposed a classification scheme for lesions of the posterior medial meniscus root attachment.[21] The scheme divided pathology into one of three groups: degenerative, partial tear, and complete tear. Groups were further subdivided by tear pattern including radial or transverse in relation to the longitudinal axis of the meniscus. The location of failure was classified as entheseal (failure at the root-plateau junction), midsubstance (within the root), or transitional (at the junction between the root and posterior horn of the medial meniscus). The boundary of the posterior meniscus root was defined as all root lateral to the inflection point on the medial tibial plateau when viewed in a coronal imaging plane. Bin *et al.* proposed a classification scheme for posterior medial meniscus root tears based on the degree of displacement at the tear site. Tears were divided into three groups: nondisplaced, overlapped, and widely displaced types.[22] The authors found that absolute extrusion of patients with nondisplaced or overlapped tears was significantly less than in the widely displaced group. Nguyen *et al.*[23] proposed a classification scheme for posterior meniscal root tears based on tear pattern, which included horizontal, longitudinal, radial, root, complex, displaced, and bucket-handle tears.

A classification scheme proposed by LaPrade *et al.* can be used to characterize tears of the anterior and posterior roots of the medial and lateral menisci.[4] Tears are divided into five subtypes: type 1, partial stable root tear; type 2, complete radial tear within 9 mm of the bony root attachment; type 3, bucket-handle tear with root detachment; type 4, complex oblique or longitudinal tear with complete disruption of the root attachment; and type 5, bony avulsion fracture of the root attachment site. Additionally, a variant tear type was defined for the posterior lateral meniscal root based on the integrity of the meniscofemoral ligament(s). Intact meniscofemoral ligament(s) were thought to confer a degree of stability to the root attachment even when the root attachment was torn, which has subsequently been validated in cadaveric biomechanical testing.[7] While to date no classification scheme has emerged as the gold standard, these schemes have nonetheless proved useful, particularly with respect to reporting outcomes.[24]

Non-operative treatment

Non-operative management of meniscal root tears is reserved for patients who are poor surgical candidates (comorbidities or advanced age), have moderate to severe osteoarthritis (Kellgren-Lawerence > grade 2) or asymptomatic chronic meniscal root tears (Figure 4). Non-operative management may also be indicated in older patients who may be unable to perform the intensive rehabilitation

program required following root repair. There have been several recent studies examining the outcomes of non-operative treatment of meniscal root tears. A study by Neogi *et al.* followed 37 patients with a medial meniscus posterior root tear identified on MRI and grade 1-2 osteoarthritis who were treated with a short course of analgesics and physical therapy.[25] The physical therapy consisted of a 12-week supervised program followed by a home exercise regimen. Patients were evaluated with subjective outcomes scores and imaging. Patients demonstrated an initial improvement in Lysholm score, Tegner Activity Scale, and visual analog scale that peaked at 6 months followed by a decline. Furthermore, the median Kellgren-Lawrence grade of osteoarthritis progressed from a 1 at the initial visit to a 2 at a mean follow-up of 35 months (range, 26-49 months). These results suggest that analgesia and physical therapy may provide temporary improvements in pain and function but ultimately fail to prevent progression of osteoarthritis. Lim *et al.* reviewed 30 patients with medial meniscus root tears treated with non-steroid anti-inflammatory (NSAID) drugs for 8-12 weeks and supervised physical therapy twice a week, for eight weeks. The authors reported improved patient reported outcome scores at 12 months.[26] However, these scores progressively decreased but did stay above baseline outcome scores. Other studies have highlighted the importance of physical activity to reduce knee pain, improve muscle strength, and increase quality of life in non-operative management of root tears.[27-29] Herrlin *et al.* reported that physical exercise three times a week during a four month period could lead to greater than 35% improvement of knee function.[27] Taking these findings together, non-operative measures such as physical therapy and NSAID use have mild to moderate relief for some patients, but likely do not affect the rate of arthritis progression and treatment effectiveness declines with time.

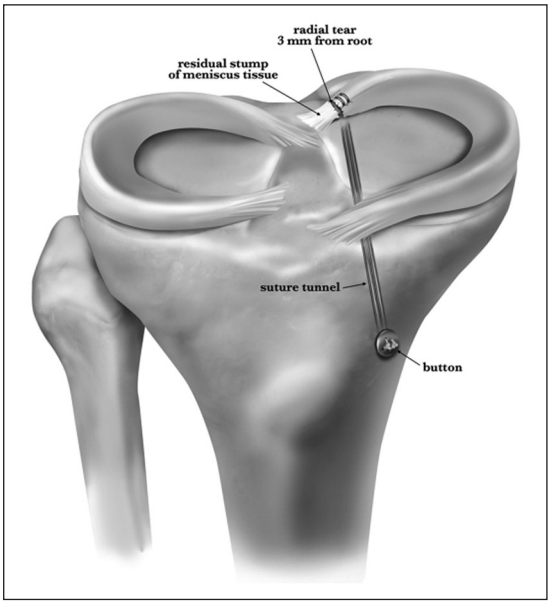

Figure 5.—Illustration of transtibial repair of a posterior horn medial meniscal root tear. Sutures are fixed on the anteromedial tibia with a fixation button.

Surgical treatment

Meniscal root tears are a subset of meniscal injuries that respond very well to surgical treatment. In an acute injury, a meniscal root tear may be identified by a bony avulsion of the meniscal root via plain radiography. Meniscal

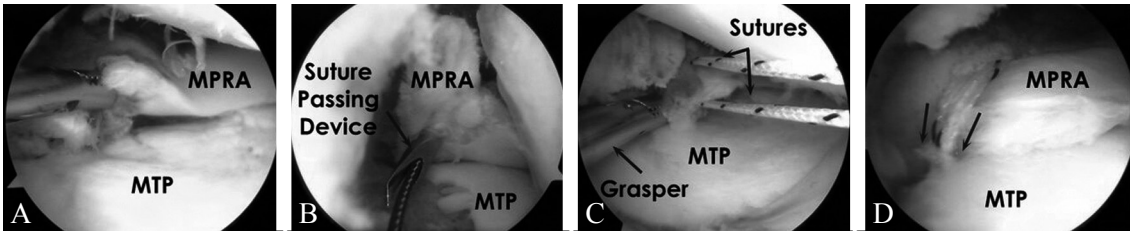

Figure 6.—Arthroscopic image sequence of a posterior medial meniscal root tear. A) Arthroscopic view of medial meniscal root tear; B) suture passing device showing suture passage through the medial posterior root attachment; C) sutures being passed over the medial meniscal root tear; D) final suture passage and completed repair of medial meniscal root tear.

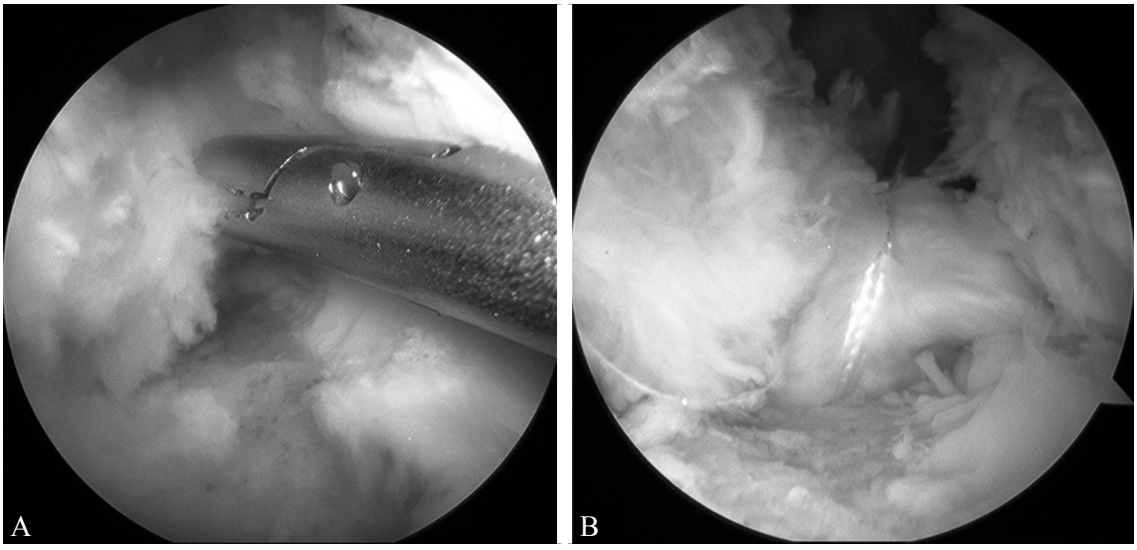

Figure 7.—Arthroscopic images of a left knee demonstrating (A) posterior lateral meniscus root tear and (B) final fixation of the root repair after pulling the sutures through the transtibial tunnels.

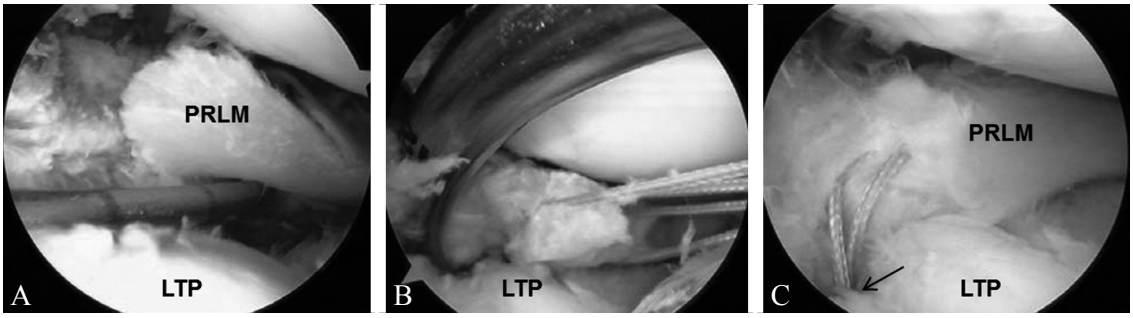

Figure 8.—Arthroscopic image sequence of posterior horn lateral meniscus repair. A) arthroscopic view of a torn posterior root of the lateral meniscus; B) arthroscopic view of sutures being passed over the root tear; C) arthroscopic image of sutures being pulled through the tibial tunnels, fixing the root tear.

root tears can also be identified arthroscopically by probing a meniscal tear and tracking it back to the root attachment of the affected meniscus. If a meniscal root tear is identified using any of these methods, surgical meniscal root repair is indicated.

Surgical repair of meniscal root repairs has been well studied in the literature. Currently, there are two main repair techniques. The first technique is the transtibial pullout repair technique. This technique can be used for medial (Figures 5, 6) or lateral (Figures 7, 8) meniscal root repairs. Meniscal root injuries are accessed via medial and lateral parapatellar arthroscopic portals. Additionally, an anterolateral portal can be utilized for suture passage.[19] Using an aiming device to place a guide pin through the tibial attachment of the medial or lateral posterior meniscal root, a transtibial tunnel is reamed over the guide pin.[2, 30] There have been a number of studies that have attempted to identify the ideal tunnel size. However, we recommend a two tunnel repair because this allows for the meniscus to be reapproximated best against the tibia. Number two non-absorbable sutures are then passed in a superior-to-inferior direction through the meniscal root, shuttled through the transtibial tunnels and secured over the anterior tibial cortex.[2] Our experience supports cortical button fixation because it is less invasive and decreases the risk of

symptomatic hardware seen with screw and washer fixation.

Recent studies have demonstrated higher ultimate failure with complex fixation methods.[31, 32] However, because as little as 3 mm of meniscal translation can alter meniscal function, we believe it is paramount to ensure secure root fixation to prevent future meniscal symptoms. To best ensure secure root fixation we recommend use of the two simple suture technique[32] because of it allows for accurate suture placement and is less technically complex.

The second meniscal root repair technique utilizes a suture anchor repair. This technique most frequently involves an all-inside repair using one suture anchor with two sutures secured in cortical bone at the anatomic meniscal root attachment site.[13, 32, 33] This procedure is performed using standard anteromedial and lateral portals in addition to a posteromedial portal that allows for more vertical placement of suture anchors, while avoiding interference from the medial femoral condyle. The suture anchor is secured to the native attachment of the posteromedial meniscal root. Sutures are then passed through the substance of the root and shuttled between portals. The sutures are then arthroscopically tied using a knot while an assistant provides adequate tension on the suture to ensure complete repair. [13, 32, 33] This technique is usually described in patients with a grade III MCL tear which allows access to the posteromedial root attachment.

Several recent studies have noted the superiority of the transtibial two-tunnel technique in anatomically restoring the attachments of the posterior root and restoring contact pressures to near normal values. Furthermore, these studies have demonstrated restoration of near normal contact pressures and hoop stresses following the double tunnel repair technique.[2, 4, 19, 29] Kim *et al.* performed a systematic review compromised of level III and IV studies and reported good to excellent results after arthroscopic transtibial pullout repair for medial meniscal root tears.[32] Furthermore, Kim *et al.* reported significantly less meniscal extrusion on second look arthroscopy in their meniscal root repair patients when compared to their partial meniscectomy patients. However, these findings are limited by the fact that the study included patients with severe osteoarthritis and a high average age (59 years).

Rehabilitation

There is a paucity of literature comparing and describing post-operative rehabilitation protocols following meniscal root repair. Mueller *et al.* proposed a linear rehabilitation protocol that focused on gradual loading of the meniscus root repair construct, which has been summarized in Table I.[34] In this protocol, patients were non-weight bearing for the first 6 weeks followed by gradual progressive increase in weight bearing for the next 2-3 weeks. Subsequent phases of rehabilitation focused on endurance followed by strength training and ended with agility drills and return to sport clearance testing. Return to sport should only occur after careful evaluation by a physician and clearance of functional testing such as the Vail sports test.[35]

TABLE I.—*Rehabilitation timeline as described by Mueller* et al.[34]

A periodized rehabilitation program following meniscus root repair		
Phase	Timeframe	Activities
Protection	Weeks 0-6	NWB, passive ROM 0-90 degrees, stretching, core strengthening
Weight-bearing	Weeks 7-9	Progress weight bearing status, calf raises, double leg squats, stationary bikes
Endurance	Weeks 10-15	Double leg squats, static lunges, stationary bike with resistance
Strength	Weeks 16-22	Single-leg squats, step ups, stationary bike with resistance
Plyometrics and return to sport	Weeks 22+	Agility drills, cutting activities, jumping training, running progression, return to sport testing

NWB: non-weight bearing; ROM: range of motion.

Outcomes

Multiple studies have reported short- and mid-term outcomes following posterior medial and lateral meniscus root repair. A meta-analysis by Chung *et al.* compiled clinical and radiographic outcomes following medial meniscus posterior root repairs.[36] Eight studies satisfied their inclusion and exclusion criteria. This meta-analysis compared pre-operative to postoperative differences in Lysholm scores, progression of Kellgren-Lawrence grade, progression of Outerbridge classification, and meniscus extrusion. Analysis of pooled data revealed a significant improvement in Lysholm scores. Radiographic progression of Kellgren-Lawrence osteoarthritis was identified in 10.6% [5.3-20.3%, 95% CI] of patients with a repair and in 17.3% [11.5-25.0%, 95% CI] of patients with a meniscectomy based on the Outerbridge classification. Together these results suggest that posterior medial meniscus root repair successfully delays progression of cartilage injury in 8 to 9 out of 10 patients who undergo repair. It is important to note that to date most of the outcome studies have reported data for posterior medial meniscus root repairs only. Compared to outcomes for posterior medial meniscus root tears, outcomes for posterior lateral meniscus root tears remain under reported.[24, 37, 38]

Another source of significant debate is whether root repairs should be performed in older patients including those with little to no evidence of osteoarthritis. Historically, these patients would have undergone a partial or subtotal meniscectomy. LaPrade *et al.* recently reported outcomes on a series of 50 knees in 49 patients.[24] Outcome scores and failure rates were compared based on patient age (less than or greater than 50 years of age) and meniscus laterality. There were 15 patient in the ≥50 years old cohort (mean age 58.0) and 35 patients <50 years old (mean age 29.9). Results showed no significant difference in failure rate or subjective outcome measures based on patient age or meniscus tear laterality. As patients demand to remain active later in life, additional study is required to further refine which older patients may benefit most from meniscus root repair versus meniscectomy or nonoperative treatments.

Complications

Intra-operative and post-operative complications associated with posterior meniscus root repair have been documented in the literature. Intra-operative complications include tunnel convergence with concomitant anterior or posterior cruciate ligament tibial tunnels, malreduction of the meniscus root to a non-anatomic position, and posterior neurovascular compromise. In addition, iatrogenic injury to the anterior cruciate ligament is possible when preparing the tibial attachment side, particularly for anterior root tears of the lateral meniscus. Iatrogenic injury to the posterior cruciate ligament is also possible when performing a posterior medial or lateral root repair. Other perioperative complications include surgical site infection, deep vein thrombosis, attenuation of the suture repair construct, suture pullout, and knee arthrofibrosis. Over longer time scales, progression of osteoarthritis and re-tearing may also occur.

Conclusions

Significant research interest regarding the diagnosis and treatment of meniscus root tears in recent years has led to improved patient outcomes. Patients with meniscus root tears treated non-operatively often lead to increased contact pressures on articular cartilage and the development of rapidly progressive osteoarthritis. Patients with little to no osteoarthritis and evidence of a meniscal root tear on MRI are candidates for repair. While multiple techniques for meniscus root repair have been reported in the literature, we advocate for transtibial pullout repair utilizing a two-tunnel approach. Early- and mid-term outcomes following meniscus root repair have been reported which show decreased pain and improved function and arrest of progression of osteoar-

thritis in most patients. Additional studies are needed to assess the longevity of repair constructs and integrity of the articular cartilage at long-term follow-up.

References

1. Allaire R, Muriuki M, Gilbertson L, Harner CD. Biomechanical consequences of a tear of the posterior root of the medial meniscus. Similar to total meniscectomy. J Bone Joint Surg Am 2008;90:1922-31.
2. Padalecki JR, Jansson KS, Smith SD, Dornan GJ, Pierce CM, Wijdicks CA, *et al.* Biomechanical consequences of a complete radial tear adjacent to the medial meniscus posterior root attachment site: in situ pull-out repair restores derangement of joint mechanics. Am J Sports Med 2014;42:699-707.
3. Johannsen AM, Civitarese DM, Padalecki JR, Goldsmith MT, Wijdicks CA, Laprade RF. Qualitative and quantitative anatomic analysis of the posterior root attachments of the medial and lateral menisci. Am J Sports Med 2012;40:2342-7.
4. Laprade CM, James EW, Cram TR, Feagin JA, Engebretsen L, Laprade RF. Meniscal root tears: a classification system based on tear morphology. Am J Sports Med 2015;43:363-9.
5. Ellman MB, Laprade CM, Smith SD, Rasmussen MT, Engebretsen L, Wijdicks CA, *et al.* Structural Properties of the Meniscal Roots. Am J Sports Med 2014;42:1881-7.
6. Laprade CM, Ellman MB, Rasmussen MT, James EW, Wijdicks CA, Engebretsen L, *et al.* Anatomy of the anterior root attachments of the medial and lateral menisci: a quantitative analysis. Am J Sports Med 2014;42:2386-92.
7. Geeslin AG, Civitarese D, Turnbull TL, Dornan GJ, Fuso FA, Laprade RF. Influence of lateral meniscal posterior root avulsions and the meniscofemoral ligaments on tibiofemoral contact mechanics. Knee Surg Sports Traumatol Arthrosc 2016;24:1469-77.
8. Costa CR, Morrison WB, Carrino JA. Medial meniscus extrusion on knee MRI: is extent associated with severity of degeneration or type of tear? AJR Am J Roentgenol 2004;183:17-23.
9. Papalia R, Vasta S, Franceschi F, D'adamio S, Maffulli N, Denaro V. Meniscal root tears: from basic science to ultimate surgery. Br Med Bull 2013;106:91-115.
10. Matheny LM, Ockuly AC, Steadman JR, Laprade RF. Posterior meniscus root tears: associated pathologies to assist as diagnostic tools. Knee Surg Sports Traumatol Arthrosc 2015;23:3127-31.
11. Hwang BY, Kim SJ, Lee SW, Lee HE, Lee CK, Hunter DJ, *et al.* Risk factors for medial meniscus posterior root tear. Am J Sports Med 2012;40:1606-10.
12. Lee DW, Ha JK, Kim JG. Medial meniscus posterior root tear: a comprehensive review. Knee Surg Relat Res 2014;26:125-34.
13. Kim JH, Chung JH, Lee DH, Lee YS, Kim JR, Ryu KJ. Arthroscopic suture anchor repair versus pullout suture repair in posterior root tear of the medial meniscus: a prospective comparison study. Arthroscopy 2011;27:1644-53.
14. Seil R, Duck K, Pape D. A clinical sign to detect root avulsions of the posterior horn of the medial meniscus. Knee Surg Sports Traumatol Arthrosc 2011;19:2072-5.
15. Ozkoc G, Circi E, Gonc U, Irgit K, Pourbagher A, Tandogan RN. Radial tears in the root of the posterior horn of the medial meniscus. Knee Surg Sports Traumatol Arthrosc 2008;16:849-54.
16. De Smet AA, Mukherjee R. Clinical, MRI, and arthroscopic findings associated with failure to diagnose a lateral meniscal tear on knee MRI. AJR Am J Roentgenol 2008;190:22-6.
17. Choi SH, Bae S, Ji SK, Chang MJ. The MRI findings of meniscal root tear of the medial meniscus: emphasis on coronal, sagittal and axial images. Knee Surg Sports Traumatol Arthrosc 2012;20:2098-103.
18. Laprade RF, Ho CP, James E, Crespo B, Laprade CM, Matheny LM. Diagnostic accuracy of 3.0 T magnetic resonance imaging for the detection of meniscus posterior root pathology. Knee Surg Sports Traumatol Arthrosc 2015;23:152-7.
19. Bhatia S, Laprade CM, Ellman MB, Laprade RF. Meniscal root tears: significance, diagnosis, and treatment. Am J Sports Med 2014;42:3016-30.
20. Lubowitz JH, Rossi MJ, Baker BS, Guttmann D. Arthroscopic visualization of the posterior compartments of the knee. Arthroscopy 2004;20:675-80.
21. Choi JY, Chang EY, Cunha GM, Tafur M, Statum S, Chung CB. Posterior medial meniscus root ligament lesions: MRI classification and associated findings. AJR Am J Roentgenol 2014;203:1286-92.
22. Bin SI, Jeong TW, Kim SJ, Lee DH. A new arthroscopic classification of degenerative medial meniscus root tear that correlates with meniscus extrusion on magnetic resonance imaging. Knee 2016;23:246-50.
23. Nguyen JC, De Smet AA, Graf BK, Rosas HG. MR imaging-based diagnosis and classification of meniscal tears. Radiographics 2014;34:981-99.
24. Laprade RF, Matheny LM, Moulton SG, James EW, Dean CS. Posterior Meniscal Root Repairs: Outcomes of an Anatomic Transtibial Pull-Out Technique. Am J Sports Med 2016;*In Press*.
25. Neogi DS, Kumar A, Rijal L, Yadav CS, Jaiman A, Nag HL. Role of nonoperative treatment in managing degenerative tears of the medial meniscus posterior root. J Orthop Traumatol 2013;14:193-9.
26. Lim HC, Bae JH, Wang JH, Seok CW, Kim MK. Non-operative treatment of degenerative posterior root tear of the medial meniscus. Knee Surg Sports Traumatol Arthrosc 2010;18:535-9.
27. Herrlin S, Hallander M, Wange P, Weidenhielm L, Werner S. Arthroscopic or conservative treatment of degenerative medial meniscal tears: a prospective randomised trial. Knee Surg Sports Traumatol Arthrosc 2007;15:393-401.
28. Mangione KK, Mccully K, Gloviak A, Lefebvre I, Hofmann M, Craik R. The effects of high-intensity and low-intensity cycle ergometry in older adults with knee osteoarthritis. J Gerontol A Biol Sci Med Sci 1999;54:M184-90.
29. Moon HK, Koh YG, Kim YC, Park YS, Jo SB, Kwon SK. Prognostic factors of arthroscopic pull-out repair for a posterior root tear of the medial meniscus. Am J Sports Med 2012;40:1138-43.
30. Laprade CM, Jansson KS, Dornan G, Smith SD, Wijdicks CA, Laprade RF. Altered tibiofemoral contact mechanics due to lateral meniscus posterior horn root avulsions and radial tears can be restored with in situ pull-out suture repairs. J Bone Joint Surg Am 2014;96:471-9.
31. Kopf S, Colvin AC, Muriuki M, Zhang X, Harner CD. Meniscal root suturing techniques: implications for root fixation. Am J Sports Med 2011;39:2141-6.
32. Feucht MJ, Kuhle J, Bode G, Mehl J, Schmal H, Sudkamp NP, *et al.* Arthroscopic Transtibial Pullout Repair for Posterior Medial Meniscus Root Tears: A Systematic Review of Clinical, Radiographic, and Second-Look Arthroscopic Results. Arthroscopy 2015;31:1808-16.

33. Jung YH, Choi NH, Oh JS, Victoroff BN. All-inside repair for a root tear of the medial meniscus using a suture anchor. Am J Sports Med 2012;40:1406-11.
34. Mueller BT, Moulton SG, O'brien L, Laprade RF. Rehabilitation Following Meniscal Root Repair: A Clinical Commentary. J Orthop Sports Phys Ther 2016;46:104-13.
35. Garrison JC, Shanley E, Thigpen C, Geary R, Osler M, Delgiorno J. The reliability of the vail sport test as a measure of physical performance following anterior cruciate ligament reconstruction. Int J Sports Phys Ther 2012;7:20-30.
36. Chung KS, Ha JK, Ra HJ, Kim JG. A meta-analysis of clinical and radiographic outcomes of posterior horn medial meniscus root repairs. Knee Surg Sports Traumatol Arthrosc 2016;24:1455-68.
37. Laprade CM, James EW, Laprade RF. A Modified Transtibial Pull-Out Repair for Posterior Root Avulsions of the Lateral Meniscus with Concomitant Anterior Cruciate Ligament Reconstruction. JBJS Case Connector 2014;4:e96.
38. Lee JH, Lim YJ, Kim KB, Kim KH, Song JH. Arthroscopic pullout suture repair of posterior root tear of the medial meniscus: radiographic and clinical results with a 2-year follow-up. Arthroscopy 2009;25:951-8.

Conflicts of interest.—The authors certify that there is no conflict of interest with any financial organization regarding the material discussed in the manuscript.