Anatomic posterior cruciate ligament reconstruction: State of the Art

Jorge Chahla,[1] Richard von Bormann,[2] Lars Engebretsen,[3] Robert F LaPrade[1,4]

[1]Steadman Philippon Research Institute, Vail, Colorado, USA
[2]Cape Town Sports & Orthopaedic Clinic, Cape Town, South Africa
[3]Orthopedic Department, Oslo University Hospital, Oslo, Norway
[4]The Steadman Clinic, Vail, Colorado, USA

Correspondence to
Dr Robert F LaPrade, Steadman Philippon Research Institute, The Steadman Clinic, 181 West Meadow Drive, Suite 400, Vail, CO 81657, USA; drlaprade@sprivail.org

Received 28 June 2016
Revised 18 July 2016
Accepted 19 July 2016
Published Online First 17 August 2016

ABSTRACT

The posterior cruciate ligament (PCL) is recognised to be the main posterior stabiliser of the knee. PCL injuries are most commonly associated with concurrent ligament injuries and also with a high prevalence of chondral and meniscal injuries. Recent evidence of the accuracy of the stress radiographs as an objective diagnostic tool has improved assessment of surgical indications and postoperative assessment. Acute, isolated PCL injuries (grades I and II) can be treated non-operatively. However, in cases of acute grade III PCL injuries or when concurrent multiligament injuries or repairable meniscal body/root tears are present, surgery is indicated. Anatomic single-bundle PCL reconstruction (PCLR), focusing on reconstruction of the larger anterolateral bundle, is the most commonly performed procedure. Owing to the residual posterior and rotational tibial instability after a single-bundle reconstruction procedure and the inability to restore normal knee kinematics, an anatomic double-bundle PCLR has been proposed in an effort to recreate the native PCL footprint more closely and to restore normal knee kinematics. The purpose of this article is to review the specific principles of PCL anatomy, biomechanics, injury diagnosis and treatment options, with a focus on arthroscopic double-bundle PCLRs.

INTRODUCTION

The posterior cruciate ligament (PCL) is considered an extra-articular, extrasynovial structure which acts as the primary restraint to posterior tibial translation. Moreover, it is a secondary restraint to internal rotation, predominantly between 90° and 120° of flexion.[1] It is composed by two bundles that were previously thought to function independently: the anterolateral bundle (ALB) was believed to function predominantly in flexion and the posteromedial bundle (PMB) mainly in extension.[2 3] However, recent biomechanical studies have found a codominant relationship between these two bundles, in the anteroposterior and rotational axes.[4 5]

Concurrent ligament injuries are commonly associated with PCL injuries.[6] Furthermore, there is a high prevalence of concomitant chondral and meniscal injuries.[6] Isolated PCL tears constitute an infrequent knee injury with an annual incidence of 2 per 100 000 persons.[7] Of note, this subset of patients are at almost a sixfold increased risk of developing osteoarthritis (OA).[7]

PCL reconstruction (PCLR) has been shown to produce more satisfactory and consistent stability when compared to the non-operative group in a systematic review.[8] Although improvements in single-bundle PCLR (SB PCLR) concerning tunnel location, fixation type and optimal graft fixation angles have been attained, biomechanical studies have reported residual laxity after a single-bundle procedure.[9] However, comparing outcomes between single-bundle and double-bundle PCLRs, results are problematic because of usage of different grafts, tensioning techniques and tunnel positions.[10]

Traditionally, outcomes of PCLR have produced less predictable results when compared to those for anterior cruciate ligament (ACL) tears.[11 12] This might be due to a failure to anatomically reconstruct functional PCL bundles and surgical techniques that disrupt the vastus medialis muscle. The purpose of this article is to review specific focused principles of PCL anatomy, biomechanics, injury diagnosis and treatment options, with an emphasis on endoscopic double-bundle PCLR.

ANATOMY

The PCL is an extrasinovial structure that inserts in the superolateral aspect of the medial femoral condyle in close proximity to the articular cartilage margin of the femur. It has a vertical orientation until its distal attachment onto a depression on the posterior aspect of the tibia.[2 13] The PCL is 32–38 mm long, with an average width of 13 mm.[2 13] The central part of the ligament is the smallest, constituting approximately one-third the areas of the femoral and tibial attachments.[14]

The PCL can be divided into two bundles based on the anatomic direction of the fibres and tensioning patterns and their function: a larger anterolateral and a smaller PMBs named according to their femoral attachment.[2 15 16] Additional structures can be present in this complex, and are the anterior (ligament of Humphrey) and/or the posterior (ligament of Wrisberg) meniscofemoral ligaments.[14 17] Anatomic studies have described that at least one is present in 95% and both ligaments only in 60% of cadaver specimens.[18] The ALB acts as the primary restraint to posterior translation and is under the greatest tension when the knee is at 90° of flexion.[19–22] It is approximately two times bigger than the PMB in cross-sectional area.[14 23] The PMB is the main structure ensuring posterior translation stability near full extension and functions as a secondary restraint to knee rotation.[1 24] Thus, tension changes reciprocally during knee range of motion between both bundles, without exhibiting true isometry[25] (figure 1).

BIOMECHANICS

The strongest bundle of the PCL is the ALB. The mean ultimate load to failure of the ALB is 1120 ±362 N, which is almost three times more than the

To cite: Chahla J, von Bormann R, Engebretsen L, *et al*. *JISAKOS* 2016;**1**:292–302.

Key articles

- Anderson CJ, Ziegler CG, Wijdicks CA, *et al*. Arthroscopically pertinent anatomy of the anterolateral and posteromedial bundles of the posterior cruciate ligament. *J Bone Joint Surg Am* 2012;94:1936–45.
- Kennedy NI, Wijdicks CA, Goldsmith MT, *et al*. Kinematic analysis of the posterior cruciate ligament, part 1: the individual and collective function of the anterolateral and posteromedial bundles. *Am J Sports Med* 2013;41:2828–38.
- Sekiya JK, Whiddon DR, Zehms CT, *et al*. A clinically relevant assessment of posterior cruciate ligament and posterolateral corner injuries. Evaluation of isolated and combined deficiency. *J Bone Joint Surg Am* 2008;90: 1621–27.
- Wijdicks CA, Kennedy NI, Goldsmith MT, *et al*. Kinematic analysis of the posterior cruciate ligament, part 2: a comparison of anatomic single- versus double-bundle reconstruction. *Am J Sports Med* 2013;41:2839–48.
- Jackman T, LaPrade RF, Pontinen T, *et al*. Intraobserver and interobserver reliability of the kneeling technique of stress radiography for the evaluation of posterior knee laxity. *Am J Sports Med* 2008;36:1571–76.
- Johannsen AM, Anderson CJ, Wijdicks CA, *et al*. Radiographic landmarks for tunnel positioning in posterior cruciate ligament reconstructions. *Am J Sports Med* 2013;41:35–42.
- Kennedy NI, LaPrade RF, Goldsmith MT, *et al*. Posterior cruciate ligament graft fixation angles, part 1: biomechanical evaluation for anatomic single-bundle reconstruction. *Am J Sports Med* 2014;42:2338–45.
- Kennedy NI, LaPrade RF, Goldsmith MT, *et al*. Posterior cruciate ligament graft fixation angles, part 2: biomechanical evaluation for anatomic double-bundle reconstruction. *Am J Sports Med* 2014;42:2346–55.
- Chahla J, Nitri M, Civitarese D, *et al*. Anatomic double-bundle posterior cruciate ligament reconstruction. *Arthrosc Tech* 2016;5:e149–56.
- Geeslin AG, LaPrade RF. Outcomes of treatment of acute grade-III isolated and combined posterolateral knee injuries: a prospective case series and surgical technique. *J Bone Joint Surg Am* 2011;93:1672–83.
- Qi YS, Wang HJ, Wang SJ, *et al*. A systematic review of double-bundle versus single-bundle posterior cruciate ligament reconstruction. *BMC Musculoskelet Disord* 2016;17:45.

mean ultimate load to failure of the PMB (419±128 N).[14] Previous studies reported near-normal knee kinematics when only the PMB was sectioned, and therefore, it has been suggested that the ALB was more relevant, and consequently, a traditional single-bundle reconstruction should be sufficient.[21 26] However, Kennedy *et al*[27] reported similar results when the ALB was sectioned and the PMB was left intact, demonstrating that both bundles have a codominant functional relationship supporting the idea that both bundles need to be reconstructed to restore near-native knee kinematics.

Biomechanical studies have suggested that the PCL is a non-isometric structure with uneven tension on the individual bundles throughout the range of knee motion angles.[25] The PCL length increases as it flexes from 0° to 90°,[4 28–30] remains relatively constant from 105° to 120° and then decreases from 120° to 135°.[4 29] Furthermore, Ahmad *et al*[31] reported that the ALB becomes longer and more vertical as the knee flexes. Conversely, the PMB becomes shorter and more horizontal with progressive flexion. This orientation change places the restraining force vector of the PMB bundle in line to counteract posterior tibial translation at increasing flexion angles and vice versa with the ALB. Thus, these dynamic changes in length and orientation suggest that neither bundle is dominant in restraining posterior tibial translation throughout a full arc of knee motion.[12]

Finally, the PCL also provides rotational stability, especially at higher flexion angles.[27 32] Biomechanical studies demonstrated a key role of the PCL for internal rotation constraint at 90° of flexion and higher.[27 32] Specifically, the PMB is important in maintaining posterior translation stability across a full range of motion and rotational stability beyond 90° of flexion, signifying that SB PCLR that fails to address the PMB may not restore near-native posterior and rotational stability compared to a double-bundle technique.[27 32]

MECHANISM OF INJURY, INCIDENCE, DEMOGRAPHICS AND NATURAL HISTORY

Isolated PCL injury often occurs as a result of a dashboard injury, high force fall on flexed knee or hyperextension of the knee.[33] Multiligament injury, including PCL tears, is more likely when the trauma involves a rotational or valgus/varus stress.[33]

A recent epidemiologic study reported that the incidence of isolated PCL tears was 2 per 100 000 in the general population, being more common in male participants.[7] This number can be underestimated probably due to failing to recognise this lesion by the surgeon or the patient not consulting at the moment of the injury. However, the scarcity of isolated PCL tears makes the

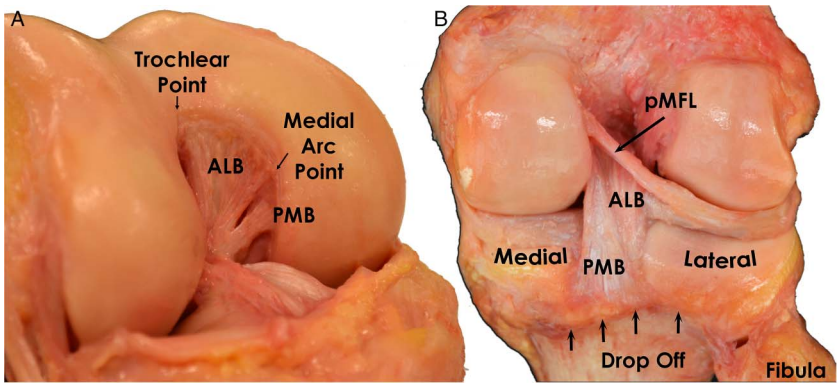

Figure 1 (A) Anteromedial view of a cadaveric knee demonstrating bony landmarks of each individual bundle that can be used arthroscopically to guide the anatomic placement of the tunnels. The ALB is located between the trochlear point and the medial arch point. The PMB lies below the medial arch point and 5 mm posterior to the cartilage. (B) Posterior view of a cadaveric right knee demonstrating bony and soft tissue landmarks of the PCL. ALB, anterolateral bundle; PCL, posterior cruciate ligament; PMB, posteromedial bundle; pMFL, posterior meniscofemoral ligament.

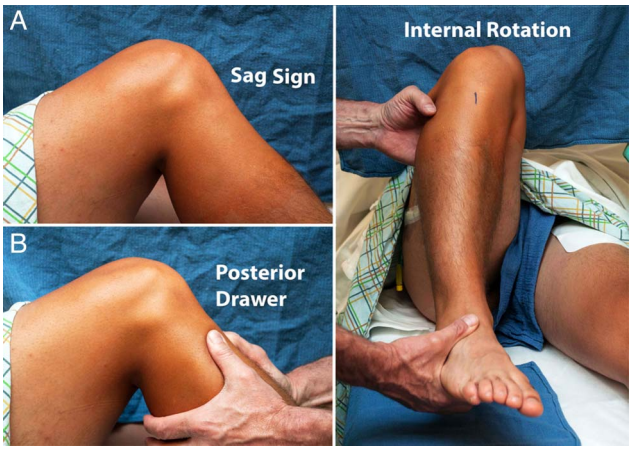

Figure 2 Examine under anaesthesia of the specific to assess for the PCL integrity. (A) The posterior sag, the posterior drawer and the supine internal rotation test. The posterior sag test is performed at 90° of hip and knee flexion and uses gravity to apply a posteriorly directed force to the tibia. The posterior sag of the tibia on the injured side is compared to the uninjured side. The posterior drawer can be performed at the same angle by applying a posterior force to the tibial tubercle and comparing the displacement with the contralateral side. Finally, internal rotation test is performed by assessing tibial internal rotation compared to the contralateral leg at various flexion angles. PCL, posterior cruciate ligament.

natural history and epidemiology of this injury challenging to study.[34]

PCL deficiency exposes the knee to abnormal kinematics and contact pressures in the medial compartment and the patellofemoral joint.[35] This increases the strain on the posterolateral knee structures, placing them at risk of subsequent injury.[36] In a 12-year follow-up study, patients with isolated PCL tears had a significantly higher likelihood (6.2 times) of symptomatic arthritis and a total knee arthroplasty (3.2 times) compared to individuals without PCL tears.

Moreover, Strobel *et al*[37] reported degenerative cartilage lesions of the medial femoral condyle in 77.8% of the cases and 46.7% of the patella in patients with PCL deficiency followed for >5 years after the index injury. Although studies with long follow-up reported that degenerative changes occur mainly in the medial and patellofemoral compartments,[38 39] Kim *et al*[40] were unable to define the overall prevalence, location or predictors of OA in a systematic review.

DIAGNOSIS

An important first step in defining treatment options is to address any concomitant pathology through an accurate physical examination and imaging methods (standard radiographs, varus and valgus[41–43] stress radiographs and MRI).

Common symptoms of a patient with an isolated PCL tear are diffuse knee pain, swelling or discomfort when the knee is highly flexed. A combined ligamentous injury should be suspected in higher energy mechanisms, severe pain or instability.[6] When evaluating a patient with a suspected PCL injury, it is important to evaluate the entire knee in terms of stability, nerve function and vascular status. With regards to specific tests that should be performed to determine the integrity of the PCL, the posterior drawer, posterior sag and quadriceps active tests, and the supine internal rotation test are the most frequently used[6] (figure 2).

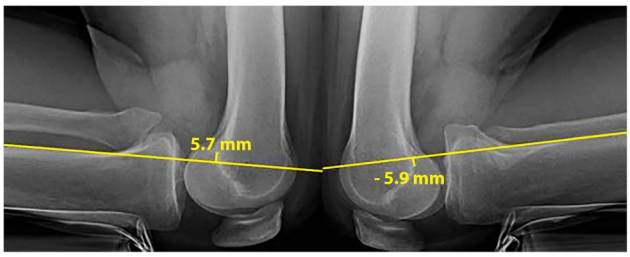

Figure 3 Comparative knee lateral stress radiographs. To compare the posterior tibial translation, a point is identified along the posterior tibial cortex 15 cm distal to the joint line. A line is then drawn from this point parallel to the posterior cortex, through the femoral condyles, and the most posterior point of Blumensaat's line is marked. A perpendicular line is drawn from that point to intersect the first line, and this distance is compared to the contralateral side. In this case, a 11.6 mm difference between both sides exists signifying a complete PCL tear. PCL, posterior cruciate ligament.

When potential posterior instability is noted in the physical examination, kneeling stress radiographs are an inexpensive, useful and reproducible adjunct to help objectively quantify posterior knee translation instability.[41] The magnitude of the posterior tibial translation can be assessed by stress radiographies performed by a device (Telos Device) applying a 150 N controlled force,[44 45] with a specially designed device applying 200 N[2] or with kneeling stress radiographs.[41] In this regard, Jung performed a comparative study between five different PCL stress methods (Telos device, hamstring contraction, kneeling view, gravity view and an axial view). The authors concluded that although kneeling resulted in a greater rotational error than Telos, it was an effective method for quantifying posterior tibial translation in a faster and less complicated manner.[46] Kneeling stress radiography allows for comparison of the amount of posterior displacement of the tibia on the femur between the injured and uninjured knees.[41] The diagnostic validated algorithm consists in: (1) 0–7 mm of side-to-side difference in posterior displacement constitutes a partial PCL tear, (2) 8–11 mm of an isolated PCL tear and (3) ≥12 mm of posterior translation means a combined PCL and posterolateral corner or posteromedial corner knee injury.[41] To accurately measure the posterior tibial translation, a point is identified along the posterior cortex 15 cm distal to the joint line. A line is then drawn from this point parallel to the posterior cortex, through the femoral condyles, and the most posterior point of Blumensaat's line is marked. A perpendicular line is drawn from that point to intersect the first line, and this distance is compared to the contralateral side (figure 3).

MRI is an important adjunct to the diagnosis because it has been found to have a sensitivity, specificity and accuracy of almost 100% for the diagnosis of acute PCL injuries.[6] It is essential for the assessment of associated pathology and concomitant ligamentous injuries. However, MRI is not so important in the evaluation of chronic PCL tears since the signal and shape can be restored in a chronic healed PCL tear on MRI; however, residual laxity can be present, and therefore, stress radiographs are strongly advocated to diagnose chronic PCL tears.

Validated outcome measures and classifications

Table 1 demonstrates the values of corresponding stress radiographs to the clinical findings to help to differentiate grade I–III PCL injuries.[47]

Table 1 Comparison of posterior drawer clinical findings versus objective kneeling radiographs validated posterior tibial translation values

Grade	Clinical finding with posterior drawer	Kneeling radiographs
I	0–5 mm PTT	0–7 mm PTT
II	5–10 mm PTT	8–11 mm PTT→complete PCL tear
III	>10 mm PTT; MTP posterior to MFC; posterior sag	≥12 mm PTT→combined injury

MFC, medial femoral condyle; MTP, medial tibial plateau; PCL, posterior cruciate ligament; PTT, posterior tibial translation.

Key issues of patient selection

- Isolated symptomatic acute grade III posterior cruciate ligament (PCL) tears.
- Combined reconstructions for multiligament lesions.
- Combined with repairable meniscal body or root tears in the acute setting.
- Acute, displaced PCL bony avulsion, surgical intervention is indicated.
- Chronic symptomatic PCL tears.

TREATMENT ALGORITHM

Several patient-specific factors should be considered to achieve a satisfactory result when treating a PCL injury. These include the presence of concomitant injuries (isolated vs combined), grade of PCL injury, setting (acute vs chronic), clinical presentation (asymptomatic vs pain or instability) and patient demands or activity level (athletic vs sedentary).[48] The algorithm proposed by the authors is as follows. Typically acute, isolated PCL injuries (grades I and II) are treated non-surgically. In order to properly name PCL injury as 'isolated', three particular conditions should be present, including:[49] (1) PCL comparative kneeling radiographs with <8 mm difference; (2) <5° of abnormal rotatory laxity at 30° of knee flexion; and (3) no significant varus/valgus instability demonstrating mediolateral insufficiency. Most of these patients are able to return to sports within 4–6 weeks after injury after a trial of non-operative treatment. For these cases, counteracting the increased posterior tibial translation with an anteriorly directed force has been clinically validated to improve posterior laxity of the knee.[50] Furthermore, new dynamic braces exist capable of applying forces to the posterior proximal tibia that increase dynamically with increased flexion angles.[51] Conversely, PCLR should be performed in cases of isolated symptomatic acute grade III PCL tears, combined reconstructions for multiligament lesions or when combined with repairable meniscal body or root tears in the acute setting. In cases of an acute, displaced PCL bony avulsion, surgical intervention is indicated.[52] Avulsion fractures usually involve the tibial attachment and are the main indication for a primary PCL repair. The repair should be performed in the acute period (<3 weeks after injury), and may be performed with screws and washers, suture or tension band techniques.[53–55] In contrast to bony avulsion injuries, results of suture repair of acute or chronic midsubstance tears have generally been unsatisfactory, and reconstruction is typically recommended in these cases.[56]

Regarding reconstructions of chronic PCL injury, indications include functional limitations due to the PCL tear (eg, difficulty with deceleration, incline descent or stairs) and PCL stress radiographic laxity >8 mm in symptomatic patients.[57]

KEY ANATOMIC SURGICAL CONSIDERATIONS

The key for a successful PCLR is an anatomical and functional restoration of the knee function and biomechanics. In this regard, reproducing both bundles of the PCL could achieve a more 'anatomic' reconstruction than an SB PCLR where only the 'ALB' is reconstructed based on biomechanically validated data showing improved outcomes with the double bundle[58] (figure 4).

Recently, increased attention has been placed on identifying the anatomical reliable landmarks of the PCL in normal knees that can be arthroscopically visualised, in an attempt to precisely mimic the anatomy during a SB or DB PCLR. The femoral attachment of the PCL has a broad and relatively vertical orientation, with a midpoint of 7–8 mm proximal to the articular surface.[59 60] The attachment has 32 mm in diameter in average. The reported distance between the ALB and the PMB centres is ~12.1 mm (±1.3). The distal margins of the ALB and PMB are 1.5 mm (±0.8) and 5.8 mm (±1.7) proximal from the notch articular cartilage, respectively[61] (figure 5).

Current evidence advises that the clock-face method has reduced clinical accuracy and reproducibility.[62] Therefore, Anderson *et al*[61] proposed reliable arthroscopic landmarks to ultimately offer guidelines for tunnel placement intraoperatively. The centre of the femoral ALB tunnel is located within a three important landmarks. The trochlear point, the medial arch point and the medial bifurcate prominence constitute a triangle that surrounds the attachment in a triangular shape, while the distal edge should be placed adjacent to the articular cartilage. On the other hand, the PMB should be placed halfway from the posterior point and the medial arch point in the femur, distal to the medial intercondylar ridge, at an average of 8.6 mm proximal to the distal cartilage margin. With the given distance between both bundles in the femoral side (average 12.1 mm), the use of an 11 mm and 7 diameter ALB and PMB tunnels, respectively, would still allow for a 2–3 mm bone bridge between the tunnels. In a quantitative analysis of PCL footprints, it has been reported that the PCL femoral insertion area to be 128 mm, which leaves sufficient space to accommodate both tunnels.[63] Conversely, the tibial insertion of the PCL is more compact,[12 64 65] having no anatomic separation between bundles.[2 66] Anderson *et al*[61] reported that the average distance between the ALB and PMB centres on the tibia was 8.9 mm (±1.2) (figure 6).

An important anterior landmark for the tibial PCL footprint is the shiny white fibres (figure 7) of the posterior horn of the medial meniscus, the anterior border. Also, the bony structure termed the bundle ridge consistently defines the posterior margin of the ALB and the anterior margin of the PMB.[61] The centre of the single PCL tunnel should be placed just anterior to the bundle ridge, on the medial side of the PCL facet, 9.8 mm from the lateral cartilage point and 5 mm from the medial groove.[61] Placement of the tunnel more posteriorly or inferiorly will fail to reproduce the normal PCL anatomy and risks injury to the popliteal neurovascular bundle, which lies in close proximity to the ligament. In addition, placement of the tunnel more anteriorly could potentially damage the posterior meniscal root attachments.[67]

To further aid in the movement towards more precise 'anatomic reconstruction' of the PCL using the double-bundle technique, Johannsen *et al*[68] were the first to quantify radiographic guidelines to improve the accuracy of PCLR intraoperatively. Typically, intraoperative fluoroscopic assistance is used to optimise tibial tunnel placement. An intraoperative fluoroscopic AP image of the guide pin should demonstrate its trajectory medial

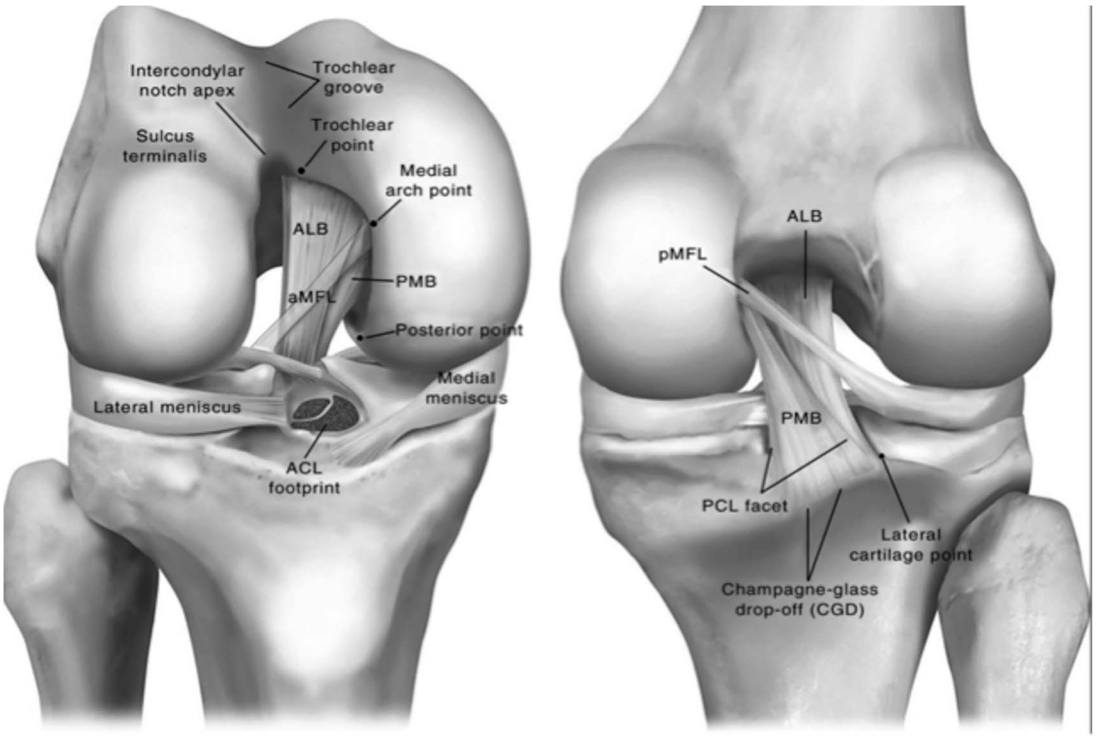

Figure 4 (A) Anterior and (B) posterior views of the native PCL. Emphasised are the femoral and tibial attachments of the ALB and PMB of the PCL and the osseous landmarks: the trochlear point, the medial arch point, the bundle ridge and the champagne glass drop-off. ACL, anterior cruciate ligament; ALB, anterolateral bundle; aMFL, anterior meniscofemoral ligament (ligament of Humphrey); FCL, fibular collateral ligament; PCL, posterior cruciate ligament; PFL, popliteofibular ligament; PMB, posteromedial bundle; pMFL, posterior meniscofemoral ligament (ligament of Wrisberg); POL, posterior oblique ligament. Reproduced with permission from Kennedy *et al*.[27]

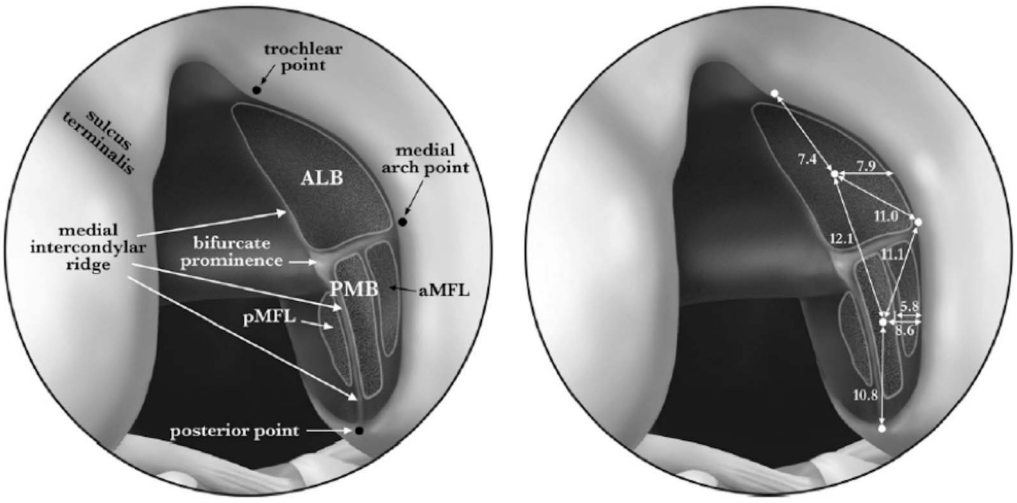

Figure 5 (A) Schematic arthroscopic view of the femoral attachment of the PCL in a right knee, demonstrating pertinent landmarks. (B) Quantitative measurements for the femoral attachment of the PCL. The values are reported in millimetres. ALB, anterolateral bundle; aMFL, anterior meniscofemoral ligament; PCL, posterior cruciate ligament; PMB, posteromedial bundle; pMFL, posterior meniscofemoral ligament. Reproduced with permission from Anderson *et al*.[61]

to the lateral tibial spine and a distance 1.6 mm distal to the joint line, and on the lateral view, the PCL attachment centre should be 5.5 (±1.7) mm superior to the champagne glass drop-off of the posterior tibia.[68]

DOUBLE-BUNDLE PCL SURGICAL TECHNIQUE

The technique uses two allografts fixed in divergent femoral tunnels, passed through a single tibial tunnel and fixed separately on the tibia to recreate the two anatomic bundles of the PCL.[69] A very thorough examination under anaesthesia is required to confirm the diagnosis and also to determine the amount of tibiofemoral step-off at 90° of flexion in the normal contralateral knee to guide later graft fixation. While starting the arthroscopic procedure, the grafts are prepared in the back table. The ALB graft is prepared from an Achilles tendon allograft with an 11 mm diameter and 25 mm long calcaneal bone

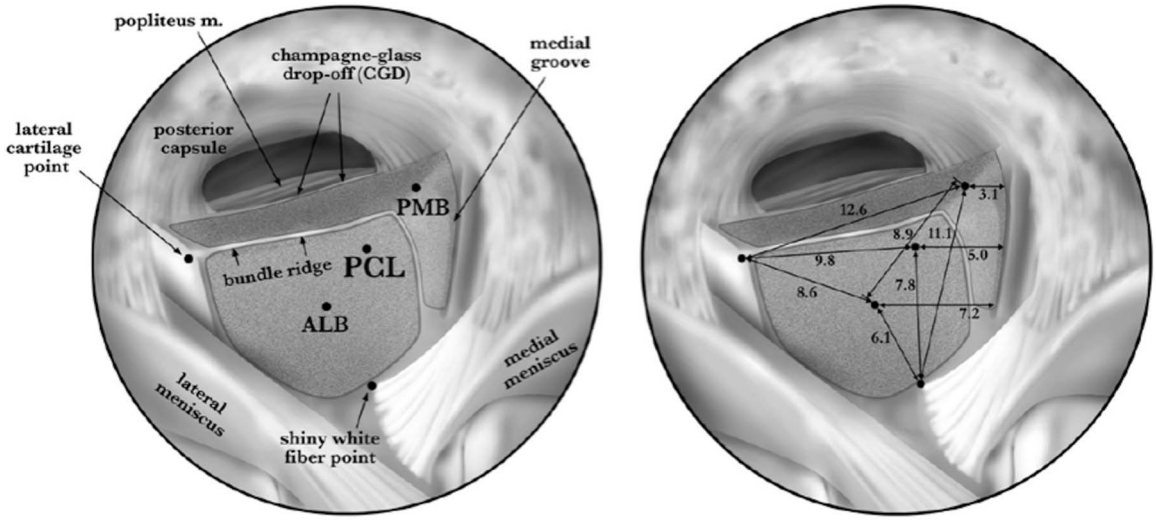

Figure 6 (A) Schematic arthroscopic view of the tibial attachment of the PCL of a right knee, demonstrating the pertinent landmarks. (B) Quantitative measurements for the tibial attachment of the PCL. The values are reported in millimeters. ALB, anterolateral bundle; PCL, posterior cruciate ligament; PMB, posteromedial bundle; m, muscle. Reproduced with permission from Anderson *et al*.[61]

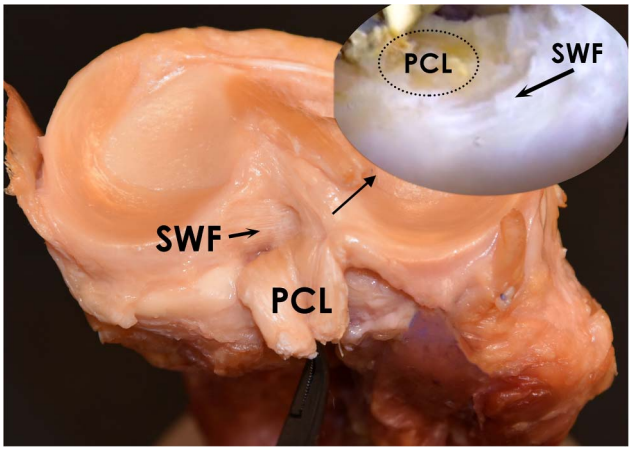

Figure 7 Cadaveric dissection depicting the intimate relationship of the posterior meniscal roots with the PCL (right knee). In the picture of the superior right corner, an arthroscopic view demonstrates the anatomic attachment of the PCL posterior to the SWF. PCL, posterior cruciate ligament; SWF, shiny white fibres.

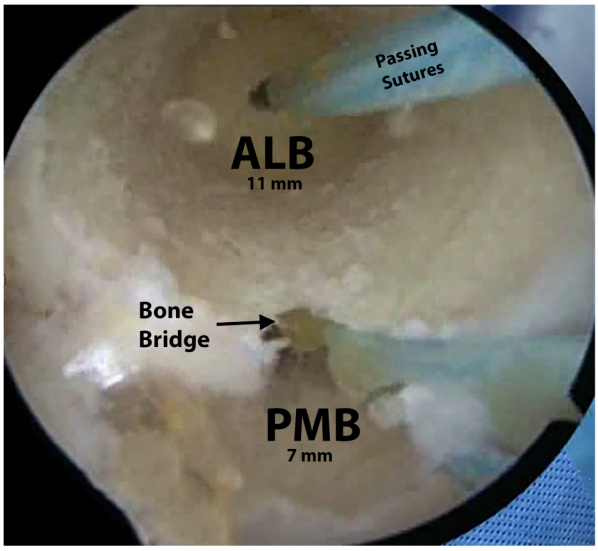

Figure 8 Arthroscopic view of the PCL tunnels through an anterolateral portal. The ALB is observed immediately against the cartilage (11 mm) and the PMB is located 5 mm posterior to the cartilage with a 2 mm bone bridge tunnel to avoid tunnel convergence. ALB, anterolateral bundle; PCL, posterior cruciate ligament; PMB, posteromedial bundle.

plug, and the distal soft tissue aspect of the graft is tubularised with a number-2 non-absorbable suture. A similar construct can be prepared from a quadriceps autograft with bone block when allograft is unavailable. The PMB graft is similarly prepared from a 7 mm diameter soft tissue allograft (semitendinosus, tibialis anterior or soft tissue portion of Achilles allograft) by tubularising each end of the graft.

After a diagnostic arthroscopy is performed through standard anterolateral and anteromedial portals, the attention is turned to the PCLR.

The femoral attachments of the ALB and PMB are identified with an arthroscopic coagulator. The ALB attachment is first outlined between the trochlear point and medial arch point and adjoining the edge of the articular cartilage. This tunnel should be placed as far distal as possible. The PMB attachment is next marked ~8–9 mm posterior to the edge of the articular cartilage of the medial femoral condyle and slightly posterior to the ALB tunnel. Then, an 11 mm diameter acorn reamer placed through the anterolateral arthroscopic portal is used as a guide to outline and ultimately ream the ALB femoral tunnel. The reamer is positioned at the previously marked centre of the ALB so that the reamer edges (using the convex side of the reamer) are against the margins of the articular cartilage at the top of the intercondylar roof and centred between the trochlear point and the medial arch point. An eyelet pin is then drilled through the reamer anteromedially out of the knee with the knee at 90° of flexion. Then, a closed socket tunnel is reamed over the eyelet pin to a depth of 25 mm. A passing suture is placed through the tunnel to facilitate later graft passage. With use of the same technique, a 7 mm reamer is placed against the previously outlined PMB, and an eyelet pin is also drilled through this reamer,

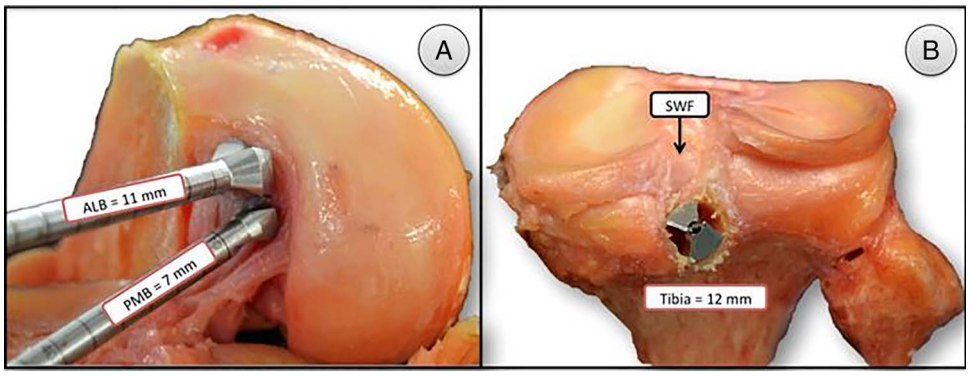

Figure 9 Anatomical attachment sites. (A) Hemisectioned knee image demonstrating ALB reamer positioning (11 mm reamer) and PMB reamer positioning (7 mm reamer) on the femur. Of note, there must exist a 2 mm space between both femoral tunnels. (B) Tibial posterior view of a right knee demonstrating a desired reamer position exit site taking the SWF as an anatomical landmark (12 mm reamer). ALB, anterolateral bundle; PMB, posteromedial bundle; SWF, shiny white fibres. Reproduced with permission from Chahla *et al*.[69]

exiting through the anteromedial aspect of the knee. A 25 mm deep closed socket is likewise reamed, trying to diverge from the ALB reconstruction tunnel with its trajectory. A 2 mm bone bridge distance is maintained between the two femoral PCL bundle tunnels (figure 8). This is critical to avoid loss of graft purchase in case of tunnel convergence. Once the femoral tunnels are created, attention is turned to identifying the tibial attachment. For this purpose, a 70° arthroscope is used to visualise an arthroscopic shaver placed through a posteromedial portal to debride the PCL tibial attachment (figure 9).

A posteromedial portal can be created to facilitate the identification and preparation of the tibial facet. This portal should be placed as far proximal as possible to avoid interference with the medial condyle. The PCL tibial attachment site is debrided and identified distally along the PCL facet. The posterior capsule is carefully elevated until the proximal aspect of the popliteus muscle fibres are visualised to ensure that the tunnel will be located sufficiently distally. Next, a guide pin is drilled, entering the anteromedial aspect of the tibia ~6 cm distal to the joint line, centred between the anterior tibial crest and the medial tibial border, and exiting posteriorly at the centre of the PCL tibial attachment along the previously described PCL bundle ridge, which has been reported to be located between the ALB and PMB on the tibia.[61] Intraoperative anteroposterior and lateral radiographs or fluoroscopy are used to verify tibial guide pin placement, which on the lateral radiograph should be ~6–7 mm proximal to the champagne glass drop-off at the PCL facet on the posterior part of the tibia (figure 10). On anteroposterior radiographs, this point is identified at the medial aspect of the lateral tibial eminence and 1–2 mm distal to the joint line.[68]

Once radiographic confirmation of the desired tibial guide pin location is confirmed, a large curette or the outside sheath of a shaver is passed through the posteromedial arthroscopic portal to retract the posterior tissues away from the reamer and to protect against guide pin protrusion and neurovascular damage. Then, a 12 mm acorn reamer over-reams the tibial guide pin under direct posterior arthroscopic visualisation. It is not recommended to use a smooth bore reamer when reaming the tibial tunnel due to the increased risk of uncontrolled penetration out the posterior tibial cortex, which could lead to iatrogenic popliteal artery injury.[70] If necessary, the exit of the reamer out of the posterior tibial cortex can be performed by hand.

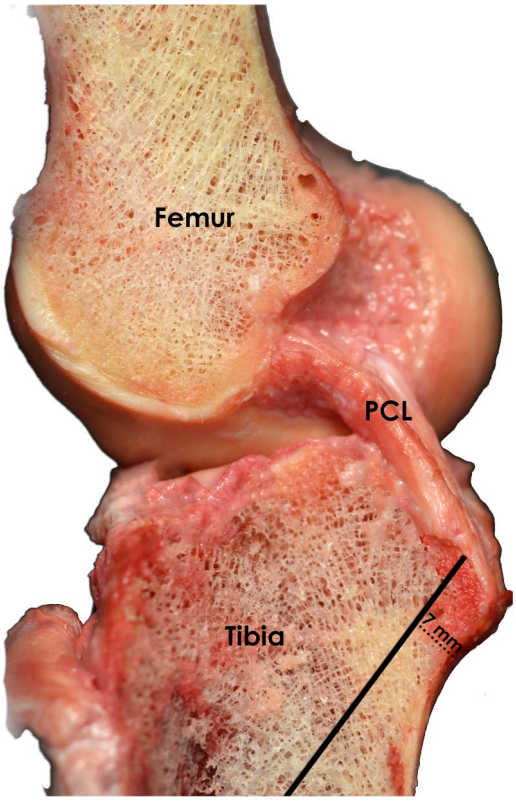

Figure 10 Cadaveric dissection of an hemisectioned knee demonstrating an ideal positioning of the transtibial tunnel guide pin at the posterior aspect of the tibia, 7 mm anterior to the champagne glass drop-off. PCL, posterior cruciate ligament.

Next, a large smoother (Acufex Smoother Crucial tool, Smith and Nephew, Andover, Massachusetts, USA) is passed proximally up the tibial tunnel, and pulled out the anteromedial arthroscopic portal with a grasper (a rasp can be used alternatively to smooth the tunnel walls and a thick wire with a loop to pass the grafts).

The smoother is gently cycled several times to smooth the intra-articular tibial tunnel aperture to remove any bony spicules that could interfere with later graft passage. The closed loop tip of the smoother is then pulled back into the joint, under the previously placed femoral tunnel passing sutures and passed out

Tips and tricks

- *Patient positioning*: It is important to remember to allow full flexion and extension of the knee. The contralateral leg should be abducted in abduction leg holder to facilitate a comfortable work space.
- *Graft preparation*: When whipstitching the soft tissue graft ends, tightly spacing the sutures at the distal ends of the grafts protects the grafts from laceration when securing with an interference screw.
- *Anatomic identification* of each bundle attachment location is crucial. Use of an arthroscopic coagulator to outline the distal location of each bundle allows for more accurate tunnel placement.
- *Tunnel positioning*: Anterolateral bundle (ALB) against the cartilage and posteromedial bundle (PMB) 5 mm posterior with a 2 mm tunnel bridge. Use the reamer as a guide for tunnel placement. Slight divergence of the femoral tunnels ensures that the tunnels will not collapse during fixation. The interference screws should be placed within the tunnel opposite the bone bridge so as to reduce the potential for fracture. For the tibial tunnel, locate the shiny white fibres and the bundle ridge. Position the guide at the crest of the ridge.
- *Acorn reamers* are recommended so that the surgeon may add fine adjustments to the tibial tunnel path. A tunnel smoother should be used to reduce friction between the graft and the aperture of the tibial tunnel at the 'killer turn'; this reduces the chance of graft laceration as it is drawn into the tunnel.
- *Fixation*: The ALB should be fixed with the knee in 90° of flexion, whereas the PMB should be fixed with the knee in full extension. A screw and washer graft fixation system on the anterior tibia minimises postoperative pain while providing optimal fixation strength.
- *Postoperative rehabilitation* should focus on progressive weight-bearing and quadriceps activation.

Major pitfalls

- *Patient positioning*: Incorrect positioning of the patient may prevent the surgeon to correctly position the knee at certain steps of the surgery limiting the ability to position/fix tunnels and grafts, respectively.
- *Graft preparation*: Oversizing the grafts can complicate the passage and fitting into the tunnels. Care must be taken not to violate the suture fibres with the needle while the surgeon is tightly stitching the graft.
- *Tunnel positioning*: On the femoral side, failing to create divergent tunnels or not leaving an appropriate bone bridge can result in tunnel convergence and loss of graft purchase. Debride the posterior aspect of the tibia to assess the anatomic position of the posterior cruciate ligament tibial attachment. Always check with fluoroscopy if the desired position was achieved.
- *Neurovascular complications*: Be extremely diligent when reaming the tibial tunnel. Finishing the reaming by hand and positioning a curette on top of the pin when reaming can avoid vascular complications. Moreover, the surgeon may partially remove the guide pin after initiating drilling of the tibial tunnel to prevent guide pin complications. Fluoroscopic imaging can help to assess the correct positioning of the guide pin and the distance to the cortex.
- *Fixation*: Given the codominant nature of the bundles, incorrect knee flexion angles during fixation may result in graft laxity during motion.

the anterolateral arthroscopic portal. Next, the PMB graft is passed into its femoral tunnel with the passing suture directed through the anterolateral portal. The PMB graft is then fixed in the femoral tunnel with a 7×23 mm bioabsorbable interference screw (positioning the screw at the posteroinferior aspect of the tunnel). The bone plug for the ALB graft is then similarly passed into its femoral tunnel with the cortical side of the bone plug placed adjacent to the articular cartilage and secured with a 7×20 mm titanium interference screw (positioning the screw at the anterosuperior aspect of the tunnel). After the grafts are fixed in the femoral tunnels, the sutures in the ends of both grafts are then passed through the loop tip of the smoother. The smoother and the graft sutures in its eyelet tip are pulled distally down the tibial tunnel and out the anteromedial aspect of the tibia; the grafts are pulled down the tibia and then individually cycled several times to remove any potential slack in the grafts. Arthroscopic verification should confirm that the ACL is reduced to its normal position while traction is concurrently placed on the grafts.

In addition, the normal tibiofemoral step-off is verified to be restored, compared to the examination under anaesthesia, while traction is applied to the grafts. With the knee flexed to 90° and in neutral rotation, the ALB is secured to the tibia with a fully threaded bicortical 6.5 mm cannulated cancellous screw and an 18 mm spiked washer (though a small hole created in the graft)[71] (figure 11). During tibial graft fixation, an anterior reduction force is applied to the tibia and distal traction applied to the graft. Verification of posterior stability is confirmed with elimination of the posterior drawer test at 90° of knee flexion.[71] The PMB is then secured to the tibia with the knee in full extension with a similar size screw and washer that was used for AMB fixation while distal traction is placed on the graft[71] (figure 12). The excess portion of the grafts is then excised ~1.5 cm distal to the screws.

POSTOPERATIVE REHABILITATION

Rehabilitation should be initiated the first postoperative day. The primary initial goals are centred on oedema control, prevention of posterior subluxation and strengthening of the quadriceps muscle. Postoperatively, all patients remain non-weight-bearing for 6 weeks with a dynamic PCL brace (Ossur PCL Rebound brace). Physical therapy emphasises early quadriceps muscle activation and prone knee flexion from 0° to 90° of flexion for the initial 2 weeks postoperatively. This avoids hamstring activation which places increased stress on the graft. Knee motion increases past 90° as tolerated starting 2 weeks postoperatively, with prone knee flexion exercises. Postoperatively, patients begin weight-bearing exercises and low resistance stationary bike (maximum of 70° of knee flexion) at 6 weeks. Progressive evolution into low-impact knee exercises is allowed as tolerated by the patient, starting 12 weeks after the surgery.

Six months postoperatively, patients are evaluated clinically and with kneeling posterior stress radiographs. Patients who are allowed to discontinue the brace can initiate a jogging programme, side-to-side and proprioceptive exercises. Functional testing is performed between 9 and 12 months postoperatively

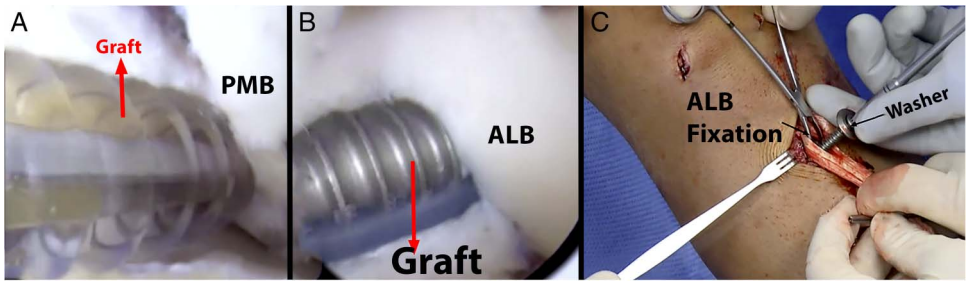

Figure 11 Graft fixation image. (A) The PMB bundle is fixed first in the femoral tunnel with a 7×23 mm bioabsorbable interference screw (positioning the screw at the posteroinferior aspect of the tunnel). (B) The ALB bone graft is then secured with a 7×20 mm titanium interference screw (positioning the screw at the anterosuperior aspect of the tunnel). (C) Tibial fixation: with the knee flexed to 90° and in neutral rotation, the ALB is secured to the tibia with a fully threaded bicortical screw and a spiked washer. The PMB is then secured to the tibia with the knee in full extension. ALB, anterolateral bundle; PMB, posteromedial bundle.

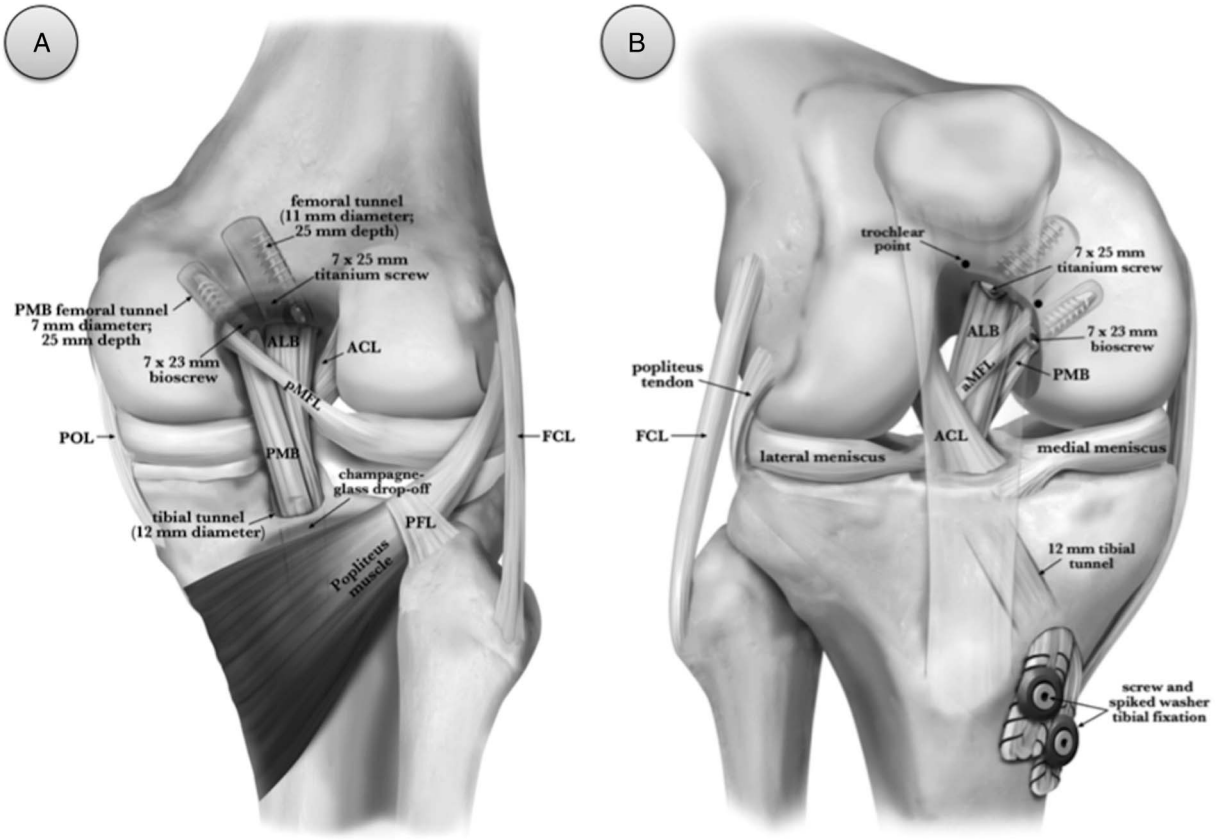

Figure 12 (A) Posterior and (B) anterior views of the aDB PCLR. The reconstructed ALB and PMB are shown, as well as the size, shape and location of their femoral and tibial tunnels. The PMB enters the tibial tunnel posteromedial to the ALB. The PMB is posterior in the transtibial tunnel and exits deep to the ALB and then is fixed medially and distally to the ALB. Femoral fixations of both bundles and the champagne glass drop-off, the anatomic landmark for transtibial tunnel drilling, are also displayed. ACL, anterior cruciate ligament; aDB, anatomic double-bundle; ALB, anterolateral bundle; aMFL, anterior meniscofemoral ligament (ligament of Humphrey); FCL, fibular collateral ligament; PCLR, posterior cruciate ligament reconstruction; PFL, popliteofibular ligament; PMB, posteromedial bundle; pMFL, posterior meniscofemoral ligament (ligament of Wrisberg); POL, posterior oblique ligament. Reproduced with permission from Wijdicks *et al*.[32]

to determine the ability of the patients to return to full activities. The functional PCL rebound brace is worn for the first year of a return to athletic competition.

CLINICAL OUTCOMES

Although it has been reported that reconstruction of the PCL reduces posterior tibial translation and rotational instability, results have been inconsistent regarding the efficacy of the procedure in restoring normal function and kinematics, probably due to the heterogeneous indications, lack of knowledge of important anatomical landmarks, the relative low incidence of this injuries and the different rehabilitation protocols.[58 72 73]

A recent systematic review[8] compared outcomes of conservative and surgical reconstruction in isolated PCL injuries. The success rates of conservative and reconstructive treatment were 33% and 90%, with a side-to-side difference of posterior tibial

translation ranging from 3.5 to 5.3 mm vs 2.0 to 3.7 (Telos) and from 3.0 to 5.2 mm to 0.7 to 5.9 mm (KT-1000), respectively. Moreover, in the conservative treatment group, a wider range of anteroposterior instability persists compared to that of the reconstructive treatment. This study concluded that there was more satisfactory and consistent stability in the reconstructive treatment group. In regards to single-bundle versus double-bundle reconstructions, another systematic review concluded that double-bundle reconstruction was significantly superior to single-bundle reconstruction in biomechanical studies. However, no significant differences were reported for clinical outcomes between the two PCLRs.[10]

Spiridonov *et al*[74] hypothesised that minor variations in technique may lead to improved clinical outcomes following double-bundle PCLR. Given that most surgical techniques split the vastus medialis obliquus (VMO) via use of an anteromedial portal, which may weaken the quadriceps muscle and delay recovery, the authors studied the effects of a VMO-sparing approach to PCLR. They analysed 31 patients with isolated and combined grade III PCL tears treated with endoscopic, double-bundle, transtibial reconstruction using Achilles allograft placed into the femoral tunnel through a lateral arthroscopic portal.[74] The grafts were secured by an all-inside method and passed distally through a transtibial tunnel to avoid surgical injury to the VMO, similar to the surgical technique described above. Following a period of at least 2 years, there were significant improvements in subjective and objective outcome scores compared to preoperative data, as well as translation on posterior stress radiographs, suggesting that this technique may be successful in treating patients with isolated and combined grade III PCL tears. However, no comparison groups were used, and further studies are warranted before declaring one technique objectively superior to another.

Over the past decade, several studies have been conducted to evaluate the efficacy of single-bundle versus double-bundle reconstructions. To date, however, the literature is inconclusive with regards to superiority of one technique over the other. Harner *et al*[5] compared single-bundle and double-bundle PCLRs in a biomechanical study using Achilles and doubled semitendinosus grafts for each respective technique. The authors reported significant differences in posterior tibial translation following single-bundle reconstruction compared to double-bundle reconstruction and normal knees, and no difference in translation between double-bundle knees and normal knees. The authors concluded that double-bundle reconstruction more closely restores the biomechanics of the intact knee than does single-bundle reconstruction throughout knee range of motion.[5] Lastly, the tibial inlay technique has the potential benefits of bone on bone healing, avoidance of the killer tibial turn and use of large graft size. In this regard, Bergfeld *et al*[75] compared transtibial (single and double bundle) and tibial inlay PCLR techniques in cadaver knees. Their group reported no difference in translation following single-bundle and double-bundle reconstructions at various degrees of flexion, concluding that single-bundle and double-bundle techniques reproduced posterior stability of the knee.[75] Of note, the posterior tibial translation with a single-bundle reconstruction was found to be 5–7 mm throughout the range of motion and the double bundle was still between 4 and 5 mm, so normal restoration of translation was not achieved in either study.

CONCLUSIONS AND FUTURE PERSPECTIVES

Recent studies examining the anatomy and biomechanical properties of the PCL have led to new surgical techniques in PCLR that attempt to duplicate the functional behaviour of the native PCL throughout the full range of knee motion. The endoscopic double-bundle PCLR allows for restoration of posterior and rotational stability throughout a full knee range of motion, and preliminary clinical studies have demonstrated good to excellent short-term clinical outcomes using this technique. Further studies are warranted to more thoroughly evaluate the long-term clinical effectiveness of various surgical techniques, including single-bundle versus double-bundle and tibial inlay PCLR techniques, in addition to pertinent rehabilitation principles, in an attempt to improve patient outcomes following operative and non-operative treatment of PCL injury.

Twitter Follow Jorge Chahla at @jachahla

Competing interests RFLP is a consultant and receives royalties from Arthrex, Ossur and Smith & Nephew. RPBvB is a consultant from Smith & Nephew and Arthrex. LE is a consultant for Smith & Nephew and Arthrex and receives royalties from Arthrex.

Provenance and peer review Commissioned; externally peer reviewed.

REFERENCES

1 Sekiya JK, Whiddon DR, Zehms CT, *et al*. A clinically relevant assessment of posterior cruciate ligament and posterolateral corner injuries. Evaluation of isolated and combined deficiency. *J Bone Joint Surg Am* 2008;90:1621–7.
2 Girgis FG, Marshall JL, Monajem A. The cruciate ligaments of the knee joint. Anatomical, functional and experimental analysis. *Clin Orthop Relat Res* 1975;106:216–31.
3 Van Dommelen BA, Fowler PJ. Anatomy of the posterior cruciate ligament. A review. *Am J Sports Med* 1989;17:24–9.
4 Papannagari R, DeFrate LE, Nha KW, *et al*. Function of posterior cruciate ligament bundles during in vivo knee flexion. *Am J Sports Med* 2007;35:1507–12.
5 Harner CD, Janaushek MA, Kanamori A, *et al*. Biomechanical analysis of a double-bundle posterior cruciate ligament reconstruction. *Am J Sports Med* 2000;28:144–51.
6 Bedi A, Musahl V, Cowan JB. Management of posterior cruciate ligament injuries: an evidence-based review. *J Am Acad Orthop Surg* 2016;24:277–89.
7 Sanders TL, Pareek A, Barrett IJ, *et al*. Incidence and long-term follow-up of isolated posterior cruciate ligament tears. *Knee Surg Sports Traumatol Arthrosc* 2016 Feb 27. [Epub ahead of print].
8 Ahn S, Lee YS, Song YD, *et al*. Does surgical reconstruction produce better stability than conservative treatment in the isolated PCL injuries? *Arch Orthop Trauma Surg* 2016;136:811–19.
9 Kennedy NI, LaPrade RF, Goldsmith MT, *et al*. Posterior cruciate ligament graft fixation angles, part 1: biomechanical evaluation for anatomic single-bundle reconstruction. *Am J Sports Med* 2014;42:2338–45.
10 Qi YS, Wang HJ, Wang SJ, *et al*. A systematic review of double-bundle versus single-bundle posterior cruciate ligament reconstruction. *BMC Musculoskelet Disord* 2016;17:45.
11 Lenschow S, Zantop T, Weimann A, *et al*. Joint kinematics and in situ forces after single bundle PCL reconstruction: a graft placed at the center of the femoral attachment does not restore normal posterior laxity. *Arch Orthop Trauma Surg* 2006;126:253–9.
12 Matava MJ, Ellis E, Gruber B. Surgical treatment of posterior cruciate ligament tears: an evolving technique. *J Am Acad Orthop Surg* 2009;17:435–46.
13 Parolie JM, Bergfeld JA. Long-term results of nonoperative treatment of isolated posterior cruciate ligament injuries in the athlete. *Am J Sports Med* 1986;14:35–8.
14 Harner CD, Xerogeanes JW, Livesay GA, *et al*. The human posterior cruciate ligament complex: an interdisciplinary study. Ligament morphology and biomechanical evaluation. *Am J Sports Med* 1995;23:736–45.
15 Makris CA, Georgoulis AD, Papageorgiou CD, *et al*. Posterior cruciate ligament architecture: evaluation under microsurgical dissection. *Arthroscopy* 2000;16:627–32.
16 Lopes OV Jr, Ferretti M, Shen W, *et al*. Topography of the femoral attachment of the posterior cruciate ligament. *J Bone Joint Surg Am* 2008;90:249–55.
17 Kennedy JC, Hawkins RJ, Willis RB, *et al*. Tension studies of human knee ligaments. Yield point, ultimate failure, and disruption of the cruciate and tibial collateral ligaments. *J Bone Joint Surg Am* 1976;58:350–5.
18 Gupte CM, Bull AM, Thomas RD, *et al*. A review of the function and biomechanics of the meniscofemoral ligaments. *Arthroscopy* 2003;19:161–71.
19 Butler DL, Noyes FR, Grood ES. Ligamentous restraints to anterior-posterior drawer in the human knee. A biomechanical study. *J Bone Joint Surg Am* 1980;62:259–70.
20 Gollehon DL, Torzilli PA, Warren RF. The role of the posterolateral and cruciate ligaments in the stability of the human knee. A biomechanical study. *J Bone Joint Surg Am* 1987;69:233–42.

21 Markolf KL, Slauterbeck JR, Armstrong KL, *et al*. A biomechanical study of replacement of the posterior cruciate ligament with a graft. Part II: forces in the graft compared with forces in the intact ligament. *J Bone Joint Surg Am* 1997;79:381–6.
22 Covey DC, Sapega AA, Riffenburgh RH. The effects of sequential sectioning of defined posterior cruciate ligament fiber regions on translational knee motion. *Am J Sports Med* 2008;36:480–6.
23 Race A, Amis AA. The mechanical properties of the two bundles of the human posterior cruciate ligament. *J Biomech* 1994;27:13–24.
24 Markolf KL, Feeley BT, Tejwani SG, *et al*. Changes in knee laxity and ligament force after sectioning the posteromedial bundle of the posterior cruciate ligament. *Arthroscopy* 2006;22:1100–6.
25 Covey DC, Sapega AA, Sherman GM. Testing for isometry during reconstruction of the posterior cruciate ligament. Anatomic and biomechanical considerations. *Am J Sports Med* 1996;24:740–6.
26 Markolf KL, Zemanovic JR, McAllister DR. Cyclic loading of posterior cruciate ligament replacements fixed with tibial tunnel and tibial inlay methods. *J Bone Joint Surg Am* 2002;84-A:518–24.
27 Kennedy NI, Wijdicks CA, Goldsmith MT, *et al*. Kinematic analysis of the posterior cruciate ligament, part 1: the individual and collective function of the anterolateral and posteromedial bundles. *Am J Sports Med* 2013;41:2828–38.
28 Escamilla RF, Zheng N, MacLeod TD, *et al*. Cruciate ligament tensile forces during the forward and side lunge. *Clin Biomech (Bristol, Avon)* 2010;25:213–21.
29 Jeong WS, Yoo YS, Kim DY, *et al*. An analysis of the posterior cruciate ligament isometric position using an in vivo 3-dimensional computed tomography-based knee joint model. *Arthroscopy* 2010;26:1333–9.
30 Li G, DeFrate LE, Sun H, *et al*. In vivo elongation of the anterior cruciate ligament and posterior cruciate ligament during knee flexion. *Am J Sports Med* 2004;32:1415–20.
31 Ahmad CS, Cohen ZA, Levine WN, *et al*. Codominance of the individual posterior cruciate ligament bundles. An analysis of bundle lengths and orientation. *Am J Sports Med* 2003;31:221–5.
32 Wijdicks CA, Kennedy NI, Goldsmith MT, *et al*. Kinematic analysis of the posterior cruciate ligament, part 2: a comparison of anatomic single- versus double-bundle reconstruction. *Am J Sports Med* 2013;41:2839–48.
33 Owesen C, Sandven-Thrane S, Lind M, *et al*. Epidemiology of surgically treated posterior cruciate ligament injuries in Scandinavia. *Knee Surg Sports Traumatol Arthrosc* 2015 Sep 19. [Epub ahead of print].
34 Fanelli GC, Edson CJ. Posterior cruciate ligament injuries in trauma patients: Part II. *Arthroscopy* 1995;11:526–9.
35 Gill TJ, DeFrate LE, Wang C, *et al*. The effect of posterior cruciate ligament reconstruction on patellofemoral contact pressures in the knee joint under simulated muscle loads. *Am J Sports Med* 2004;32:109–15.
36 Kozanek M, Fu EC, Van de Velde SK, *et al*. Posterolateral structures of the knee in posterior cruciate ligament deficiency. *Am J Sports Med* 2009;37:534–41.
37 Strobel MJ, Weiler A, Schulz MS, *et al*. Arthroscopic evaluation of articular cartilage lesions in posterior-cruciate-ligament-deficient knees. *Arthroscopy* 2003;19:262–8.
38 Jackson WF, van der Tempel WM, Salmon LJ, *et al*. Endoscopically-assisted single-bundle posterior cruciate ligament reconstruction: results at minimum ten-year follow-up. *J Bone Joint Surg Br* 2008;90:1328–33.
39 Song EK, Park HW, Ahn YS, *et al*. Transtibial versus tibial inlay techniques for posterior cruciate ligament reconstruction: long-term follow-up study. *Am J Sports Med* 2014;42:2964–71.
40 Kim YM, Lee CA, Matava MJ. Clinical results of arthroscopic single-bundle transtibial posterior cruciate ligament reconstruction: a systematic review. *Am J Sports Med* 2011;39:425–34.
41 Jackman T, LaPrade RF, Pontinen T, *et al*. Intraobserver and interobserver reliability of the kneeling technique of stress radiography for the evaluation of posterior knee laxity. *Am J Sports Med* 2008;36:1571–6.
42 Laprade RF, Bernhardson AS, Griffith CJ, *et al*. Correlation of valgus stress radiographs with medial knee ligament injuries: an in vitro biomechanical study. *Am J Sports Med* 2010;38:330–8.
43 LaPrade RF, Heikes C, Bakker AJ, *et al*. The reproducibility and repeatability of varus stress radiographs in the assessment of isolated fibular collateral ligament and grade-III posterolateral knee injuries. An in vitro biomechanical study. *J Bone Joint Surg Am* 2008;90:2069–76.
44 Schulz MS, Steenlage ES, Russe K, *et al*. Distribution of posterior tibial displacement in knees with posterior cruciate ligament tears. *J Bone Joint Surg Am* 2007;89:332–8.
45 Schulz MS, Russe K, Lampakis G, *et al*. Reliability of stress radiography for evaluation of posterior knee laxity. *Am J Sports Med* 2005;33:502–6.
46 Jung TM, Reinhardt C, Scheffler SU, *et al*. Stress radiography to measure posterior cruciate ligament insufficiency: a comparison of five different techniques. *Knee Surg Sports Traumatol Arthrosc* 2006;14:1116–21.
47 Ellman M, LaPrade RF. Current concepts in the treatment of posterior cruciate ligament injuries. In: Doral NM, Karlsson J, eds. *Sports injuries: prevention, diagnosis, treatment and rehabilitation*. Berlin, Heidelberg: Springer, 2015:1003–19.
48 Allen CR RJ, Harner CD. Posterior cruciate ligament: diagnosis and decision making. In: Miller MD, Cole BJ, eds. *Textbook of arthroscopy*. Philadelphia, Elsevier, 2004:687–702.
49 Pierce CM, O'Brien L, Griffin LW, *et al*. Posterior cruciate ligament tears: functional and postoperative rehabilitation. *Knee Surg Sports Traumatol Arthrosc* 2013;21:1071–84.
50 Jung YB, Tae SK, Lee YS, *et al*. Active non-operative treatment of acute isolated posterior cruciate ligament injury with cylinder cast immobilization. *Knee Surg Sports Traumatol Arthrosc* 2008;16:729–33.
51 LaPrade RF, Smith SD, Wilson KJ, *et al*. Quantification of functional brace forces for posterior cruciate ligament injuries on the knee joint: an in vivo investigation. *Knee Surg Sports Traumatol Arthrosc* 2015;23:3070–6.
52 Veltri DM, Warren RF. Isolated and combined posterior cruciate ligament injuries. *J Am Acad Orthop Surg* 1993;1:67–75.
53 Espejo-Baena A, López-Arévalo R, Urbano V, *et al*. Arthroscopic repair of the posterior cruciate ligament: two techniques. *Arthroscopy* 2000;16:656–60.
54 Kim SJ, Shin SJ, Choi NH, *et al*. Arthroscopically assisted treatment of avulsion fractures of the posterior cruciate ligament from the tibia. *J Bone Joint Surg Am* 2001;83-A:698–708.
55 Richter M, Kiefer H, Hehl G, *et al*. Primary repair for posterior cruciate ligament injuries. An eight-year followup of fifty-three patients. *Am J Sports Med* 1996;24:298–305.
56 Bianchi M. Acute tears of the posterior cruciate ligament: clinical study and results of operative treatment in 27 cases. *Am J Sports Med* 1983;11:308–14.
57 LaPrade CM, Civitarese DM, Rasmussen MT, *et al*. Emerging updates on the posterior cruciate ligament: a review of the current literature. *Am J Sports Med* 2015;43:3077–92.
58 Sekiya JK, West RV, Ong BC, *et al*. Clinical outcomes after isolated arthroscopic single-bundle posterior cruciate ligament reconstruction. *Arthroscopy* 2005;21:1042–50.
59 Mejia EA, Noyes FR, Grood ES. Posterior cruciate ligament femoral insertion site characteristics. Importance for reconstructive procedures. *Am J Sports Med* 2002;30:643–51.
60 Fuss FK. Anatomy of the cruciate ligaments and their function in extension and flexion of the human knee joint. *Am J Anat* 1989;184:165–76.
61 Anderson CJ, Ziegler CG, Wijkicks CA, *et al*. Arthroscopically pertinent anatomy of the anterolateral and posteromedial bundles of the posterior cruciate ligament. *J Bone Joint Surg Am* 2012;94:1936–45.
62 Apsingi S, Bull AM, Deehan DJ, *et al*. Review: femoral tunnel placement for PCL reconstruction in relation to the PCL fibre bundle attachments. *Knee Surg Sports Traumatol Arthrosc* 2009;17:652–9.
63 Harner CD, Baek GH, Vogrin TM, *et al*. Quantitative analysis of human cruciate ligament insertions. *Arthroscopy* 1999;15:741–9.
64 Edwards A, Bull AM, Amis AA. The attachments of the fiber bundles of the posterior cruciate ligament: an anatomic study. *Arthroscopy* 2007;23:284–90.
65 Dargel J, Pohl P, Tzikaras P, *et al*. Morphometric side-to-side differences in human cruciate ligament insertions. *Surg Radiol Anat* 2006;28:398–402.
66 Cosgarea AJ, Jay PR. Posterior cruciate ligament injuries: evaluation and management. *J Am Acad Orthop Surg* 2001;9:297–307.
67 Kennedy NI, Michalski MP, Engebretsen L, *et al*. Iatrogenic meniscus posterior root injury following reconstruction of the posterior cruciate ligament. A report of three cases. *JBJS Case Connect* 2014;4:e20.
68 Johannsen AM, Anderson CJ, Wijdicks CA, *et al*. Radiographic landmarks for tunnel positioning in posterior cruciate ligament reconstructions. *Am J Sports Med* 2013;41:35–42.
69 Chahla J, Nitri M, Civitarese D, *et al*. Anatomic double-bundle posterior cruciate ligament reconstruction. *Arthrosc Tech* 2016;5:e149–56.
70 Zawodny SR, Miller MD. Complications of posterior cruciate ligament surgery. *Sports Med Arthrosc* 2010;18:269–74.
71 Kennedy NI, LaPrade RF, Goldsmith MT, *et al*. Posterior cruciate ligament graft fixation angles, part 2: biomechanical evaluation for anatomic double-bundle reconstruction. *Am J Sports Med* 2014;42:2346–55.
72 Hatayama K, Higuchi H, Kimura M, *et al*. A comparison of arthroscopic single- and double-bundle posterior cruciate ligament reconstruction: review of 20 cases. *Am J Orthop (Belle Mead NJ)* 2006;35:568–71.
73 Watsend AM, Osestad TM, Jakobsen RB, *et al*. Clinical studies on posterior cruciate ligament tears have weak design. *Knee Surg Sports Traumatol Arthrosc* 2009;17:140–9.
74 Spiridonov SI, Slinkard NJ, LaPrade RF. Isolated and combined grade-III posterior cruciate ligament tears treated with double-bundle reconstruction with use of endoscopically placed femoral tunnels and grafts: operative technique and clinical outcomes. *J Bone Joint Surg Am* 2011;93:1773–80.
75 Bergfeld JA, Graham SM, Parker RD, *et al*. A biomechanical comparison of posterior cruciate ligament reconstructions using single- and double-bundle tibial inlay techniques. *Am J Sports Med* 2005;33:976–81.

Anatomic posterior cruciate ligament reconstruction: State of the Art

Jorge Chahla, Richard von Bormann, Lars Engebretsen and Robert F LaPrade

J ISAKOS 2016 1: 292-302 originally published online August 17, 2016
doi: 10.1136/jisakos-2016-000078