

Technical Note

Posterior Wall Blowout During Anterior Cruciate Ligament Reconstruction: Suspensory Cortical Fixation With a Screw and Washer Post

Justin J. Mitchell, M.D., Jorge Chahla, M.D., Chase S. Dean, M.D., Travis J. Menge, M.D., Alexander R. Vap, M.D., Tyler R. Cram, A.T.C., O.T.C., and Robert F. LaPrade, M.D., Ph.D.

Abstract: Posterior wall blowout can be a devastating intraoperative complication in anterior cruciate ligament reconstruction. This loss of osseous containment can cause difficulty with graft fixation and can potentially lead to early graft failure if unrecognized and left untreated. If cortical blowout occurs despite careful planning and proper surgical technique, a thorough knowledge of the local anatomy and surgical salvage options is paramount to ensure positive patient outcomes. This article highlights our preferred salvage technique using suspensory cortical fixation with a screw and washer construct.

It has been estimated that between 1994 and 2006, the population-adjusted rate of anterior cruciate ligament reconstructions (ACLRs) increased by 37%.¹ Approximately 200,000 ACLRs are performed each year in the United States.² With the rise in surgical intervention comes a heightened awareness of potential complications and causes of surgical failure. ACLR failure can be grouped into 3 general categories: (1) failure caused by surgical technique, (2) failure caused by hostile biology, and (3) failure resulting from post-operative trauma.³ Of these categories, only technical failures can be prevented at the time of surgery. Tunnel malposition represents the most commonly reported technical error during ACLR, particularly inappropriate femoral tunnel placement. Precise anatomic placement of the anterior cruciate ligament (ACL) tunnels is crucial for sagittal stability and rotational control of the

injured knee. Several recent studies have shown that tunnel malposition is a common cause of both intraoperative complications and graft failure after ACLR.⁴⁻⁷

Anterior or superior femoral tunnel malposition can result in rotational laxity or graft impingement. However, more immediate consequences such as violation of the posterior femoral cortex and a lack of femoral graft fixation can result from a posteriorly placed femoral tunnel. A similar result can occur from over-reaming the femoral tunnel, which can inadvertently cause a breach of the posterolateral femoral cortex. These posterior or lateral cortical insults lead to a loss of graft containment and subsequent difficulty with secure graft fixation. It is critical to promptly recognize and appropriately treat this intraoperative error because the graft is at an increased risk of premature failure. Recognition of this complication and a comprehensive knowledge of strategies for alternative fixation are critical to performing a successful surgical procedure after posterior wall blowout.⁷⁻¹¹

Numerous salvage and fixation techniques have been described to address posterior cortical breach when the damage is too significant to continue with the planned fixation. Some of these include suspensory fixation with a cortical button, interference screw, or cross pin; over-the-top fixation; a 2-incision technique; and suspensory cortical fixation with a screw and washer post. Although each method has advantages and limitations, our preferred technique is suspensory cortical fixation with a screw and washer post because an intact posterior cortex is not needed, it can be performed in all

From The Steadman Clinic (J.J.M., T.J.M., A.R.V., R.F.L.); and the Steadman Philippon Research Institute (J.J.M., J.C., C.S.D., T.J.M., A.R.V., T.R.C., R.F.L.), Vail, Colorado, U.S.A.

The authors report the following potential conflict of interest or source of funding: Institution provided support by Arthrex, Ossur, Siemens, and Smith & Nephew. R.F.L. receives support from Arthrex; Smith & Nephew; Ossur; Health East, Norway; and an NIH R13 grant for biologics.

Received December 23, 2015; accepted February 2, 2016.

Address correspondence to Robert F. LaPrade, M.D., Ph.D., The Steadman Clinic, 181 W Meadow Dr., Ste 400, Vail, CO 81657, U.S.A. E-mail: rlaprade@sprivail.org

© 2016 by the Arthroscopy Association of North America
2212-6287/151216/\$36.00

<http://dx.doi.org/10.1016/j.eats.2016.02.003>

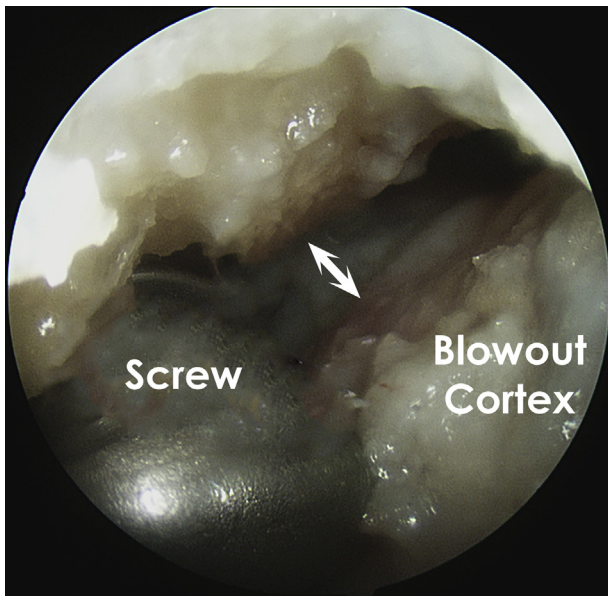


Fig 1. Violation of the posterior femoral cortex after screw insertion into the femoral tunnel as visualized through the anteromedial arthroscopic portal in a right knee. A representation of posterior wall blowout during anterior cruciate ligament reconstruction is shown in the upper left corner.

locations of cortical violation, both soft-tissue and bone-tendon-bone grafts can be used, and the instrumentation required for this technique is available at most centers without the need for specialized surgical equipment.^{12,13} The purpose of this technical note is to describe suspensory cortical fixation with a screw and washer post for fixation of the ACL graft in the setting of femoral cortical violation.

Surgical Technique

Indications

Once a substantial violation of the posterior femoral cortex has been confirmed (defined as loss of osseous posterior containment with lack of purchase of the femoral screw or under arthroscopic visualization), a salvage procedure should be performed to secure the graft in the femur (Fig 1). Conversion to a cortical fixation using suture suspension around a screw and washer post is the preferred method of the senior author (R.F.L.).

Patient Positioning and Anesthesia

For an ACLR, the patient is placed in a supine position with the injured leg in a leg holder (Mizuho OSI, Union City, CA), with the nonsurgical leg flexed, abducted, and held in an abduction holder (Birkova Products, Gothenburg, NE). A well-padded thigh tourniquet is subsequently placed on the upper thigh of the operative leg. The surgical leg is prepared and draped in the usual

sterile fashion, the leg is exsanguinated, and the tourniquet is inflated.

Surgical Approach

A standard ACLR is performed using anterolateral and anteromedial arthroscopic portals (Video 1). If significant violation of the femoral cortex is identified during reconstruction, the standard procedure is aborted and femoral fixation with a screw and washer post is begun. A lateral longitudinal incision is performed over the distal lateral femur centered on the lateral supracondylar ridge (Fig 2). Sharp dissection is performed down to the fascia overlying the iliotibial band. The iliotibial band is then longitudinally incised such that the vastus lateralis muscle can be elevated subperiosteally off of the lateral femur (Fig 3).

Careful dissection should be performed to expose the femoral tunnel on the posterolateral aspect of the femur and the sutures exiting the previously placed tunnel. A 3.2-mm drill is used with a starting position located posterior to the lateral intermuscular septum, aiming anteroproximally to avoid collision with the trochlea. A fully threaded 4.5-mm bicortical screw (Synthes, Paoli, PA) is placed through a 13-mm washer (Synthes) approximately 1 cm anterodistally to the femoral tunnel (so the pressure is shifted to the anterior aspect of the tunnel), near the metadiaphyseal flare of the femur (Fig 4).

After insertion of 80% of the screw length, the sutures holding the ACL graft are shuttled through the femoral tunnel under direct visualization and secured around the screw and washer. To build a stronger

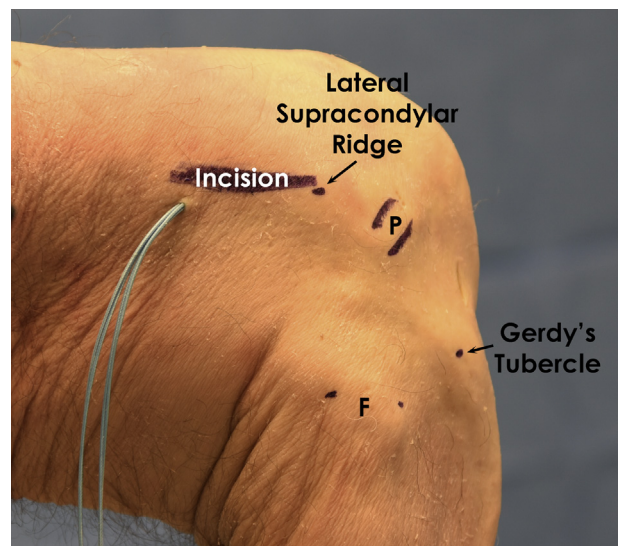


Fig 2. Anatomic landmarks for the skin incision after a posterior wall violation during anterior cruciate ligament reconstruction in a right knee. A longitudinal incision is performed over the lateral supracondylar ridge. (F, fibula; P, popliteus sulcus.)

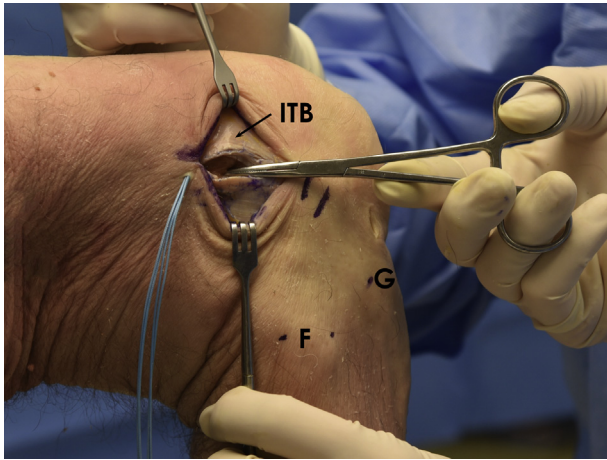


Fig 3. A longitudinal incision of the iliotibial band (ITB) over the lateral supracondylar ridge in a right knee. (F, fibula; G, Gerdy tubercle.)

construct, the limbs of 2 sutures are passed around each side of the screw and firmly tied beneath the washer (Fig 5).

The sutures should be adjusted to ensure an appropriate graft-tunnel match on both the femoral and tibial sides. The screw is secured such that the washer compresses the sutures against the lateral femoral cortex. Standard tibial fixation can then proceed as previously planned (Fig 6).

Once fixation is complete (Fig 7), the knee is assessed through a complete range of motion and anteroposterior laxity is evaluated with anterior drawer and Lachman tests. Pearls and pitfalls of this surgical technique are summarized in Table 1.

Postoperative Rehabilitation

Rehabilitation after ACLR should focus on progressive knee range of motion, weight bearing, prevention of anterior subluxation, and strengthening of the quadriceps musculature. All patients begin a supervised

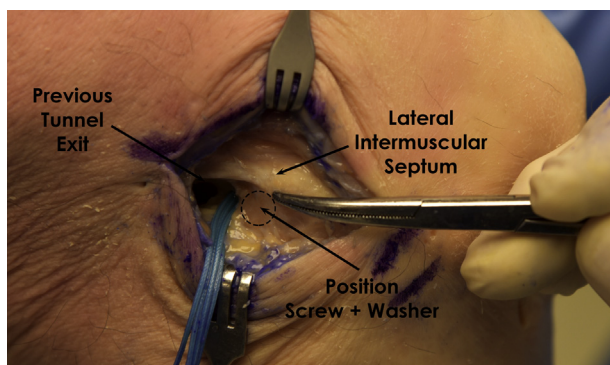


Fig 4. Previously placed tunnel with the sutures exiting the tunnel in a right knee. The lateral intermuscular septum constitutes an important landmark for placement of the screw and washer.

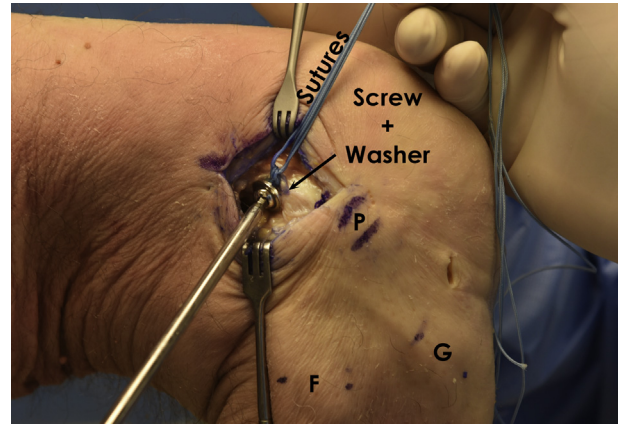


Fig 5. Cortical fixation with the screw and washer and the graft sutures tied beneath the washer in a right knee. (F, fibula; G, Gerdy tubercle; P, popliteus sulcus.)

physical therapy program on postoperative day 1 and are allowed range of motion as tolerated with emphasis on regaining full extension. Weight bearing as tolerated is permitted on the operative extremity immediately after surgery, and crutches are typically used for the first week until the patient can walk without a limp. The knee is initially placed in a knee immobilizer until quadriceps function returns, at which point the patient is transitioned into an ACL brace for 3 months postoperatively (CTi brace; Ossur, Reykjavik, Iceland).

Discussion

The most important point of this technical note is that recognition of posterior wall blowout is critical to achieving a good outcome. As understanding of the surgical management of ACL rupture increases, a heightened awareness of potential complications and causes of surgical failure follows.

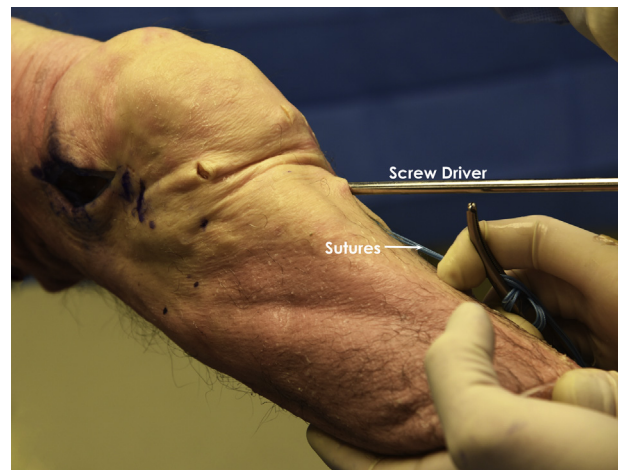


Fig 6. Standard tibial fixation for anterior cruciate ligament reconstruction after the femoral salvage procedure for posterior wall blowout in a right knee.

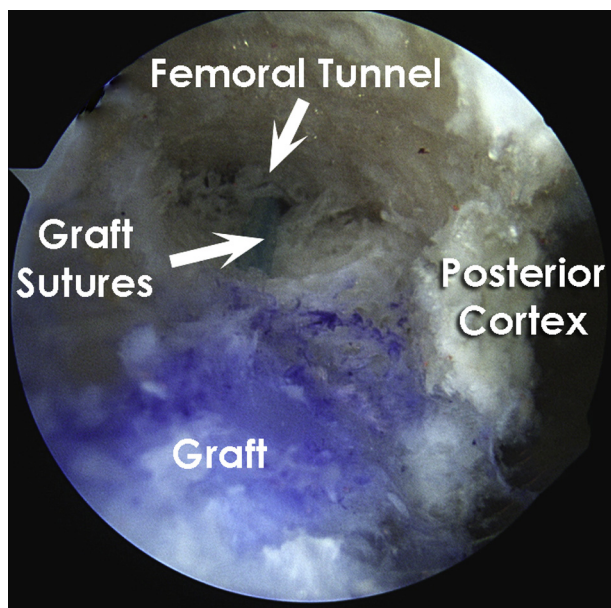


Fig 7. Arthroscopic view of a right knee showing a bone-tendon-bone graft within the femoral tunnel after suspensory cortical fixation after posterior wall blowout. The graft sutures can be seen attached to the femoral bone plug of the anterior cruciate ligament graft and traveling through the remaining femoral tunnel.

Successful outcomes in ACLR are dependent on tunnel positioning, graft tension at the time of surgery, and fixation technique.^{12,14} While performing ACLR, the surgeon may accidentally breach the posterior or lateral femoral cortex, and in these instances, immediate recognition and appropriate salvage methods are required.

Several techniques are available for management of posterior wall blowout that is not amenable to simple re-direction of the femoral tunnel. Authors have previously described the use of suspensory fixation with cortical buttons, cross-pin fixation, hybrid fixation using both suspension and interference techniques, and alteration of surgical technique to re-place the tunnel in a more advantageous position.^{12,13} Although each of these options is viable under certain instances, their utility is largely based on the ability of the devices to anchor over or within a previously reamed tunnel. For example, femoral tunnels are typically reamed to a diameter of at least 7 mm, and this diameter is approaching the upper limit of length available for standard cortical fixation in most devices.⁸ In these situations, specialized extended cortical suspension buttons are available in lengths up to 10 mm (XtendoButton; Smith & Nephew Endoscopy, Andover, MA).^{3,8,10} However, in revision settings with widened tunnels or in situations in which the femoral tunnel has blown out in an ovoid shape that is larger than 10 mm, these devices may not provide appropriate fixation.

Furthermore, many institutions do not have these devices readily available for such instances.

In situations in which the cortical breach is such that these devices are not large enough to be secured over the defect, suspensory fixation using a screw and washer post is recommended. The advantage of this method is that it is readily available in most centers and is technically straightforward. Furthermore, use of the suspensory post fixation allows for adjustment of the graft within the tunnel to avoid graft-tunnel mismatch on either the femoral or tibial side. Direct visualization of the placement of the screw and post on the lateral femur also ensures that the surgeon appropriately places the suspended sutures in the correct position. Limitations to this technique include having to make an extra incision, ensuring an appropriate graft and tunnel match, and needing a thorough knowledge of the surgical anatomy to appropriately position the lateral incision and the graft. [Table 2](#) shows a summary of advantages and limitations of this surgical technique.

The exact prevalence of posterior wall blowout in ACLR is difficult to determine because it is not clear how often such blowouts are recognized and treated intraoperatively versus how many remain undiagnosed and go on to later complications.³ Regardless of the exact number of occurrences, posterior wall blowout is an important potential source of ACLR failure. The risk of this complication can be mitigated if surgeons adhere to sound arthroscopic techniques and use appropriate vigilance in confirming anatomic tunnel placement with maintenance of an intact posterior wall.³ In the event of posterior wall blowout despite careful surgical planning and appropriate technique, it is critical to recognize the complication intraoperatively and use one of the described alternative salvage techniques to achieve stable femoral-sided fixation of the ACL graft.^{3,4,8,10,12,13}

Table 1. Pearls and Pitfalls

Pearls	
The most critical step to avoid posterior wall blowout is anatomic placement of the femoral tunnel.	
The location of the anatomic femoral attachments changes as the knee flexion angle changes, which is important for correct tunnel placement and avoiding breach of the posterior cortex.	
When placing the femoral screw, the surgeon should aim anteroproximally to avoid collision with the trochlea.	
To build a stronger construct, 2 sutures are passed around each side of the screw and firmly tied to the screw beneath the washer.	
Pitfalls	
Improper surgical technique remains one of the most common sources of failure of primary ACL reconstructions.	
If posterior wall compromise is not identified intraoperatively, this can lead to premature graft failure.	
It is essential to clear all overlying soft tissues when placing the femoral screw to ensure proper position.	
Failure to ensure an appropriate graft-tunnel match on both the femoral and tibial sides can result in improper graft placement.	

ACL, anterior cruciate ligament.

Table 2. Advantages and Limitations

Advantages	
Can be performed without an intact posterior cortex	
Specialized equipment not necessary	
Can be performed in all locations of cortical violation	
Compatible with soft-tissue and bone-tendon-bone grafts	
Limitations	
The need for an extra incision	
The need for appropriate judgment of graft position on the femoral side to avoid graft-tunnel mismatch	
Difficulty with lateral dissection in the setting of exuberant soft tissue	

Our recommended technique is to use salvage suspensory cortical fixation with a screw and washer post because it provides secure fixation in any area of cortical violation without the need for an intact posterior cortex.

References

1. Buller LT, Best MJ, Baraga MG, Kaplan LD. Trends in anterior cruciate ligament reconstruction in the United States. *Orthop J Sports Med* 2015;3:2325967114563664.
2. Lynch TS, Parker RD, Patel RM, et al. The impact of the Multicenter Orthopaedic Outcomes Network (MOON) research on anterior cruciate ligament reconstruction and orthopaedic practice. *J Am Acad Orthop Surg* 2015;23:154-163.
3. Rue JH, Busam ML, Detterline AJ, Bach Bernard R Jr. Posterior wall blowout in anterior cruciate ligament reconstruction—Avoidance, recognition, and salvage. *J Knee Surg* 2010;21:235-240.
4. Akhtar MA, Bhattacharya R, Ohly N, Keating JF. Revision ACL reconstruction—Causes of failure and graft choices. *Br J Sports Med* 2011;45:A15 (abstr).
5. Chen JL, Allen CR, Stephens TE, et al. Differences in mechanisms of failure, intraoperative findings, and surgical characteristics between single- and multiple-revision ACL reconstructions: A MARS cohort study. *Am J Sports Med* 2013;41:1571-1578.
6. Matava MJ, Arciero RA, Baumgarten KM, et al. Multi-rater agreement of the causes of anterior cruciate ligament reconstruction failure: A radiographic and video analysis of the MARS cohort. *Am J Sports Med* 2015;43:310-319.
7. Trojani C, Sbihi A, Djian P, et al. Causes for failure of ACL reconstruction and influence of meniscectomies after revision. *Knee Surg Sports Traumatol Arthrosc* 2011;19:196-201.
8. Herbort M, Heletta S, Raschke MJ, et al. Accidental perforation of the lateral femoral cortex in ACL reconstruction: An investigation of mechanical properties of different fixation techniques. *Arthroscopy* 2012;28:382-389.
9. Busam ML, Provencher MT, Bach BRJ. Complications of anterior cruciate ligament reconstruction with bone-patellar tendon-bone constructs: Care and prevention. *Am J Sports Med* 2008;36:379-394.
10. Hammond KE, Potini V, Dierckman BD, Xerogeanes JW, Labib SA. Femoral tunnel “blowout” during ACL reconstruction: A biomechanical analysis (SS-65). *Arthroscopy* 2011;27:e64-e65 (abstr).
11. Hammond KE, Dierckman BD, Potini VC, Xerogeanes JW, Labib SA, Hutton WC. Lateral femoral cortical breach during anterior cruciate ligament reconstruction: A biomechanical analysis. *Arthroscopy* 2012;28:365-371.
12. Kamelger FS, Onder U, Schmoelz W, Tecklenburg K, Arora R, Fink C. Suspensory fixation of grafts in anterior cruciate ligament reconstruction: A biomechanical comparison of 3 implants. *Arthroscopy* 2009;25:767-776.
13. Conner CS, Perez BA, Morris RP, Buckner JW, Buford WL, Ivey FM. Three femoral fixation devices for anterior cruciate ligament reconstruction: Comparison of fixation on the lateral cortex versus the anterior cortex. *Arthroscopy* 2010;26:796-807.
14. Beynon BD, Johnson RJ, Abate JA, Fleming BC, Nichols CE. Treatment of anterior cruciate ligament injuries, part 2. *Am J Sports Med* 2005;33:1751-1767.