

# A Novel Repair Method for Radial Tears of the Medial Meniscus

## Biomechanical Comparison of Transtibial 2-Tunnel and Double Horizontal Mattress Suture Techniques Under Cyclic Loading

Sanjeev Bhatia,<sup>\*†</sup> MD, David M. Civitarese,<sup>\*</sup> BA, Travis Lee Turnbull,<sup>\*</sup> PhD, Christopher M. LaPrade,<sup>\*</sup> BA, Marco Nitri,<sup>\*</sup> MD, Coen A. Wijdicks,<sup>\*</sup> PhD, and Robert F. LaPrade,<sup>\*†‡</sup> MD, PhD

*Investigation performed at the Department of BioMedical Engineering, Steadman Philippon Research Institute, Vail, Colorado, USA*

**Background:** Complete radial tears of the medial meniscus have been reported to be functionally similar to a total meniscectomy. At present, there is no consensus on an ideal technique for repair of radial midbody tears of the medial meniscus. Prior attempts at repair with double horizontal mattress suture techniques have led to a reportedly high rate of incomplete healing or healing in a nonanatomic (gapped) position, which compromises the ability of the meniscus to withstand hoop stresses.

**Hypothesis:** A newly proposed 2-tunnel radial meniscal repair method will result in decreased gapping and increased ultimate failure loads compared with the double horizontal mattress suture repair technique under cyclic loading.

**Study Design:** Controlled laboratory study.

**Methods:** Ten matched pairs of male human cadaveric knees (average age, 58.6 years; range, 48-66 years) were used. A complete radial medial meniscal tear was made at the junction of the posterior one-third and middle third of the meniscus. One knee underwent a horizontal mattress inside-out repair, while the contralateral knee underwent a radial meniscal repair entailing the same technique with a concurrent novel 2-tunnel repair. Specimens were potted and mounted on a universal testing machine. Each specimen was cyclically loaded 1000 times with loads between 5 and 20 N before experiencing a load to failure. Gap distances at the tear site and failure load were measured.

**Results:** The 2-tunnel repairs exhibited a significantly stronger ultimate failure load (median, 196 N; range, 163-212 N) than did the double horizontal mattress suture repairs (median, 106 N; range, 63-229 N) ( $P = .004$ ). In addition, the 2-tunnel repairs demonstrated decreased gapping at all testing states ( $P < .05$ ) with a final measured gapping of 1.7 mm and 4.1 mm after 1000 cycles for the 2-tunnel and double horizontal mattress suture repairs, respectively.

**Conclusion:** The 2-tunnel repairs displayed significantly less gapping distance after cyclic loading and had significantly stronger ultimate failure loads compared with the double horizontal mattress suture repairs.

**Clinical Relevance:** Complete radial tears of the medial meniscus significantly decrease the ability of the meniscus to dissipate tibiofemoral loads, predisposing patients to early osteoarthritis. Improving the ability to repair medial meniscal radial tears in a way that withstands cyclic loads and heals in an anatomic position could significantly improve patient healing rates and result in improved preservation of the articular cartilage of the medial compartment of the knee. The 2-tunnel repair may be a more reliable and stronger repair option for midbody radial tears of the medial meniscus. Clinical studies are warranted to further evaluate these repairs.

**Keywords:** medial meniscus repair; radial tear; 2-tunnel; mattress suture

Radial meniscal tears, oriented perpendicular to the meniscal axis, are common in active individuals and frequently occur in combination with anterior cruciate and multiligament knee injuries.<sup>4</sup> In an evaluation of 196 consecutive patients undergoing knee arthroscopy, Harper and colleagues<sup>11</sup> reported a 15% incidence of radial

meniscal tears, most of which were in the posterior third of the medial and lateral menisci. When complete radial tears of the medial meniscus occur, they significantly impair the ability of the meniscus to withstand tibiofemoral loads and have been described as being functionally equivalent to a total meniscectomy.<sup>2,16,17</sup> As such, radial meniscal tears of the medial meniscus have been reported to result in rapid joint degeneration when left untreated.<sup>1</sup>

Historically, patients with radial tears of the medial meniscus were treated with partial or total meniscectomies to alleviate pain symptoms. Some of these patients then proceeded to undergo meniscal transplantation to slow joint degeneration. However, given the inconsistent outcomes and high reoperation rate of meniscal transplantation,<sup>11</sup> especially in high-demand individuals, there has been a renewed push for repair of radial meniscal tears when possible.<sup>2</sup>

Current strategies for repair of radial meniscal tears involve either an all-inside horizontal mattress repair or an inside-out repair with single, double, or crossed horizontal mattress sutures.<sup>15</sup> Although some authors have reported favorable healing rates of the peripheral meniscus with these techniques,<sup>18</sup> other authors have reported an unacceptably low rate of meniscal healing, especially of the central, white-white zone of the meniscus.<sup>5</sup> To address the shortcomings of the current repair techniques, James and coauthors<sup>12</sup> described a novel technique for repair of a medial meniscal midbody radial tear that was used in a 29-year-old man. The technique used 2 transosseous tunnels and, upon second-look arthroscopy, was found to result in complete healing of not only the red-red and red-white zones of the meniscus but also the avascular or central portion. The authors theorized that improved meniscal healing may have occurred due to improved stability of the repair construct, the ability to anatomically restore the meniscus to its proper position, and biological factors that are inherent to using transosseous tunnels at the site of the repair.<sup>12</sup> Improved stability of meniscal repairs has long been purported as a favorable factor during the healing process of menisci and other musculoskeletal tissue.<sup>5,7</sup>

The purpose of the present study was to biomechanically compare a horizontal mattress inside-out suture technique for repair of radial meniscal tears, which is the current clinical standard, with an inside-out horizontal mattress suture repair construct augmented with a novel 2-tunnel transtibial technique. We hypothesized that the 2-tunnel method would result in decreased gapping and increased ultimate failure loads compared with the double horizontal mattress suture technique under cyclic loading.

## METHODS

Ten matched pairs of male human cadaveric knee specimens with an average age of 58.6 years (range, 48-66 years) were used for this investigation. Before inclusion of any specimen, visual inspection of the medial compartment of the knee was performed to ensure that meniscal and chondral tissue did not have any macroscopic signs of significant degeneration such as fibrillation or fragmentation. Each specimen was dissected so that only the tibia, medial meniscus, and medial capsule tissue remained. Each femur, along with cruciate ligament attachments, was separated, with care taken not to injure the anterior or posterior root attachments of the medial meniscus. After each tibia was potted in polymethyl methacrylate, a complete radial tear was created with a No. 15 scalpel blade at the junction of the posterior one-third and middle third of the medial meniscus. This location was consistent with the most commonly reported site of medial meniscal radial tears.<sup>4,11</sup>

## Surgical Technique

All mattress sutures were performed with 2-0 nonabsorbable meniscal sutures (FiberWire; Arthrex), consistent with currently described repair techniques and testing protocols.<sup>12,15</sup> The transtibial method used nonabsorbable No. 2 sutures (FiberWire) that were passed through 2 transosseous tunnels in addition to the mattress sutures. To ensure consistency between techniques and precision across all specimens, repairs were performed open—under direct visualization—in a manner consistent with clinical practice by a board-certified orthopaedic surgeon (S.B.).

The inside-out horizontal mattress radial repair was performed on 1 medial meniscus in each matched pair. The technique was similar to that described by Matsubara et al,<sup>15</sup> except that 2 horizontal inside-out sutures were placed on the superior surface of the meniscus and 2 additional inside-out sutures were placed on the inferior surface of the meniscus. This technique replicates the current standard of radial meniscal repair, which is also currently performed at our institution. Two horizontal mattress sutures were placed in an inside-out format through both the superior and inferior surfaces of the meniscus and the capsular tissue in a parallel configuration to allow a more balanced type of repair. For each edge of the radial tear, sutures pierced the meniscus 5 mm away from the tear site and 5 mm and 10 mm from the capsular junction (Figure 1). Sutures were tied on the capsular side.

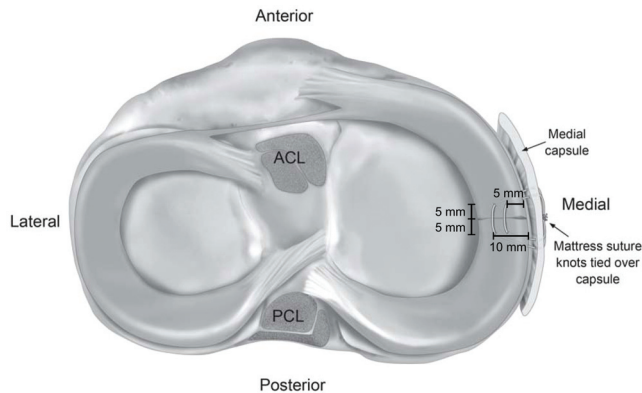
In the 2-tunnel crisscross repair group, the midbody radial repair was performed in the manner described by

<sup>‡</sup>Address correspondence to Robert F. LaPrade, MD, PhD, Steadman Philippon Research Institute, The Steadman Clinic, 181 West Meadow Drive, Suite 400, Vail, CO 81657 USA (email: drlaprade@sprivail.org).

\*Steadman Philippon Research Institute, Vail, Colorado, USA.

†The Steadman Clinic, Vail, Colorado, USA.

One or more of the authors has declared the following potential conflict of interest or source of funding: This study was sponsored by the Steadman Philippon Research Institute. R.F.L. receives royalties from Arthrex Inc, Smith & Nephew, and Ossur; is a paid consultant for Arthrex Inc, Ossur, and Smith & Nephew; and receives research support from Arthrex Inc, Smith & Nephew, Ossur, and Linvatec.



**Figure 1.** Superior view of a horizontal mattress suture repair of a medial meniscal radial midbody tear in a left knee. Tears occurring at the posterior and middle third junction of the medial meniscus are most common, and tears at this location were repaired with this technique in this study. ACL, anterior cruciate ligament; PCL, posterior cruciate ligament.

James et al<sup>12</sup> (Figure 2). After each radial tear edge was released, two 2.4-mm tunnels were placed at the meniscocapsular region of the tibia with the center of the tunnels located 5 mm apart. Each tunnel was created with the use of a sheathed drill and a 5-mm parallel drill guide (Smith & Nephew) with a technique described in a similar study evaluating 2-tunnel meniscal root repair.<sup>13</sup> Each torn edge of the meniscus was then sutured superoinferiorly at the posterior corner of the tear edge with a noncutting needle. A nitinol lasso was used to shuttle each No. 2 FiberWire suture in a crisscross fashion through the transosseous tunnels. Once the sutures were through the tunnels completely, the metal sheaths were extracted. Sutures were tied together over a button while the repair was directly visualized to ensure accurate reduction. Once the transosseous portion of the repair was

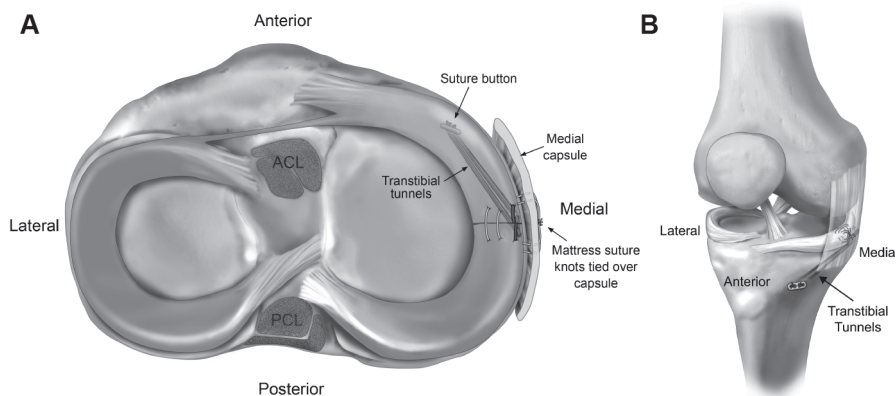
completed, 2 inside-out horizontal mattress sutures were placed on both the superior and inferior portion of the meniscus in the manner previously described.<sup>15</sup>

### Biomechanical Testing

In accordance with the methods of other studies<sup>17</sup> that have investigated meniscal strength after radial repair, each specimen was mounted on a universal testing machine (Instron E10000) after the posterior horn meniscal capsular tissue was dissected to within 15 mm of the repair construct and the posterior root was detached (Figure 3). Anterior meniscal tissue was left attached, as it is naturally secured to the tibia at the meniscocapsular junction and anterior root. A ligament staple was placed through the meniscus, 15 mm anterior to the tear site, to standardize the length of meniscal tissue on the anterior side of the repair subject to displacement during loading of each construct. Posterior horn meniscal tissue was secured to the universal testing machine by use of custom-made clamps according to a previously described technique.<sup>8</sup> To prevent slippage or rotation at the meniscus-clamp interface, 18-gauge sternal wire was wrapped around the posterior horn limb before clamping.<sup>8</sup> Posteriorly, the menisci were clamped a standardized 15 mm posterior to the tear site. Specimens were cyclically loaded between 5 and 20 N at 0.5 Hz for 1000 cycles and, after the completion of 1000 cycles, pulled to failure at a displacement rate of 30 mm/min as previously described in other protocols.<sup>15</sup>


### Gap Distance Measurement

Photographs of the tear site were obtained at 0, 10, 50, 100, 250, 500, and 1000 cycles with a high-resolution digital single lens reflex camera (Nikon USA) mounted on a tripod in order to obtain gap measurements via an image processing program (ImageJ; US National Institutes of Health) (Figure 4). Each high-resolution photograph was taken with

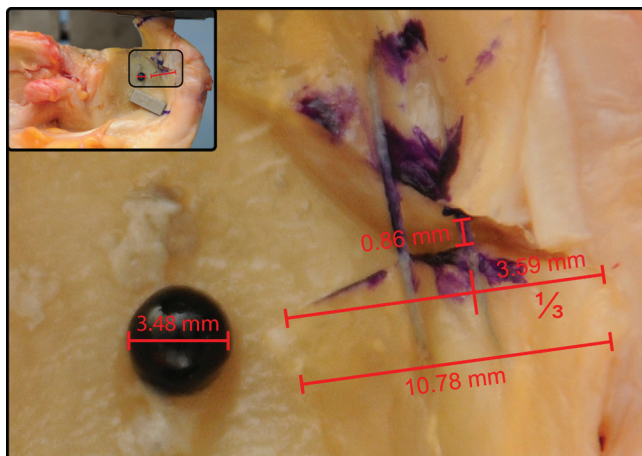


**Figure 2.** (A) Superior and (B) anteromedial view of transtibial 2-tunnel repair of a meniscal radial tear illustrating the crisscross transtibial tunnel technique in a left knee. Sutures were passed through an anterior and posterior tibial tunnel to the anteromedial cortex and tied together over a button. Tears occurring at the posterior and middle third junction of the medial meniscus are most common, and tears at this location were repaired with this technique in this study. ACL, anterior cruciate ligament; PCL, posterior cruciate ligament.





**Figure 3.** (A) Perspective view and (B) axial view of the mechanical testing setup with tensile force applied to the posterolateral meniscus. A ligament staple was used to standardize the length of meniscal tissue on the anterior side of the repair subject to displacement during loading of each construct. A calibration reference was used to determine the gap distance in conjunction with an image processing program. A, anterior; L, lateral; M, medial; P, posterior.

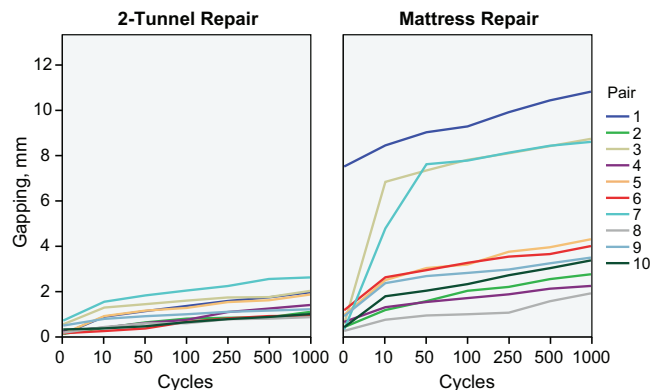


**Figure 4.** Example of the measurement technique for gap distance using a predetermined calibration reference (3.48 mm) to measure a distance that was one-third of the width from the meniscal rim (3.59 mm). The meniscal gap distance was subsequently measured (0.86 mm) at this point as the circumferential distance between the torn edges of the meniscus.

the camera stationary in the exact same position. Gap distance was determined by measuring the distance between the tear edges at one-half of the meniscal width from the peripheral meniscal rim. Two raters independently measured the gap distances to confirm both accuracy and precision of data collection.

### Statistical Analysis

Interrater reliability was assessed by use of the 2-way random effects, single measures, and absolute agreement



**Figure 5.** Mean gap distance measurements of 2-tunnel and mattress radial meniscal repair constructs during cyclic loading.

definition of the intraclass correlation coefficient (ICC). Group comparisons of gapping and ultimate failure strength between the mattress and 2-tunnel techniques were made by use of the Mann-Whitney *U* test. The Mann-Whitney *U* test compares mean ranks rather than means of the raw data; thus, it is more robust to extreme values.

### RESULTS

The gap distance measurements and ultimate failure loads are reported in Table 1. All repairs survived the cyclic loading protocol. During pull-to-failure testing, however, all repairs experienced failure at the site of the simulated radial tear. A significant difference ( $P < .05$ ) in gap distance between the 2 repair types was found at all cycles

TABLE 1  
Gap Distance at Various Cycles and Pull-to-Failure Values for Double Horizontal  
Mattress Repair and 2-Tunnel Repair Constructs

	Mattress Repair, Median (Range)	2-Tunnel Repair, Median (Range)	P Value <sup>a</sup>
Gapping at various cycles, mm			
0 cycle	0.7 (0.4-7.7)	0.3 (0.2-0.7)	.002 <sup>b</sup>
10 cycles	2.4 (1.3-8.0)	0.8 (0.4-1.6)	<.001 <sup>b</sup>
50 cycles	2.8 (1.5-8.9)	1.0 (0.4-1.9)	<.001 <sup>b</sup>
100 cycles	3.0 (1.5-9.2)	1.3 (0.7-2.0)	<.001 <sup>b</sup>
250 cycles	3.4 (1.6-10.2)	1.4 (0.8-2.1)	<.001 <sup>b</sup>
500 cycles	3.6 (2.2-10.5)	1.5 (0.8-2.3)	<.001 <sup>b</sup>
1000 cycles	4.0 (2.4-11.0)	1.7 (0.9-2.5)	<.001 <sup>b</sup>
Pull to failure, N	106 (63-229)	196 (163-212)	.004 <sup>c</sup>

<sup>a</sup>Mann-Whitney *U* test.

<sup>b</sup>Statistically significant difference in gap distance between repair techniques at all cycles ( $P < .005$ ).

<sup>c</sup>Statistically significant difference in pull-to-failure values between repair techniques ( $P < .005$ ).

for which gap measurements were recorded (0, 10, 50, 100, 250, 500, and 1000 cycles) (Figure 5 and Table 1), with the 2-tunnel repairs and double horizontal mattress suture resulting in 1.7 mm and 4.0 mm of gapping after 1000 cycles, respectively. Three specimens in the mattress group had visibly more gapping than the other specimens. These specimens had similar meniscal tissue quality as determined by visual inspection. The 2-tunnel repairs also exhibited a significantly stronger ultimate failure load (median, 196 N; range, 163-212 N) than did the double horizontal mattress suture repairs (median, 106 N; range, 63-229 N;  $P = .004$ ).

Interrater ICCs for gap distance measurements were 0.978 (95% CI, 0.941-0.989) and 0.544 (95% CI, 0.243-0.726) for the mattress and 2-tunnel groups, respectively. The maximum absolute measurement difference between the 2 raters was 1.57 mm and 1.96 mm for the 2-tunnel and mattress repair groups, respectively.

## DISCUSSION

The most important finding of this study was that the novel 2-tunnel radial tear repair technique reduced median gapping distance at the tear site by 2.3 mm compared with the horizontal mattress repair group after 1000 cycles of loading. The 2-tunnel radial repair constructs also had less biomechanical variability between repairs among the 10 specimens. Furthermore, the transtibial technique exhibited a higher average load to failure (196 N) than the mattress repair technique (106 N).

Gap distance has been studied at other musculoskeletal tissue repair sites and has been demonstrated to have a critical effect on the strength and viability of connective tissue repair constructs.<sup>21</sup> In an experimental study on the early stages of flexor tendon repairs in adult dogs, Gelberman et al<sup>9</sup> found that a gap at the repair site of more than 3 mm prevents the accrual of strength and stiffness that normally occurs with time. Additionally, the authors noted that repair constructs with increased gap distances were at a significantly higher risk for rerupture.<sup>9</sup> Even though their study

primarily pertained to flexor tendon repair, it nonetheless has important implications for meniscal midbody radial tears. Like flexor tendons, meniscal tissue has relatively poor vascularity, which is primarily present in the peripheral fibers of the collagen tissue. Moreover, healing of meniscal tissues is slow and likely requires a complement of both mechanical and biological factors for favorable healing rates.

Healing of radial meniscal tears has been challenging. Although an all-inside repair technique is technically easier than the method described in the current investigation, it has not resulted in favorable healing outcomes. In a retrospective review of 14 patients undergoing all-inside repair of a complete radial meniscal tear, Choi and colleagues<sup>5</sup> reported that only 35.7% of repaired constructs were fully healed on follow-up magnetic resonance imaging. Similarly, van Trommel and coauthors<sup>22</sup> described a case series in which only 3 of 5 radial meniscal repairs had excellent healing at second-look arthroscopy; of the these 3 patients, 2 patients still required subsequent partial meniscectomy to trim unhealed flaps of tissue. To decrease the need for further surgery, Haklar et al<sup>10</sup> recommended performing a partial meniscectomy of the inner portion of the meniscus while simultaneously performing a double inside-out horizontal mattress repair of radial midbody meniscal tears. Although the authors reported a high healing rate,<sup>10</sup> the partial meniscectomy may produce sequelae as a consequence of increased contact pressures in the medial compartment.<sup>2</sup>

In a biomechanical analysis, Bedi and colleagues<sup>2</sup> reported that radial tears involving at least 90% of the meniscal rim width cause a shift in the location of the peak contact pressures within the knee that cannot be reversed with an inside-out mattress suture repair technique. It was theorized that this alteration in the mechanical function of the meniscus after the inside-out mattress repair may be due to the inability of the mattress repair technique to restore the menisci's ability to withstand hoop stresses. Thus, in menisci with complete radial tears that have significant extrusion due to the violation of circumferential fibers, a mattress repair technique may not have the ability to functionally tighten the meniscal tissue back to its native shape.

The rationale for the development of this radial meniscal repair technique was based on advances in meniscal root and radial root tear repair techniques. The senior author (R.F.L.) theorized that each end of the radial meniscal tear could be treated as a separate root tear and that fixation through transtibial tunnels would enhance the stability of the construct.<sup>3,12,14</sup> Although this study primarily assessed the mechanical aspects of meniscal repair constructs in a cadaveric experimental model, there may be biological benefits to placing transosseous tunnels directly underneath a midbody meniscal repair construct that were not evaluated.<sup>6</sup> A transosseous tunnel may allow the extravasation of pluripotent mesenchymal cells from the bone marrow to bathe the repair construct in a manner that could augment healing rates. A similar phenomenon has been observed with rotator cuff healing when a robust bone marrow clot—the “crimson duvet”—is placed at the site of a single row repair construct.<sup>19</sup> Similar types of biological augmentation have been shown to have some promise in meniscal healing. Ra and colleagues<sup>18</sup> sutured a fibrin clot to radial meniscal tears being repaired with inside-out mattress sutures and observed that 6 of 7 menisci were completely healed on second-look arthroscopy. Thus, in addition to the biomechanical benefits of transosseous radial repair, biological advantages likely are present as well.

One of the most noteworthy characteristics of the transosseous 2-tunnel technique is that the medial meniscal repair construct essentially anchors the medial meniscal tissue to the proximal tibia. This type of repair likely does not have any negative implications for function given the inherently fixed position of the native medial meniscus.<sup>20</sup> The medial meniscus, as noted by various authors, is effectively immobile on the proximal tibia due to meniscocapsular attachments as well as attachments to the deep portion of the medial collateral ligament. Furthermore, any subtle meniscal mechanic differences in vivo that occur from translation are likely of minimal consequence compared with the likely alternative: a nonfunctional extruded meniscus or meniscectomy secondary to a complete nonhealing medial meniscal radial tear, both of which dramatically increase joint reactive loads of the medial compartment. Additional studies are necessary to determine any potential tethering and its effect on meniscal mechanics, especially if this technique is extended to the lateral meniscus, which has been reported to have more mobility with knee motion.

The ICC of the gap distance measurements between the 2 groups was high, particularly for the horizontal mattress group, demonstrating the consistent differences in gapping with either technique. While the interrater agreement as assessed by ICC appeared worse among the 2-tunnel measurements, we noted that the average bias was 0.4 mm and the largest single discrepancy between raters was 1.6 mm. Neither of these values was larger in millimeter units than the measurement discrepancies found for the mattress suture group. Therefore, we conclude that this measurement is accurate to a clinically acceptable threshold and that the lower ICC for the 2-tunnel group is a consequence of the measurement error being larger relative to the magnitude of the measurement itself.

Although mechanical differences were observed, limitations are inherent to the study design. The most noteworthy limitation is that this was a controlled biomechanical study. Thus, it is impossible to extrapolate the true effects of the measured and reported gap distances and load to failure to in vivo healing rates. Nevertheless, based on prior published work, an improved biomechanical profile of repair constructs likely improves connective tissue healing, particularly at less vascular sites in the body.<sup>9,21</sup> In addition, it is recognized that the increased strength of the transtibial tunnel repair is somewhat due to the increased number of sutures in the overall meniscal repair. However, we believe that the configuration of the transtibial tunnel sutures, which was in line with the vector of the applied force, is primarily responsible for this increase in construct force.

## CONCLUSION

The 2-tunnel, transosseous, medial meniscal radial repair constructs demonstrated significantly less gapping with cyclic loading and had significantly stronger ultimate failure loads than the double horizontal mattress suture repairs. This improved biomechanical profile, and the potential biological benefits of transosseous tunnel placement at the repair site, may augment radial repair healing rates. We recommend that clinical studies be performed to further evaluate these repairs.

## ACKNOWLEDGMENT

The authors thank Angelica Wedell and Barry Eckhaus for providing medical photography and Grant J. Dornan, MSc, for assistance with statistical analysis.

## REFERENCES

1. Badlani JT, Borrero C, Golla S, Harner CD, Irrgang JJ. The effects of meniscus injury on the development of knee osteoarthritis: data from the osteoarthritis initiative. *Am J Sports Med*. 2013;41(6):1238-1244.
2. Bedi A, Kelly NH, Baad M, et al. Dynamic contact mechanics of the medial meniscus as a function of radial tear, repair, and partial meniscectomy. *J Bone Joint Surg Am*. 2010;92(6):1398-1408.
3. Bhatia S, LaPrade CM, Ellman MB, LaPrade RF. Meniscal root tears: significance, diagnosis, and treatment. *Am J Sports Med*. 2014; 42(12):3016-3030.
4. Bin SI, Kim JM, Shin SJ. Radial tears of the posterior horn of the medial meniscus. *Arthroscopy*. 2004;20(4):373-378.
5. Choi NH, Kim TH, Son KM, Victoroff BN. Meniscal repair for radial tears of the midbody of the lateral meniscus. *Am J Sports Med*. 2010;38(12):2472-2476.
6. de Girolamo L, Galliera E, Volpi P, et al. Why menisci show higher healing rate when repaired during ACL reconstruction? Growth factors release can be the explanation. *Knee Surg Sports Traumatol Arthrosc*. 2015;23(1):90-96.
7. Durselen L, Heibisch A, Claes LE, Bauer G. Gapping phenomenon of longitudinal meniscal tears. *Clin Biomech (Bristol, Avon)*. 2003; 18(6):505-510.
8. Ellman MB, LaPrade CM, Smith SD, et al. Structural properties of the meniscal roots. *Am J Sports Med*. 2014;42(8):1881-1887.

9. Gelberman RH, Boyer MI, Brodt MD, Winters SC, Silva MJ. The effect of gap formation at the repair site on the strength and excursion of intrasynovial flexor tendons: an experimental study on the early stages of tendon-healing in dogs. *J Bone Joint Surg Am.* 1999;81(7): 975-982.
10. Haklar U, Kocaoglu B, Nalbantoglu U, Tuzuner T, Guven O. Arthroscopic repair of radial lateral meniscus [corrected] tear by double horizontal sutures with inside-outside technique. *Knee.* 2008;15(5): 355-359.
11. Harper KW, Helms CA, Lambert HS III, Higgins LD. Radial meniscal tears: significance, incidence, and MR appearance. *AJR Am J Roentgenol.* 2005;185(6):1429-1434.
12. James EW, LaPrade CM, Feagin JA, LaPrade RF. Repair of a complete radial tear in the midbody of the medial meniscus using a novel crisscross suture transtibial tunnel surgical technique: a case report. *Knee Surg Sports Traumatol Arthrosc.* 2015;23(9):2750-2755.
13. LaPrade CM, LaPrade MD, Turnbull TL, Wijdicks CA, LaPrade RF. Biomechanical evaluation of the transtibial pull-out technique for posterior medial meniscal root repairs using 1 and 2 transtibial bone tunnels. *Am J Sports Med.* 2015;43(4):899-904.
14. LaPrade RF, LaPrade CM, James EW. Recent advances in posterior meniscal root repair techniques. *J Am Acad Orthop Surg.* 2015; 23(2):71-76.
15. Matsubara H, Okazaki K, Izawa T, et al. New suture method for radial tears of the meniscus: biomechanical analysis of cross-suture and double horizontal suture techniques using cyclic load testing. *Am J Sports Med.* 2012;40(2):414-418.
16. Messner K, Gao J. The menisci of the knee joint: anatomical and functional characteristics, and a rationale for clinical treatment. *J Anat.* 1998;193(pt 2):161-178.
17. Ode GE, Van Thiel GS, McArthur SA, et al. Effects of serial sectioning and repair of radial tears in the lateral meniscus. *Am J Sports Med.* 2012;40(8):1863-1870.
18. Ra HJ, Ha JK, Jang SH, Lee DW, Kim JG. Arthroscopic inside-out repair of complete radial tears of the meniscus with a fibrin clot. *Knee Surg Sports Traumatol Arthrosc.* 2013;21(9):2126-2130.
19. Snyder SJ, Burns J. Rotator cuff healing and the bone marrow "crimson duvet" from clinical observations to science. *Tech Shoulder Elbow Surg.* 2009;10(4):130-137.
20. Stein G, Koebke J, Faymonville C, Dargel J, Muller LP, Schiffer G. The relationship between the medial collateral ligament and the medial meniscus: a topographical and biomechanical study. *Surg Radiol Anat.* 2011;33(9):763-766.
21. Tamboli M, Mihata T, Hwang J, McGarry MH, Kang Y, Lee TQ. Biomechanical characteristics of the horizontal mattress stitch: implication for double-row and suture-bridge rotator cuff repair. *J Orthop Sci.* 2014;19(2):235-241.
22. van Trommel MF, Simonian PT, Potter HG, Wickiewicz TL. Arthroscopic meniscal repair with fibrin clot of complete radial tears of the lateral meniscus in the avascular zone. *Arthroscopy.* 1998;14(4):360-365.

---

For reprints and permission queries, please visit SAGE's Web site at <http://www.sagepub.com/journalsPermissions.nav>.