

Snapping biceps femoris tendon treated with an anatomic repair

Andrew S. Bernhardson · Robert F. LaPrade

Received: 14 September 2009 / Accepted: 1 December 2009
© Springer-Verlag 2009

Abstract Three patients were seen for pain and snapping over the lateral aspect of their symptomatic knee during deep knee flexion. On physical examination, each patient had subluxation of the long head of the biceps over the lateral aspect of the fibular head. Each patient underwent an anatomic repair of the torn anterior arms of the short and long biceps femoris to their anatomic insertion sites with suture anchors. All patients had normal return of function without pain or further subluxation events.

Keywords Subluxating biceps femoris · Snapping biceps · Lateral knee pain · Anatomic repair

Introduction

Diagnosing snapping biceps tendons can be an enigma. Patients present with an audible and visible snapping of the biceps tendon over the lateral aspect of the fibular head. The etiology of these symptoms is often not recognized, and patients may have their pathology go undiagnosed due to a paucity of literature about this subject.

There have been few reports of snapping biceps femoris tendons in the literature. Most often patients have been reported to present with symptoms of painful snapping knees without a history of trauma. Diagnosis has been primarily performed by physical examination, with MRI

yielding only minimal information. Differing surgical approaches have been described to resolve the symptoms after conservative non-operative treatment has failed, which have included excision of the fibular head or relocation of the long head biceps femoris insertion [1–7, 10].

Case reports

Case 1: A 28-year-old man was referred by his primary care provider to our sports institute for evaluation of right knee pain. The first time he noted any symptoms was 18 months prior to presentation when he noted a sensation of locking over the lateral aspect of his right knee after performing a deep squat. He reported a nauseating feeling of something subluxating over the lateral aspect of his right knee when performing deep squats. Sitting in low seats also reproduced his symptoms. An audible and painful pop was noted when the tendon relocated when he arose from a deep squatting position.

On physical examination, his knee range of motion was symmetric bilaterally. He had pain to palpation over the fibular collateral ligament-biceps bursa [8] and the lateral aspect of the fibular styloid. He did not have pain over his lateral joint line or when his knee was placed into a figure-of-four position [9]. When performing a deep squat, the long head of his biceps femoris subluxed over the lateral aspect of the fibular head. When holding his biceps common tendon reduced by applying manual pressure to the tendon where it crossed the fibular head, he did not have the nauseating sensation or any subluxation of the biceps tendon. A right knee MRI was obtained to evaluate any other possible concurrent knee pathology to explain his symptoms. The MRI revealed mild thickening of the long head of the biceps femoris tendon with concurrent tears of

A. S. Bernhardson · R. F. LaPrade (✉)
Department of Orthopaedic Surgery,
University of Minnesota Biomechanics Laboratory,
University of Minnesota, 2450 Riverside Avenue South, R200,
Minneapolis, MN 55454, USA
e-mail: lapra001@umn.edu
URL: <http://www.sportsdoc.umn.edu>

the direct arms of the long and short heads of the biceps femoris off their fibular attachments, and no other intra-articular pathology was noted.

The impression drawn from his clinical examination and imaging studies was a subluxating long and short head of the biceps femoris due to a tear of the direct arm attachments to the lateral aspect of the fibular styloid. Having failed to have symptom control with non-operative treatment, the patient elected to go forward with surgical management by reattaching the direct arms of his biceps femoris to his fibular styloid with suture anchors.

Case 2: A 43-year-old woman presented with an almost 2-year history of left knee pain. She reported the most painful activity for her was squatting. She reported popping over the lateral aspect of her knee near her fibular head when she performed a deep squat or with deep stepping activities. She reported that it “feels like a ligament slips.” Examination of her left knee when squatting revealed a visible and audible subluxation of the long head of her biceps femoris over the lateral aspect of her fibular head with deep squatting. Manual palpation of her common biceps tendon at the fibular head held it reduced and prevented it from subluxating over the lateral aspect of her fibular head. An MRI of her left knee revealed no evidence of any lateral compartment knee pathology and a tear of the direct arms of the long and short heads of the biceps femoris off the fibular styloid.

Case 3: A 41-year-old woman also presented to the sports clinic with a 6-month history of atraumatic knee pain and an audible and visible snapping sensation on the lateral side of her right knee. She noted the snapping sensation when squatting or dancing. She had no history of trauma to her right knee, and her other knee ligaments were stable. On physical examination, she was noted to have a painful subluxation of the common biceps tendon when she performed a deep squat. Manual reduction through applying force to the biceps tendon at the fibular head also eliminated her painful snapping. Her right knee MRI scan revealed that her long and short heads of the biceps were torn from their attachments on the fibular styloid. She also elected to have surgery.

Surgical treatment

All patients elected to have surgery. Intraoperatively, it was noted that the long and short heads of the biceps femoris were torn from their fibular attachments in all cases (Fig. 1). Also, it was noted that the common biceps tendon was loose and subluxable along the lateral aspect of the fibular styloid and fibular head rather than fixed at its normal attachment along the posterolateral aspect of the fibular styloid. The normal anatomic sites for the insertion

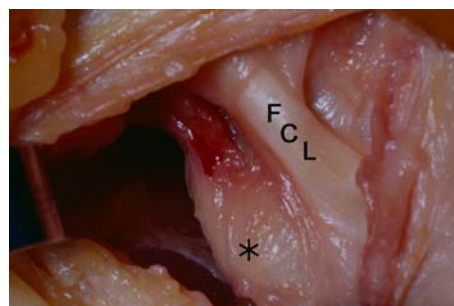


Fig. 1 The torn direct arms of the biceps femoris were visualized after dissection, and the lateral aspect of the fibular styloid was exposed prior to suture anchor placement (*lateral view, right knee*)

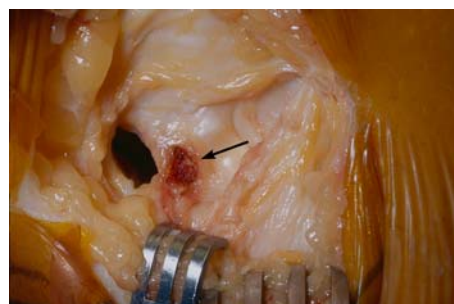


Fig. 2 After the normal attachment site of the direct arms of the long and short heads of the biceps femoris have been identified, the lateral aspect of the fibular head was identified using blunt dissection and electrocautery (*lateral view, right knee*)

of the direct arms of the short and long heads of the biceps were identified, and the area was cleared of soft tissue in preparation for reattachment (Fig. 2). Two suture anchors were placed on the lateral aspect of the fibular styloid, and the short and long heads of the biceps were each repaired back separately to the posterolateral aspect of the fibular styloid. For rehabilitation, patients were limited to toe touch weight bearing for 6 weeks. At 6 weeks they were allowed to use a stationary bike, and only after 3 months were isolated hamstring exercises allowed. All patients had normal function and no further subluxation episodes at a minimum of 1 year of follow-up.

Discussion

The most important finding of the present study was that an anatomic repair of snapping biceps tendons was successful in treating this pathology. In all cases, patients with snapping biceps tendons presented with both audible and visible subluxation of the common biceps tendon on the lateral aspect of the fibular head while performing a deep squat or with activities which involved deep knee flexion. In all patients, manual palpation was able to reduce or eliminate

the painful subluxation of the biceps tendon over the lateral aspect of the fibular head. This helped to verify that the pathology was extra-articular and not due to a subluxating lateral meniscus or a tear of the popliteomeniscal fascicles [9]. When reviewing MRI scans from each patient, the commonality noted was the appearance of tears of the biceps tendon from each head's attachment site. An anatomic repair of the symptomatic subluxating biceps femoris tendon yielded excellent results with complete resolution of symptoms in three patients.

Previous reports have described cases of snapping biceps femoris tendons. Some authors have performed fibular head resection [1, 2, 4, 7] while other reports advocate anatomic repositioning if there are no bony abnormalities [3, 6]. The second and third patients were unique in the fact that all previously reported snapping biceps femoris tendons were in active male patients younger than 25 [3].

Normally, the tendon of the long head of the biceps femoris tendon divides into two main segments at the knee, the anterior arm and the direct arm [8]. The direct arm inserts on the posterolateral edge of the fibular head and the anterior arm inserts on the lateral edge of the fibular head where it then crosses lateral to the fibular collateral ligament [11]. The short head of the biceps femoris also has a direct arm which inserts on the fibular styloid, lateral to the tip of the styloid process [11]. The main components of the common biceps tendon which keep it attached to the fibular styloid are the direct arms of the long and short heads. In our patients with a snapping biceps tendon, the direct arms of both the long and short biceps femoris were not attached and resulted in painful subluxation over the lateral aspect of the fibula when the patients performed activities which resulted in deep knee flexion. The lack of the normal attachment of the direct arms to the fibular resulted in the entire common biceps tendon subluxing over the lateral aspect of the fibular head. The anatomic repair that was performed in these patients resulted in a complete resolution of their symptoms.

Conclusions

In conclusion, we recommend an anatomic repair of the direct arms of the long and short heads of the biceps

femoris back to the fibular styloid for symptomatic snapping biceps femoris tendons. Snapping biceps tendons can be difficult to diagnose, and present with patient complaints of a snapping sensation, due to lateral subluxation and a visible, and often audible, subluxation of the common biceps tendon over the lateral aspect of the fibular head. Holding direct pressure along the long and short heads of the common biceps tendons can help to prevent its clinical subluxation and assist in its diagnosis. Unless there are bony abnormalities, we believe that an anatomic repair of the direct arms of the long and short heads of the biceps femoris to the posterolateral aspect of the fibular styloid is the optimum surgical treatment for this condition.

References

1. Bach BR, Minihane K (2001) Subluxating biceps femoris tendon: an unusual case of lateral knee pain in a soccer athlete. *Am J Sports Med* 29:93
2. Bagchi K, Grelsamer RP (2003) Partial fibular head resection for bilateral snapping biceps femoris tendon. *Orthopedics* 26:1147–1149
3. Bansal R, Taylor C, Pimpalnerkar AL (2005) Snapping knee: an unusual biceps femoris tendon injury. *Knee* 12:458–460
4. Fung DA, Frey S, Markbreiter L (2008) Bilateral Symptomatic snapping biceps femoris tendon due to fibular exostosis. *J Knee Surg* 21:55–57
5. Hernandez JA, Rius M, Noonan KJ (1996) Snapping knee from anomalous biceps femoris tendon insertion: a case report. *Iowa Orthop J* 16:161–163
6. Kissnerberth MJ, Wilckens JH (2000) The snapping biceps femoris tendon: case report. *Am J Knee Surg* 13:25–28
7. Kristensen G, Nielsen K, Blyme PJ (1989) Snapping knee from biceps femoris tendon. A case report. *Acta Orthop Scand* 60:621
8. LaPrade RF, Hamilton CD (1997) The fibular collateral ligament-biceps femoris bursa. An anatomic study. *Am J Sports Med* 25:439–443
9. LaPrade RF, Konowolchuk BK (2005) Popliteomeniscal fascicle tears causing symptomatic lateral compartment knee pain: diagnosis by the figure-4 test and treatment by open repair. *Am J Sports Med* 33:1231–1236
10. Lokiec F, Velkes S, Schindler A, Pritsch M (1992) The snapping biceps femoris syndrome. *Clin Orthop Relat Res* 283:205–206
11. Terry GC, LaPrade RF (1996) The posterolateral aspect of the knee. Anatomy and surgical approach. *Am J Sports Med* 24:732–739