

CASE REPORTS

SKIN NECROSIS WITH MINIDOSE WARFARIN USED FOR PROPHYLAXIS AGAINST THROMBOEMBOLIC DISEASE AFTER HIP SURGERY

Robert F. LaPrade, MD
Bradley L. Fowler, MD
Thomas G. Ryan, MD

Warfarin sodium is one of the most commonly prescribed oral anticoagulants. It has been proven to be an effective agent in the prophylaxis of thromboembolic disease and fatal pulmonary embolism in total joint arthroplasty and emergency hip fracture surgery.¹⁻³ A rare, undesirable side effect of warfarin is skin necrosis.

The authors present a case of skin necrosis after use of warfarin for prophylaxis against thromboembolic disease after surgery. To the authors' knowledge, this is only the second case in the orthopedic literature of this complication when warfarin was used for prophylaxis against thromboembolic disease.⁴

CASE REPORT

A 69-year-old woman presented to the emergency room complaining of left hip pain after tripping and falling at home. On physical examination she was noted to be mildly obese with shortening and external rotation of her left lower extremity. Radiographs demonstrated a subtrochanteric hip fracture. Initial laboratory values showed a hemoglobin of 11.4 gm/dl; hematocrit 34.3; prothrombin time 11.4 seconds (control 10.9 seconds); and a partial thromboplastin time of 21.2 seconds. An open reduction and internal fixation of the left hip fracture was performed with a compression screw and 12-hole side plate 36 hours after injury.

Minidose warfarin sodium was initiated for prophylaxis against deep venous thrombi on the first postoperative day. Initial doses were 5 mg for the first 2 days, then 2.5 mg per day for subsequent doses. Physical therapy was initiated on day 2. On day 5 the left thigh became edematous anteromedially with a small purpuric region centrally. The operative incision was noted to be clean and dry. Warfarin sodium was discontinued. An angiodynogram of the left leg was normal. Her hemoglobin was 10.2 gm/dL and the prothrombin time was 17.0

seconds (control 11.5). By day 7 the purpuric region was 15 cm in diameter with several large bullae. The bullae were noted to have ruptured by day 11 and some central areas of necrosis were noted. Further necrosis and eschar formation developed over the next week (Fig 1).

A debridement and split thickness skin graft was performed 37 days after hip surgery. A full thickness skin loss, which went deeply into the adipose tissues, was present. Histologic examination of the debrided tissues showed venous thrombi with associated adipose necrosis and acute inflammatory changes (Fig 2). A diagnosis of warfarin sodium necrosis was made. A protein C level was found to be normal at 4.7 µg/mL (normal range 2.5 to 5.6). Her skin grafts and hip fracture healed well and she was ambulatory without discomfort 18 months later (Fig 3).

DISCUSSION

Warfarin sodium, a Coumadin derivative, has been used in the prophylaxis and treatment of thromboembolic disease since first described by Allen et al⁵ in 1942. It has been demonstrated to be useful in this setting because it impairs the vitamin K dependent biosynthesis of factors II, VII, IX, and X in the extrinsic clotting pathway. In addition, warfarin has a relatively rapid onset of action and a relatively stable oral maintenance dose. Its effectiveness in anticoagulation is easily measured by following prothrombin activity. Presently it appears that the most effective method of deep venous thrombus prophylaxis is the use of warfarin sodium to maintain the prothrombin time at levels of 1.2 to 1.5 times control.^{1,2}

Warfarin-induced skin necrosis is quite rare. It has been estimated to occur in 0.1% of patients.⁶ The case of warfarin necrosis seen in this patient was similar to cases previously described. The lesions usually occur in obese patients in areas of abundant adipose tissue, such as the breasts, thighs, or buttocks.⁶⁻⁷ The etiology of warfarin-induced skin necrosis is still unknown. Its treatment is supportive. Depending on its severity, the eschar may slough and the lesion may subside without further treatment, heal by granulation, require debridement and skin grafting, or even require amputation in severe cases.

Warfarin necrosis is probably seen more frequently than realized. Because this entity is

Fig 1: Photograph of left anterior thigh 12 days after ORIF of the left subtrochanteric hip fracture demonstrating bullae rupture, central necrosis, and eschar formation from warfarin-induced skin necrosis.

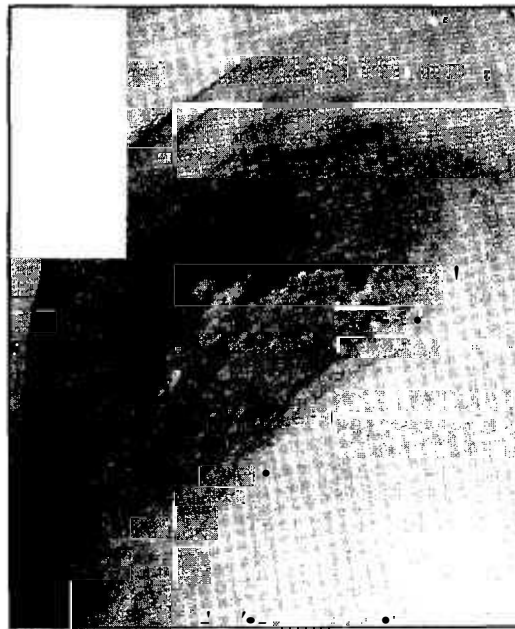


Fig 2: Photograph of left thigh lesion (hematoxylin & eosin, [A] x 100; [B] x 200). Venous thrombi, adipose tissue necrosis, and neutrophilic/lymphocytic invasion consistent with a diagnosis of warfarin-induced skin necrosis.




Fig 2A.

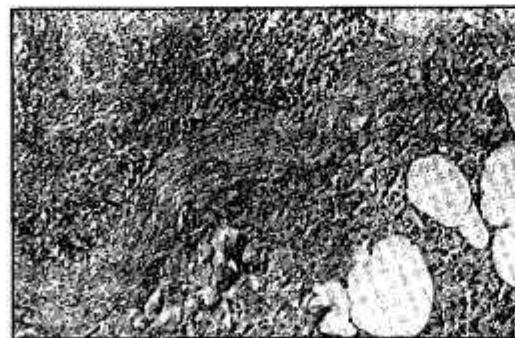
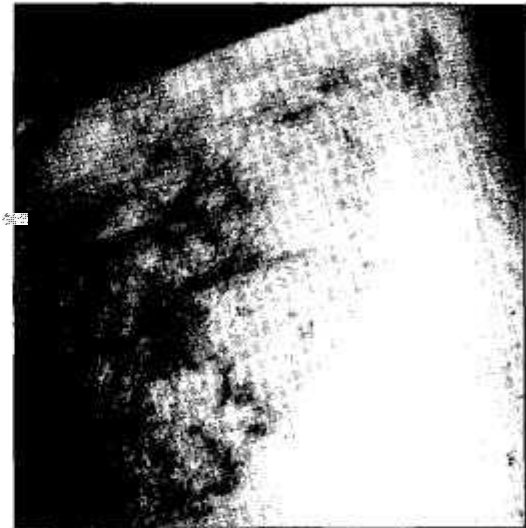


Fig 2B.

almost unknown in the orthopedic literature, it is probably misdiagnosed in its less serious stages, and a high level of suspicion needs to be maintained to recognize the entity in its more subtle stages since it may be interpreted as a hemorrhagic effect or pressure sore. In fact, since this initial case was seen, two additional cases, one involving the dorsum of the foot and the other the posterior calf, were seen in this community.

The authors have presented a case of warfarin

Fig 3: Photograph of left anterior thigh demonstrating healing of split thickness skin grafts at 6 months after debridement of warfarin-induced skin necrosis.



skin necrosis which appeared to have been an idiopathic reaction by warfarin used prophylactically to prevent thromboembolic disease after hip surgery. This case illustrates one of the more rare and least known, but more serious, side effects of anticoagulation treatment. It is stressed that this possible side effect of warfarin use needs to be recognized as a possible consequence when warfarin is utilized in this setting.

REFERENCES

1. Amstutz HC, Friscia DA, Dorey F, Carney BT. Warfarin prophylaxis to prevent mortality from pulmonary embolism after total hip replacement. *J Bone Joint Surg.* 1989; 71A:321-326.
2. Guyer RD, Booth RE, Rothman RH. The detection and prevention of pulmonary embolism in total hip replacement. *J fl<w Joint Surg.* 1982; 62A:1040-1044.
3. Morris GK, Mitchell GR. Warfarin sodium in prevention of deep venous thrombosis and pulmonary embolism in patients with fractured neck of femur. *Lancet.* 1976; 2:869-872.
4. Hal BS, Gurba DM. Coumadin-induced necrosis of the skin after total knee replacement. *J Bone Joint Surg.* 1991; 73A:129-130.
5. Allen EV, Barker NW, Waugh JM. A preparation from spoiled sweet clover which prolongs coagulation and prothrombin time of the blood. *JAMA.* 1942; 120:1009-1015.
6. Dominic W, Hansbrough JF, Field JD, Carroll \VG. Warfarin-induced skin necrosis; an entity occasionally requiring burn wound expertise. *Burns.* 1988; 14:139-141.
7. Nalbandian RM, Mader IJ, Barrett JL, Pearce JF, Rupp EC. Petechiae, ecchymoses, and necrosis of skin induced by coumadin congeners. *JAMA.* 1965; 192:107-112.

From Michigan State University, Kalamazoo Center for Medical Studies, Kalamazoo, Mich.
Reprint requests: Robert F. LaPrade, MD, 1535 Gull Rd, Ste 230. Kalamazoo, MI 49001.