

Posterior Root Avulsion Fracture of the Medial Meniscus in an Adolescent Female Patient With Surgical Reattachment

Chad J. Griffith,* Robert F. LaPrade,*[†] MD, PhD, Hollis M. Fritts,[‡] MD, and Patrick M. Morgan,* MD

From the *Department of Orthopaedic Surgery, University of Minnesota, Minneapolis, Minnesota, and the [‡]Center for Diagnostic Imaging, Saint Louis Park, Minnesota

Keywords: meniscal root avulsion; meniscal ossicle; meniscal repair; medial meniscus

The attachment of the posterior horn of the medial meniscus has been shown to be essential in maintaining normal meniscal positioning and function, as well as preventing extrusion of the medial meniscus.⁶ Traumatic avulsion fractures of the posterior horn of the medial meniscus, also referred to as meniscal ossicles, have been previously described in case reports.^{1,8,9,12,13} The literature has suggested that meniscal ossicles could arise from multiple causes, including trauma,^{3,12,15} metaplastic ossification,¹⁶ or a sesamoid bone.^{5,14} Regardless of cause, there has also been no agreement regarding treatment of these meniscal ossicles. A previous review found that the majority of physicians chose to initially treat these cases conservatively; however, many of the cases went on to require arthrotomy or arthroscopy with meniscectomy because of persistent symptoms.¹⁰ To our knowledge, this is only the second case report describing surgical reattachment of a bony avulsion fracture of the posterior horn root of the medial meniscus.¹²

CASE REPORT

A 16-year-old, white, female patient twisted her left knee during a high school basketball game. She had immediate onset of pain, followed by an effusion the following day. The patient was unable to participate in any competition for 3 weeks after the injury; before the injury, she played year-round high-level youth basketball on school and club teams. She had no previous history of injury to her left knee.

Three weeks after her injury, her physical examination revealed mild tenderness to palpation over her medial joint line with significantly increased tenderness over the postero-medial joint area. Deep squatting reproduced the deep posterior knee pain. There was no tenderness to palpation over the lateral joint line. The rest of her knee examination was normal, with no effusion, no increased joint line opening to varus or valgus stress at 30° of knee flexion, and negative Lachman, posterior drawer, and pivot-shift tests. Her left knee range of motion was 5° to 140°. She had normal patellar tracking through a normal range of motion, but she did have mild crepitation with translation of the patella in the trochlear groove. She had no tenderness to palpation over her pes anserine, prepatellar, biceps femoris, or semimembranosus bursae.

An MRI of the patient's left knee revealed a tear of the posterior horn root attachment of the medial meniscus (Figure 1). The medial meniscus body itself was devoid of any tear other than its posterior horn root attachment site. There was no evidence of lateral meniscal injury, and the cruciate ligaments were intact.

Under arthroscopic examination, it was noted that the root attachment of the posterior horn of the medial meniscus had avulsed off its tibial attachment along with a bone fragment (Figure 2), and the entire posterior horn of the medial meniscus was unstable. The normal meniscal root attachment site was then identified on the tibia. At that point, the authors determined that the tear was repairable, with a good chance of reducing the posterior horn root attachment to its normal anatomic position.

A medial parapatellar arthroscopy portal was used as the working portal. We trephinated the posterior joint capsule around the meniscal attachment and synovium, decorticated the far lateral aspect of the bony avulsion with a shaver, and employed a rasp to stimulate healing of the perisynovial tissue. An anterior cruciate ligament (ACL) guide was then used to place a transtibial guide pin, which coursed from the anteromedial tibial cortex to the attachment site of the posterior horn root attachment on the posteromedial

[†]Address correspondence to Robert F. LaPrade, MD, PhD, Department of Orthopaedic Surgery, University of Minnesota, 2450 Riverside Ave, R200, Minneapolis, MN 55454 (e-mail: lapra001@umn.edu).

No potential conflict of interest declared.

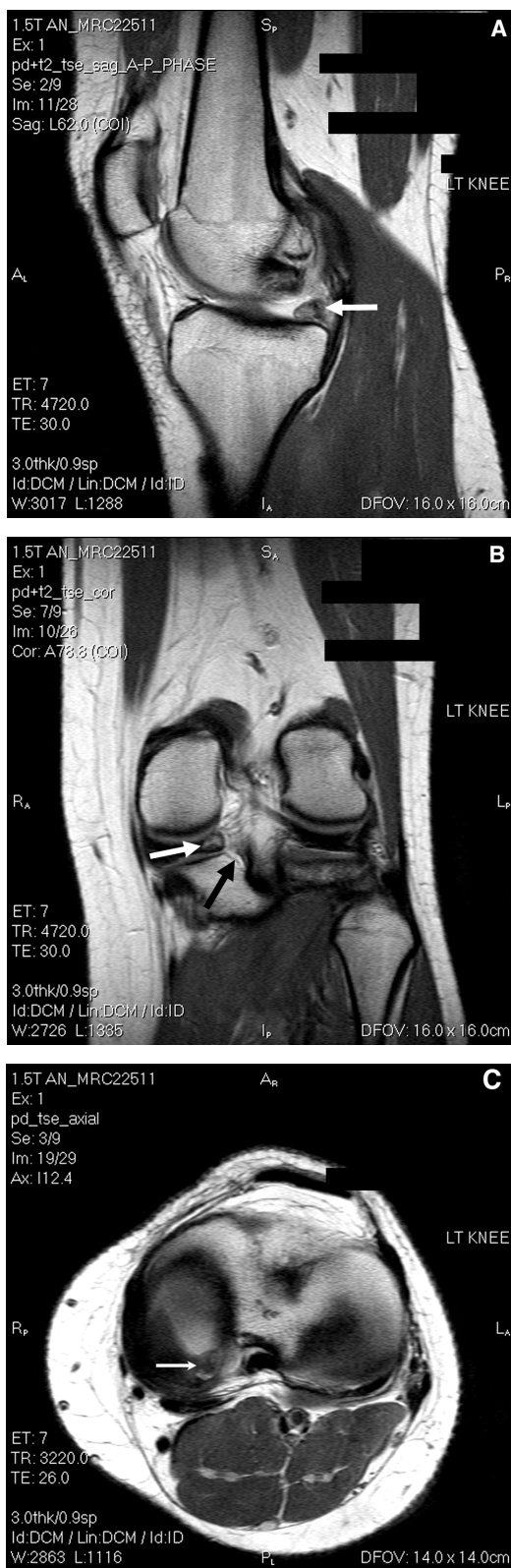


Figure 1. Preoperative MRI scans demonstrating the posterior horn root avulsion tear of the medial meniscus (left knee). A, sagittal (arrow indicates avulsed bony fragment); B, coronal (white arrow indicates avulsed bony fragment, black arrow indicates avulsion site); C, axial (arrow indicates avulsed bony fragment).

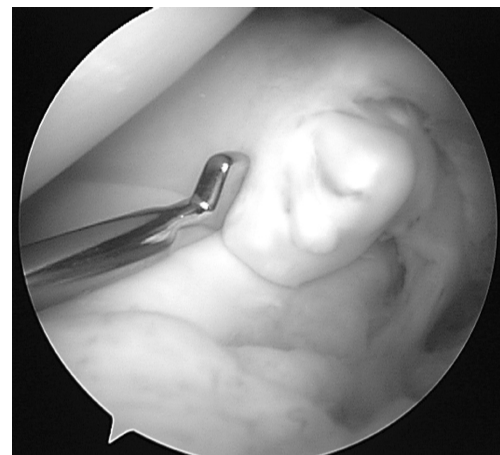


Figure 2. Arthroscopic photograph (posteromedial view-left knee) demonstrating the posterior horn root tear with its bony avulsion (meniscal ossicle to right of probe).

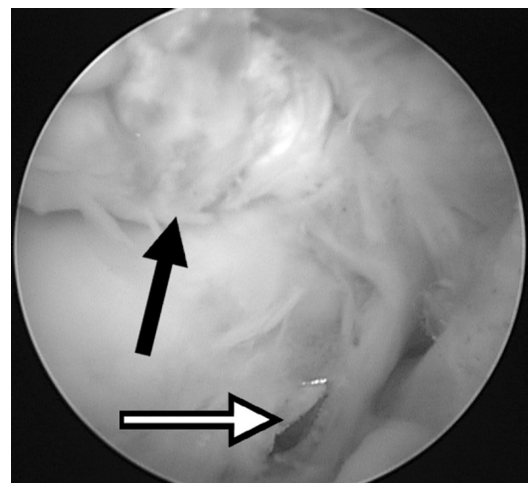


Figure 3. Arthroscopic photo showing decorticated meniscal root avulsion (black arrow) and tip of transtibial guide pin (white arrow).

aspect of the medial tibial plateau (Figure 3). A small 1-cm incision was then made vertically over the guide pin. Once the guide pin was confirmed to be in the proper position, we then proceeded to ream over it with a 5-mm reamer and to chamfer around the exit site on the posteromedial tibia with a rasp and shaver (Figure 4). An arthroscopic backbiter punch was also used to remove any soft tissue from the reamed tunnel entrance that could interfere with reducing the root avulsion fracture. We then used a Caspari suture punch (Arthrotek, Warsaw, Ind) to place two 2-0 Prolene (Johnson & Johnson, Somerville, NJ) sutures into the posterior horn root attachment on each side of the meniscal ossicle (Figure 5). Graspers were then used to pass the sutures through the tip of an islet pin inserted retrograde up the tibial tunnel. The sutures were subsequently pulled through the tunnel, which allowed the posterior horn meniscal root attachment to be reduced into the prepared 5-mm socket on the tibia (Figure 6). The posterior horn root of the patient's medial meniscus reduced to near anatomic position, and the entire posterior horn of the medial meniscus was now stable to palpation with a probe.

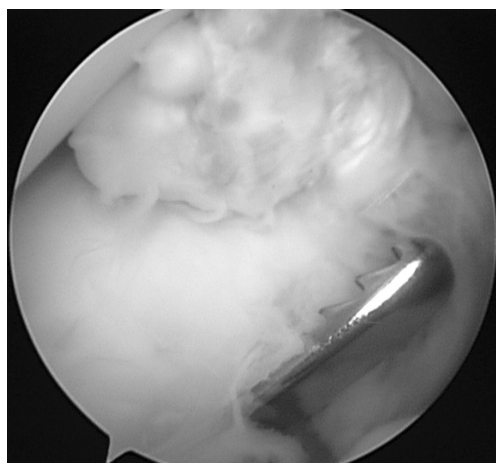


Figure 4. Arthroscopic photo demonstrating a rasp chamfering the posteromedial tibial tunnel entrance site.

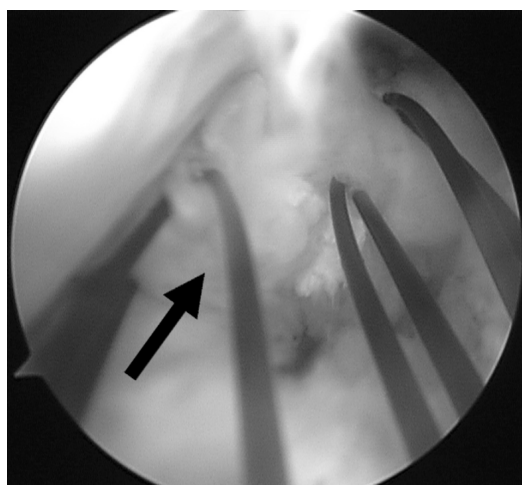


Figure 5. Prolene sutures surrounding base of decorticated meniscal root avulsion fracture (arrow).

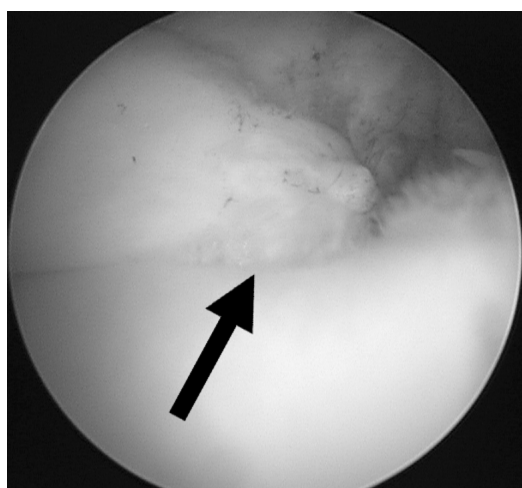


Figure 6. Arthroscopic photograph demonstrating the reduced posterior horn root of the medial meniscus using sutures (posteromedial view, left knee; arrow pointing to reduced root avulsion).

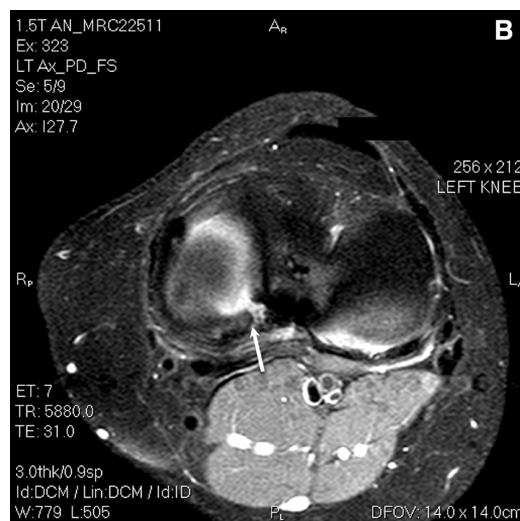
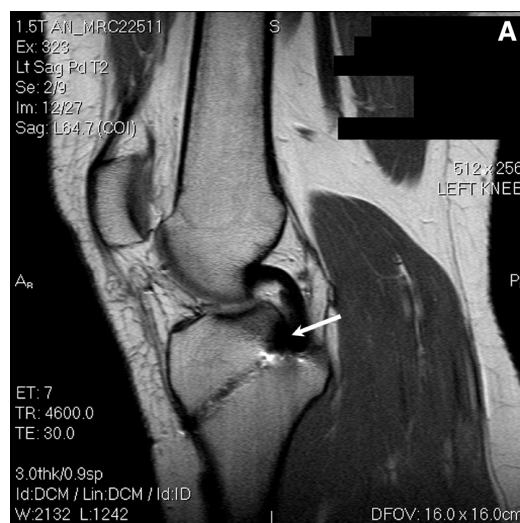

Figure 7. Follow-up left knee MRI demonstrating the surgical repair of the posterior horn root of the medial meniscus (arrow) 3 years postoperatively. A, sagittal; B, axial.

The sutures were individually tied over a button on the anteromedial tibial cortex. Both sutures were then tied back to themselves to provide further backup fixation. Further arthroscopic visualization of the posterior horn root attachment demonstrated that the avulsion fracture was well reduced, and her left knee could be flexed to about 70° before significant tension on the meniscal root repair was observed.

After surgery, the patient's knee was kept in full extension for 2 weeks, and she was instructed to perform quadriceps sets 5 to 6 times daily, as well as leg raises several times daily in the brace only. After the first 2 weeks, she was allowed passive motion out of the immobilizer as tolerated 4 times daily. The patient was kept nonweightbearing with the use of crutches for 6 weeks. She was then allowed to wean off her crutches once she could ambulate without a limp. At 3.5 months postoperatively, she was allowed to slowly progress with endurance activities before beginning cutting and sprinting activities. A follow-up MRI demonstrated that the posterior horn root attachment remains reduced in its normal anatomic position (Figure 7).



Figure 8. Patient performing a single-legged squat on her surgical left knee 3 years postoperatively.

At 3 years' postoperative follow-up, the patient was a sophomore in college and reported that she was able to participate in intramural basketball. She had a Tegner activity score of 7, a Cincinnati score of 92, an International Knee Documentation Committee (IKDC) subjective score of 88.5, and a Lysholm score of 80. On examination, she had no pain to deep squatting or to palpation along the medial joint line and was able to balance in a single deep leg squat (Figure 8). She had full range of motion compared with her contralateral side, from -3° to 135° . With no limitation or instability, she was able to perform a single-legged hop to 96% of her contralateral side and a crossover triple hop to 98% of her uninjured side. Overall, the patient had normal knee function and was satisfied with her recovery.

DISCUSSION

Previous authors have extensively described ossicles of the posterior horn of the medial meniscus and closely debated their origin.^{1,3,5,6,9,10,12-16} Regardless of the association with a traumatic injury, the initial treatment of these meniscal ossicles has been primarily conservative.¹⁰ Unfortunately, many of the conservatively treated patients had persistent symptoms and eventually required meniscectomy.¹⁰ To our knowledge, there is only 1 case report in the literature for the surgical reattachment of a bony avulsion of the posterior medial meniscal root after a traumatic injury.¹²

The root attachment of the posterior horn of the medial meniscus on the posterior tibia is essential in preventing extrusion of the medial meniscus and preserving normal medial meniscal position and function.⁶ We believe surgical reattachment and avoidance of meniscectomy should be the preferred treatment option for avulsion fractures of the posterior horn root of the medial meniscus. Several articles have reported on the rapid degeneration of the articular cartilage of the knee after a total meniscectomy.^{2,4,7,11} In this patient, the primary treatment principle was to relieve pain symptoms and avoid, in effect, a functionally total meniscectomy. Surgical reattachment of her posterior horn root avulsion fracture resulted in essentially normal left knee function at 3 years' follow-up.

REFERENCES

1. Berg E. The meniscal ossicle: the consequence of a meniscal avulsion. *Arthroscopy*. 1991;7:241-243.
2. Bolano LE, Grana WA. Isolated arthroscopic partial meniscectomy: functional radiographic evaluation at 5 years. *Am J Sports Med*. 1993;21:432-437.
3. Conforty B, Lotem M. Ossicles in human menisci: report of 2 cases. *Clin Orthop*. 1979;144:272-275.
4. Fairbank TJ. Knee joint changes after meniscectomy. *J Bone Joint Surg Br*. 1948;30:664-670.
5. Glass RS, Barnes WB, Kells Du, Thomas S, Campbell C. Ossicles of knee menisci. Reports of 7 cases. *Clin Orthop*. 1975;111:163-171.
6. Jones AO, Houang MTW, Low RS, Wood DG. Medial meniscus posterior root attachment injury and degeneration: MRI findings. *Austral Radiol*. 2006;50(4):306-313.
7. Jorgensen U, Sonne-Holm S, Lauridsen F, Rosenklint A. Long-term follow-up of meniscectomy in athletes: a prospective longitudinal study. *J Bone Joint Surg Br*. 1987;69:80-83.
8. Pagnani MJ, Cooper DE, Warren RF. Extrusion of the medial meniscus. *Arthroscopy*. 1991;7(3):297-300.
9. Pauly T, Van Ende R. Avulsion fracture. Special type of meniscal damage. *Arch Orthop Trauma Surg*. 1989;108(5):325-326.
10. Prabhudesai V, Richards P. Radiological appearance as a meniscal ossicle develops: a case report and review of the literature. *Injury*. 2003;34:378-382.
11. Rangger C, Klestil T, Gloetzer W, Kemmler G, Benedetto KP. Osteoarthritis after arthroscopic partial meniscectomy. *Am J Sports Med*. 1995;23:240-244.
12. Raustol OA, Poelstra KA, Chhabra A, Diduch DR. The meniscal ossicle revisited: etiology and an arthroscopic technique for treatment. *Arthroscopy*. 2006;22(6):687.e1-3.
13. Richmond JC, Sarno RC. Arthroscopic treatment of medial meniscal avulsion fractures. *Arthroscopy*. 1988;4(2):117-120.
14. Rosen IE. Unusual intrameniscal lunulae. Three case reports. *J Bone Joint Surg Am*. 1958;40:925-928.
15. Symeonides PP, Ioannides G. Ossicles of knee menisci. Report of 3 cases. *J Bone Joint Surg Am*. 1972;54:1288-1292.
16. Weaver JB. Calcification and ossification of the menisci. *J Bone Joint Surg*. 1942;24:873-882.