

# Acute Knee Injuries

## On-the-Field and Sideline Evaluation

Robert F LaPrade, MD

Fred Wentorf, MS

Photo: © 1999, Shelby Thorne/David Madison

### Ira brief

An athlete who has an acute knee injury should be assessed rapidly on the field and then more thoroughly on the sideline or in the training room. **On-the-field** assessment includes questions about the mechanism of injury and any similar previous injuries, a visual check for knee deformities and skin injuries, a neurovascular exam, and, ideally, tests for flexion and hyperextension. On the sideline or in the training room, standard physical tests are likely to reveal any significant injuries. These include the patellar apprehension, Lachman, posterior sag, quadriceps active, posterior drawer, posterolateral drawer, valgus and varus stress, pivot-shift, and dial tests.

**A**n athlete who has an acutely injured knee on the playing field, court, or once requires a thorough evaluation. Ideally, the knee should be assessed on the field within the first few minutes of injury, since guarding can set in quickly and interfere with a comprehensive examination. However, the athlete's pain may preclude certain diagnostic tests, and some tests may be more appropriate for a sideline or training-room exam.



In any case, a rapid on-the-field assessment followed by a more comprehensive evaluation on the sideline or in the training room can provide essential information. Using the basic principles of a history and physical exam that are outlined below will help physicians determine the type and severity of the injury and protect the short- and long-term health of athletes.

### History

The on-the-field assessment of an acute knee injury should be as brief but as thorough as possible and should include a history and initial physical exam. The goal is to rule out a fracture, dislocation, or neurovascular injury (table 1). Once these injuries have been assessed and, when necessary, treated, the athlete can be transferred to the sideline or training room for a more comprehensive evaluation.

**Mechanism.** One of the first steps is to determine whether the injury involved contact. If it is

*continued*



**For CME credit, see page 95**

Dr LaPrade is an assistant professor and Mr Wentorf is a research fellow in the Department of Orthopaedic Surgery at the University of Minnesota in Minneapolis. Dr LaPrade is also a team physician for ice hockey and baseball at the University of Minnesota and a member of the American Orthopaedic Society for Sports Medicine.

**Table 1. On-the-Field Assessment of Acute Knee Injuries: Condition and Signs\***

Condition	Signs
Fracture	immediate hemarthrosis, joint deformity, periarticular lacerations
Knee dislocation	Abnormal pulses, joint deformity, neurologic deficits
Patellar dislocation	Joint deformity, pain

\* Signs vary; the complete clinical picture must be considered.

a noncontact injury, knowing the position of the knee and lower extremity before the injury is helpful. A description of the athlete's injury-related sensations, such as tearing or an audible pop, can also facilitate the diagnosis. For example, a pop typically indicates an anterior cruciate ligament (ACL) tear, while a tearing sensation often accompanies a medial collateral ligament (MCL) tear.

If the injury involved contact, determining where the blow occurred on or around the knee is important. In general, injured ligamentous

structures are on the side opposite the blow. Blows to the lateral aspect of the knee, which are the most common, force the medial joint to open and stress the medial ligamentous structures; thus, most MCL injuries result from contact that causes valgus stress. Valgus stress can also lead to patellar dislocation or subluxation, so athletes who have received a lateral blow should be asked about sensations of patellar sliding or subluxation.

A blow to the medial or anteromedial aspect of the knee can cause a posterolateral complex injury, which can be quite serious, along with injury of the common peroneal nerve.<sup>1</sup> An anterior blow to a flexed knee, which can occur when an athlete falls on a hard surface with the knee flexed, can result in either a patellar injury (fracture or chondral fracture) or a posterior cruciate ligament (PCL) tear. A blow to an extended knee, which can cause hyperextension, may result in a range of defects, from an injury to the anterior fat pad to injuries involving both cruciate ligaments.

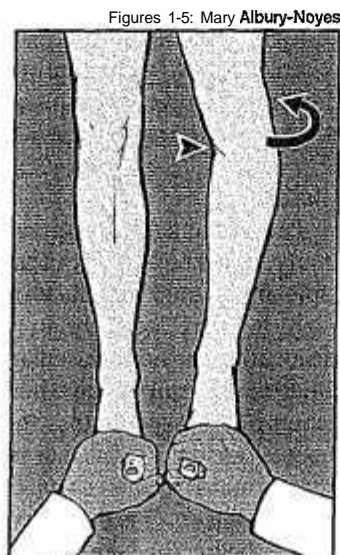
If an athlete cannot describe the mechanism of injury or is unclear about how the injury occurred, a teammate or another observer may be able to provide helpful information.

**Previous injury.** Besides determining the mechanism of current injury, asking about previous similar injuries and symptoms is also important. It is not uncommon for a knee injury to be an acute-on-chronic injury, ie, an exacerbation of a preexisting chronic injury. We have often seen athletes who had what was suspected to be an acute ACL tear; but subsequent evaluation revealed evidence of a chronic tear. In retrospect, most of these athletes will recall a previous injury that they may not have described in the acute situation.

### Initial Physical Examination

The initial evaluation of an injured knee includes an examination for loss of skin integrity and knee deformities that could be evidence of fractures or patellar or tibiofemoral dislocations. If the patella is dislocated, it can usually be reduced soon after injury by using a medial reduction maneuver with the knee in extension. An

**Figure 1.** For the external rotation recurvation test, the patient is supine with the quadriceps muscles relaxed. Grasping the toes, raise the injured limb. A hyperextended knee, a mildly rotated tibia (arrow), and a 'bow-legged' appearance of the medial aspect of the knee (arrowhead) indicate a posterolateral knee injury with an injury to one or both cruciate ligaments. In the presence of these signs, the uninjured limb should be checked for comparison.



immediate effusion usually indicates a hemarthrosis due to a significant intra-articular trauma. Abrasions or lacerations could be caused by extra-articular mechanisms or an intra-articular or periarticular fracture.

Next, an on-the-field neurovascular exam should be done. The extent of this exam depends on the nature of the injury. A quick check of gross sensation is appropriate in all cases. If a dislocation or posterolateral corner injury is suspected, the exam should include the common peroneal nerve distribution. Since most athletes on the field will be wearing shoes, this evaluation should be limited to assessing ankle dorsiflexion strength. If a knee dislocation is suspected, the pedal and posterior tibial pulses should also be checked before the athlete is moved to the sideline.

Evaluating the injured knee's range of motion is appropriate. An effective test for assessing hyperextension is the external rotation recurvation test (figure 1).<sup>17</sup> If there is hyperextension, the contralateral knee should be examined for symmetry; asymmetry indicates a significant multi-ligament injury on the affected side.

Ideally, the flexion of the injured knee should also be evaluated on the field, because pain, swelling and spasm make flexion very difficult to assess after a few hours. However, flexion should be checked gently and only to the degree permitted by the athlete's comfort. Full flexion may be limited by pain or a mechanical block, which could be caused by a meniscal tear; including a bucket-handle tear; or by a chondral or osteochondral fracture or some other lesion.

At this point, the athlete should usually be moved from the field for further examination. Some of the following tests could be done on the field, as indicated below, but performing them in a more controlled setting is preferable.

### Patellofemoral Joint

Although the patella may be evaluated on the field for subluxation or dislocation, as mentioned above, a more thorough evaluation can be done on the sideline. It should begin with palpation of the patella and tibial tubercle and surrounding structures. Pain at the inferior pole of

**Table 2. Sideline Examination for Acute Knee Injuries: Major Structures and Useful Tests**

Structure	Physical Test
Anterior cruciate ligament	Lachman, pivot-shift
Posterior cruciate ligament	Posterior drawer, posterior sag sign, quadriceps active
Fibular collateral ligament	Varus stress
Medial collateral ligament	Valgus stress
Patella	Patellar apprehension (for instability)
Posterolateral corner structures	Dial, external rotation recurvatum, varus stress, posterolateral drawer

the patella with a palpable step-off could indicate a patellar tendon tear. Pain along the medial patellofemoral ligament and retinacular structures could indicate a patellar dislocation.

Patellar subluxation or dislocation can be assessed by performing the patellar apprehension test.<sup>18</sup> With the patient seated or supine and the knee flexed 45°, the patella is pushed laterally. Apparent increased laxity and patient apprehension indicate the possibility of patellar subluxation or dislocation. If there is no increase in pain but some increase in laxity, the laxity of the other knee should be checked to determine if this is normal laxity for the patient.

Other injuries to consider are quadriceps tendon tears, tibial tubercle avulsion fractures in skeletally immature patients, and retropatellar fat-pad contusions. The sideline evaluation should include palpation of the sites of these structures.

### Tibiofemoral Joint

A number of physical tests are useful in assessing the tibiofemoral joint. Before doing these tests, however, it is helpful to ask the injured athlete to point to the area of the knee that is most

*continued*

Figure 2. The **Lachman** test is used to evaluate the integrity of the ACL. Flex the patient's knee **20°** to 30°, grasp the proximal tibia with one hand and the femur with the other, and, keeping the knee in neutral alignment, apply a gentle **anterior** force to the tibia. A translation of **more than 4 mm** and no **firm end point** indicates a **torn ACL**.

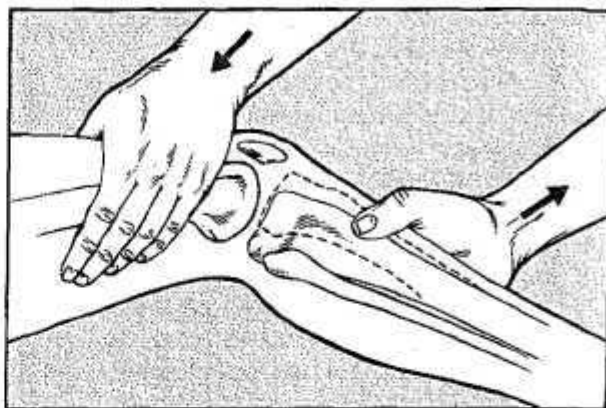


Figure 3. The posterior sag sign indicates a deficiency of the PCL. When the knee is flexed 90°, the joint will exhibit a posterior tibial sag (a). The quadriceps active test can confirm **PCL deficiency**. When the patient contracts the quadriceps muscles (arrow), the tibia will move from a posterior sag to a more normal position (b).

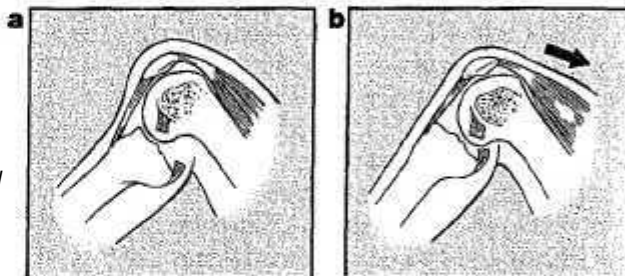
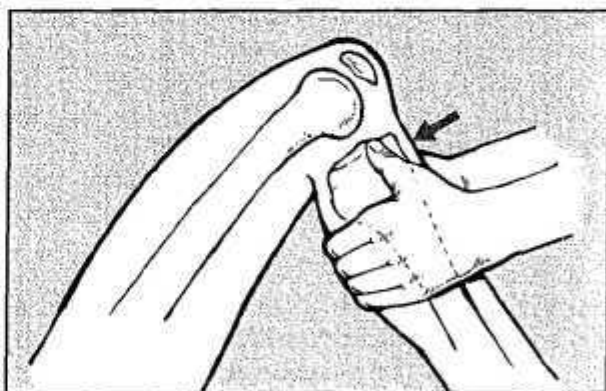

Figure 4. The **posterior** drawer test for **PCL** injury is done with the patient **supine**, the knee **flexed 90°**, and the quadriceps and hamstring muscles completely relaxed. Hold the tibia in neutral position by sitting on the patient's foot. Gently push the proximal tibia posteriorly to assess **PCL** integrity; excursion **and** a soft end point, when compared with the opposite side, suggest an injury.

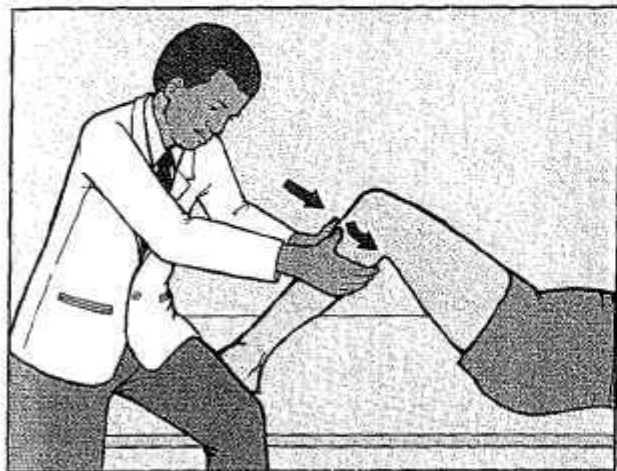


painful, thereby identifying the ligament complex (table 2) that most likely has been injured. Assessing the stability of this complex last will help to minimize guarding that could interfere with the evaluation of other injured structures.

If the tibiofemoral joint is evaluated on the field, the goal is to detect abnormalities that would disqualify an athlete from immediate return to play.

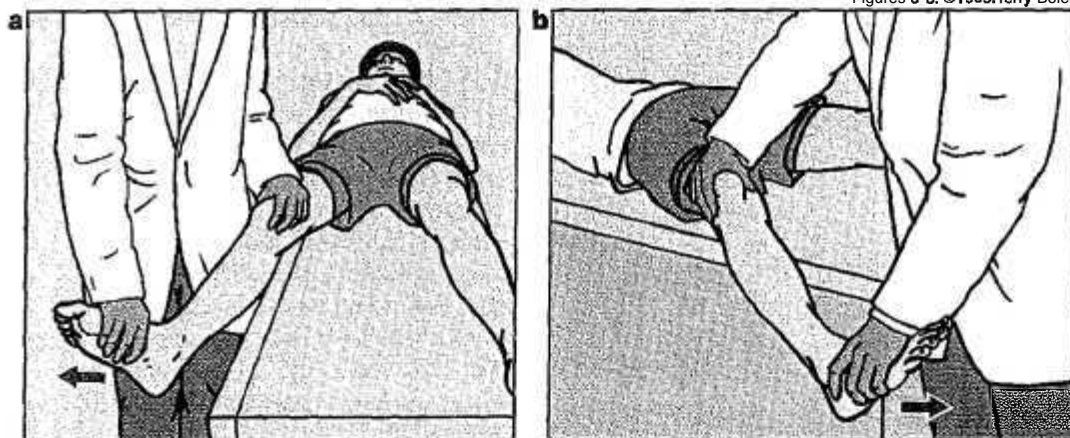
**Anterior translation.** The *Lachman* test (fig-

ure 2) is the most effective test to determine the integrity of the **anterior** cruciate ligament (ACL).<sup>4</sup> A normal knee will have less than 2 to 4 mm of **anterior** translation and a solid end point. A knee with an acute ACL injury will have increased **anterior** translation **and** a soft end point. In this test the knee must be held in neutral alignment, because if the patient's tibia is allowed to rotate, any laxity detected may be the result of other injuries, such as a posterolateral



**Figure 5.** The posterolateral drawer test is a variant of the posterior drawer test. With the knee and hip flexed  $80^{\circ}$  to  $90^{\circ}$ , rotate the patient's foot externally  $15^{\circ}$  to  $20^{\circ}$  and immobilize the foot under your thigh. Apply a posterior and external rotation force to the proximal tibia (arrows). Increased posterolateral rotation in comparison with the uninjured knee indicates a posterolateral corner injury.

Figures 6-8: ©1999, Terry Boles



**Figure 6.** The valgus and varus stress tests are performed while the patient is supine with the knee flexed  $30^{\circ}$ . In the valgus test (a), place your hip against the lateral aspect of the patient's thigh and put the fingers of one hand over the medial joint line of the injured knee. Grasping the patient's foot or ankle, apply a valgus stress through the foot or ankle and assess intra-articular crepitation and the degree of medial compartment opening. The varus test (b) is similar to the valgus test but involves reversing your hand positions and applying a varus stress while assessing lateral joint-line opening.

injury, rather than of an ACL injury.

**Posterior translation.** Tests used to evaluate the PCL are usually done with the knee flexed  $90^{\circ}$ . In this position, the PCL is the main structure preventing posterior translation of the tibia on the femur.<sup>5</sup> When the PCL has been torn, posterior translation is increased.

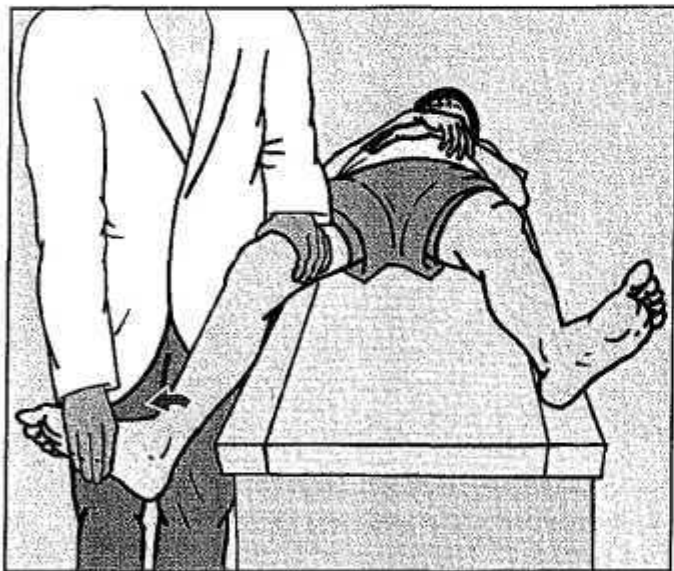
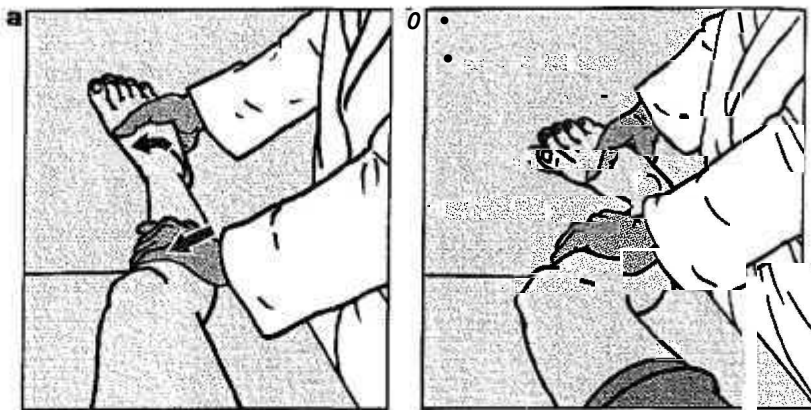
The posterior sag sign (figure 3a) is an excellent clinical test of the integrity of the PCL. If the ligament is injured, a step-off deformity of the

proximal tibia will be apparent. This test can be followed by the quadriceps active test (figure 3b),<sup>6</sup> which may be the most reliable test in an acute knee injury. If the PCL is partially or completely torn, contracting the quadriceps will pull the posteriorly translated proximal tibia forward into a more normal position.

The posterior drawer test (figure 4)<sup>5</sup> is done with the examiner sitting on the patient's foot to hold it in a neutral position. The amount of pos-

*continued*

**Figure 7.** For the pivot-shift test, apply internal rotation and valgus forces to the nearly fully extended knee (a). If the anterior ACL is torn, the tibia will sublux slightly antero-laterally. As the knee is then flexed to about 40° (b), the iliotibial band changes from a knee extensor to a flexor and reduces the subluxed tibia, sometimes with an audible clunk—a positive test for an ACL tear. A positive test should not be repeated because of risk to the meniscus.



**Figure 8.** The dial test is done with the supine patient's knee flexed 30° and feet extending over the side of a bench or table. Externally rotate the foot while stabilizing the thigh, and observe the amount of rotation of the tibial tubercle. Increased external rotation on the injured side indicates a posterolateral corner injury. This test can be repeated with the knee flexed 90° and the hip in neutral. If the injured knee rotates less at 90° than at 30°, an isolated posterolateral injury is likely; if the knee rotates more at 90°, a concurrent PCL injury is likely.

terior translation is assessed by gently rocking the knee back and forth. The test must be done with the tibia in neutral rotation, and the patient's quadriceps and hamstrings must be completely relaxed. If the foot is not held in neutral rotation, and if the PCL is intact but a posterolateral injury is present, a combination of external rotation and posterior translation can give the false impression of a PCL injury.

The posterolateral drawer test (figure 5)<sup>12</sup> is used to assess the integrity of the posterolateral corner structures of the knee. Posterolateral rotation of the injured knee should be compared with that of the normal knee.

**Varus and valgus laxity.** The collateral ligaments can be assessed by applying varus and valgus stresses to the knee in 30° of flexion (figure 6), the position in which the collateral ligaments are the main stabilizers of the knee. In both maneuvers, the patient's leg is placed over the side of a bench or examining table, and stress is applied to the knee. It is important to apply the valgus or varus force through the foot or ankle rather than directly to the tibial shaft, because otherwise the extent of the ligamentous injury may not be completely appreciated.

The examiner places his or her fingers directly over the joint line to assess intra-articular crepitation and joint-line opening.<sup>37</sup> Intra-articular crepitation indicates either a meniscal tear or a chondral and/or osteochondral injury. A clunk may indicate a very unstable, large periph-



eral tear of the meniscus where it has separated from the capsule. In addition, localized areas of arthritis may be painful with these maneuvers.

The severity of collateral ligament injury is generally indicated by the amount of joint-line opening with valgus and varus stress<sup>8</sup>:

- Less than 5 mm, grade 1 (minor sprain);
- 6 to 10 mm, grade 2 (partial tear); and
- More than 1 cm and no solid end point, grade 3 (complete tear)

However, the amount of joint-line opening in a varus stress test varies among patients, so it is essential to compare the injured knee with the uninjured knee.

In skeletally immature patients, any increase in medial or lateral joint-line opening may indicate a growth plate (physeal) fracture.

**Rotational abnormalities.** Assessing for rotational instabilities of the knee can help the physician diagnose ligament injuries. Two tests are useful and should usually be done on the side-line shortly after the injury, before significant pain and spasm begin.

The *pivot-shift test* (figure 7) is used to gauge the integrity of the ACL.<sup>9</sup> This maneuver requires a completely relaxed hamstring. A positive test should not be repeated since repetition could worsen any meniscal tear.

The *dial test* (figure 8) assesses posterolateral rotation of the tibia on the femur and injuries to the posterolateral knee. The test is often de-

scribed as being done with the patient prone, but we have found it more useful to have the patient supine. As the patient's feet are externally rotated, the amount of rotation of the two limbs is compared by observing the tibial tubercles.<sup>10</sup> The maneuver will suggest whether the patient has an isolated posterolateral injury or a posterolateral injury with a torn PCL.

### Guiding Return to Play

The physical tests described here obviously do not include all tests for evaluating an acutely injured knee. But these tests, if done as soon after injury as possible, are likely to reveal any major injury and provide valuable information for making return-to-play decisions. The most painful tissues are likely sites of injury and should be tested last to minimize spasm and guarding that could interfere with a complete assessment. Thoroughness is essential since concurrent injuries can affect an athlete's prognosis.

An athlete should resume play only after he or she has a full range of motion, as demonstrated in a comprehensive exam, and has passed functional tests specific to his or her sport. **PSM**

Address correspondence to Robert E LaPrade, MD, University of Minnesota, Dept of Orthopaedic Surgery, 420 Delaware St SE, Box 492, Minneapolis, MN 55455. E-mail may be sent to the author via the following Web site: [www.sportsdoc.umn.edu](http://www.sportsdoc.umn.edu).

### References

1. LaPrade RF, Terry GC: Injuries to the posterolateral aspect of the knee: association of anatomic injury patterns with clinical instability. *Am J Sports Med* 1997;25(4):433-438
2. Hughston JC, Norwood LA: The posterolateral drawer test and external rotation recurvatum test for posterolateral rotatory instability of the knee. *Clin Orthop* 1980;147(Mar-Apr):82-87
3. Jacobson KE, Flandry FC: Diagnosis of anterior knee pain. *Clin Sports Med* 1989;8(2):179-196
4. Torg JS, Conrad W, Kalen V: Clinical diagnosis of anterior cruciate ligament instability in the athlete. *Am J Sports Med* 1976;4(2):84-91
5. Grood ES, Stowers SF, Noyes FR: Limits of movement in the human knee: effect of sectioning the posterior cruciate ligament and posterolateral structures. *J Bone Joint Surg (Am)* 1988;70(1):88-97
6. Daniel DM, Stone ML, Barnett P, et al: Use of the quadriceps active test to diagnose posterior cruciate ligament disruption and measure posterior laxity of the knee. *J Bone Joint Surg (Am)* 1988;70(3):386-391
7. Hughston JC, Andrews JR, Cross MJ, et al: Classification of knee ligament instabilities: part I: the medial compartment and cruciate ligaments. *J Bone Joint Surg (Am)* 1976;58(2):159-172
8. American Medical Association: Standard nomenclature of athletic injuries. Chicago, American Medical Association, 1966
9. Bach BR, Warren RF, Wickiewicz TJ: The pivot shift phenomenon: results and description of a modified clinical test for anterior cruciate ligament insufficiency. *Am J Sports Med* 1988;16(6):571-576
10. Veltri DM, Warren BF: Posterolateral instability of the knee. *J Bone Joint Surg (Am)* 1994;76(3):460-472