

Sartorial branch of the saphenous nerve in relation to a medial knee ligament repair or reconstruction

Coen A. Wijdicks · Benjamin D. Westerhaus ·
Emily J. Brand · Steinar Johansen ·
Lars Engebretsen · Robert F. LaPrade

Received: 22 July 2009 / Accepted: 4 September 2009
© Springer-Verlag 2009

Abstract Surgical approaches to repair or reconstruct the medial knee structures note caution to avoid the sartorial branch of saphenous nerve. However, the approximate area of potential iatrogenic nerve injury has not been previously described in relation to landmarks for a medial knee reconstruction. The purpose of this study was to define the course of the sartorial branch of the saphenous nerve in relation to the superficial medial collateral ligament. A total of ten non-paired, fresh-frozen cadaveric knees, with no evidence of prior injury or disease were utilized. Dissection to identify the medial knee structures was performed. The sartorial branch of the saphenous nerve was identified in all specimens. The perpendicular distance from the anterior border of the superficial medial collateral ligament 2 cm distal from the joint line to the sartorial branch of the saphenous nerve was 4.8 ± 0.9 cm. The distance from the anterior border of the superficial medial collateral ligament to the sartorial branch of the saphenous nerve decreased as the distance was increased distally with a mean distance of 4 cm (4.1 ± 0.8 cm) distal from the joint line and 6 cm (3.8 ± 0.8 cm) distal from the joint line. We have characterized the surgically relevant landmark anatomy of the sartorial branch of the saphenous nerve in regards to performing a repair or reconstruction of

the medial knee structures. Familiarity with these anatomic landmarks and associated distances from the sartorial branch of the saphenous nerve, we can assess the potential area of vulnerability to this nerve branch intraoperatively.

Keywords Superficial medial collateral ligament · Saphenous nerve · Sartorial branch · Medial knee reconstruction

Introduction

Injuries to the medial knee structures comprise the most commonly injured ligaments of the knee, and are frequently found in patients with valgus instability about the knee joint [12, 15, 22, 26]. Surgical treatment of medial knee injuries has recently gained interest in the literature; of which, the most commonly repaired or reconstructed structure is the superficial medial collateral ligament [5, 10, 11, 20, 23, 35]. The superficial medial collateral ligament consists of one femoral and two tibial attachments, which have been separately defined as the proximal and distal divisions [21]. Anatomically, the femoral superficial medial collateral ligament attachment is located approximately 6.0 mm posterior to the medial epicondyle, whereas the distal tibial attachment of the superficial medial collateral ligament is located approximately 6.0 cm distal to the medial joint line [21, 34].

Recent literatures [5, 10, 11, 20, 23, 35] describing a surgical approach to repair or to reconstruct the medial knee structures note caution to avoid the sartorial branch of saphenous nerve, which provides sensation to the medial part of the leg, knee, calf, and ankle. The position of the sartorial branch of the saphenous nerve has been previously described for knee arthroscopy in reference to the anterior

C. A. Wijdicks · B. D. Westerhaus · E. J. Brand ·
R. F. LaPrade (✉)
Orthopaedic Biomechanics Laboratory,
Department of Orthopaedic Surgery,
University of Minnesota, 2450 Riverside Avenue South,
R200, Minneapolis, MN 55454, USA
e-mail: lapra001@umn.edu

S. Johansen · L. Engebretsen
Orthopaedic Center, Ullevaal University Hospital and Faculty
of Medicine, University of Oslo, Oslo, Norway

border of the sartorius [7] and for its relationship to the tibial attachment of the pes anserine tendons and the distance from the medial femoral epicondyle [3]. However, the approximate area of potential iatrogenic nerve injury has not been previously described in relation to landmarks for a medial knee reconstruction.

The proximity of the saphenous nerve to the medial portion of the knee makes it vulnerable to potential iatrogenic injury. Surgical transection or injury to the saphenous nerve has been reported as a complication of arthroscopy [9], medial approach knee injection [18], hamstring tendon harvest [4], saphenous vein harvest [25], and fasciotomy [28]. One study reported an isolated injury rate of 23% to the sartorial branch after autogenous hamstring harvesting [29]. In agreement with other authors, the nerve damage was permanent in 80% of the clinical cases [4, 27, 29, 33].

Accurate knowledge of the location of the sartorial branch of the saphenous nerve is necessary to avoid iatrogenic nerve injury [29] while at the same time being able to fully repair or reconstruct the medial knee structures to their native anatomic state. The purpose of this study was to define the course of the sartorial branch of the saphenous nerve in relation to the superficial medial collateral ligament, and to provide a clinically relevant guide to evoke caution and consideration for this nerve during a medial knee repair or reconstruction.

Materials and methods

A total of ten non-paired, fresh-frozen cadaveric knees, with an average age of 61.7 years (range 43–81 years), with no evidence of prior injury or disease were utilized for this study. Knees were stored at -20°C and thawed overnight prior to dissection.

Dissection to identify the medial knee structures was performed. The incision was initiated proximally 2 cm anterior and proximal to the medial epicondyle and continued distally to the level of the pes anserine tibial attachment. The distal aspect of the incision split the distance between the anterior tibial crest and the posteromedial border of the tibia. The semitendinosus, gracilis, and sartorius muscles and tendons were identified and deeper dissection just distal to the semitendinosus was performed to enter the pes anserine bursa. The superficial medial collateral ligament was identified deep within the pes anserine bursa [21]. During dissection, we were careful to identify the course of the sartorial branch of the saphenous nerve in relation to landmarks. These landmark-based distance measurements were recorded in reference to the perpendicular distance from the adductor tubercle and medial epicondyle and 2, 4, and 6 cm distal to the medial joint line along the anterior border of the superficial medial

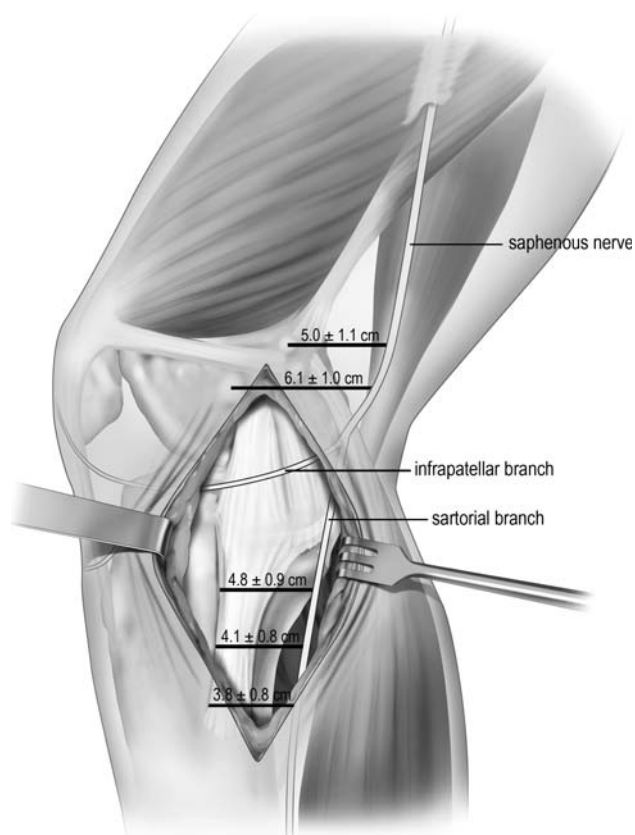


Fig. 1 Diagrammatic representation of the medial knee and the course of the saphenous nerve and associated sartorial and infrapatellar branches. Distance measurements (mean \pm SD) are noted in relation to the described landmarks. Please refer to Table 1 for additional information

collateral ligament (Figs. 1, 2). The knees were placed in 30° of knee flexion and one examiner measured all of the distances, while a second examiner verified the identified

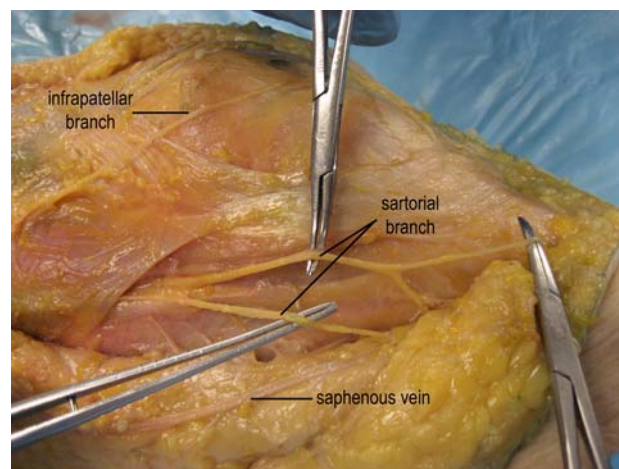


Fig. 2 Dissection demonstrating the course of the sartorial branch of the saphenous nerve (medial view, left knee)

Table 1 Quantitative relationships of sartorial branch of the saphenous nerve to medial knee landmarks

Relationship	Mean distance \pm SD (range)
Perpendicular distance to sartorial branch from anterior border of the sMCL at	
2 cm Distal from joint space	4.8 \pm 0.9 cm (3.0–7.0 cm)
4 cm Distal from joint space	4.1 \pm 0.8 cm (2.5–6.0 cm)
6 cm Distal from joint space	3.8 \pm 0.8 cm (2.5–5.5 cm)
Perpendicular distance to sartorial branch from adductor tubercle	5.0 \pm 1.1 cm (3.0–7.0 cm)
Perpendicular distance to sartorial branch from medial epicondyle	6.1 \pm 1.0 cm (4.5–8.0 cm)

structures in relation to the pertinent landmarks and the subsequent recorded measurements.

Results

The sartorial branch of the saphenous nerve was identified in all specimens (Fig. 1; Table 1). The branching of the nerve varied among specimens from the saphenous nerve to the sartorial and infrapatellar branches. Distances are reported in mean and SD. The perpendicular distance to the sartorial branch of the saphenous nerve from the adductor tubercle was 5.0 ± 1.1 cm. The perpendicular distance to the sartorial branch of the saphenous nerve from the medial epicondyle was 6.1 ± 1.0 cm. The perpendicular distance from the anterior border of the superficial medial collateral ligament 2 cm distal from the joint line to the sartorial branch of the saphenous nerve was 4.8 ± 0.9 cm. The distance from the anterior border of the superficial medial collateral ligament to the sartorial branch of the saphenous nerve decreased as the distance was increased distally with a mean distance of 4.1 ± 0.8 cm, 4 cm distal from the joint line and 3.8 ± 0.8 cm, 6 cm distal from the joint line.

Discussion

The surgical approach for medial knee repairs and reconstructions predominantly utilize an anteromedial incision [5, 6, 10, 11, 20, 23, 35]. The present study defined the locations of the sartorial branch of the saphenous nerve, and characterized safe zone for a medial knee reconstruction that does not compromise this important branch of the nerve. The most important finding of the present study was that the sartorial branch of the saphenous nerve courses slightly posterior to the medial knee structure, which is most commonly repaired or reconstructed and is in agreement with other authors [7]. Furthermore, the surgical incisions and dissections performed along both femoral attachments of the main medial knee structures and also anterior to the posteromedial aspect of the tibia should avoid its course.

The saphenous nerve is the major cutaneous branch of the femoral nerve, which originates from the second, third, and fourth lumbar rootlets as part of the lumbar plexus. Disruption of the saphenous nerve at the knee can result in a spectrum of neuropathy ranging from inconsequential sensory loss [1] to painful neuralgia; classically described as “burning, electrical shock-like” sensations [4]. The sectioned nerve can also develop into a painful neuroma, which has been described in cases where the axonal regrowth process is blocked, possibly by scar tissue, and these sprouts turn back toward the cell body and form a tangle of nerve endings. Ectopic nerve firings from these neuromas can give rise to painful sensations [2, 30].

The saphenous nerve travels with the femoral artery in the adductor (Hunter’s) canal until exiting the canal with the saphenous branch of the inferior genicular artery at the lower part of the adductor magnus muscle [14]. Upon its emergence from Hunter’s canal, the saphenous nerve divides into infrapatellar and sartorial terminal branches. The infrapatellar branch travels anteriorly and courses inferior to the patella to innervate the anteromedial aspect of the knee [8]. The sartorial branch has been reported to primarily have a vertical course, deep to the sartorius muscle along the medial side of the knee [3]. It becomes subcutaneous between the sartorius and gracilis muscles, and then continues inferiorly with the great saphenous vein to provide sensation to the medial part of the leg, knee, calf, ankle [3, 32], and extends as far as the first metatarsal [24].

One limitation of the present study was that we did not measure the course of the infrapatellar branch of the saphenous nerve. The infrapatellar branch of the saphenous nerve is the primary articular afferent branch of the saphenous nerve [19]. This branch splits from the saphenous nerve in a highly variable fashion [16, 30], and innervates the inferomedial capsule, patellar tendon, and overlying skin. The rate of iatrogenic infrapatellar nerve injury with open techniques has been studied for anterior cruciate ligament and meniscal surgery, and incidences have ranged from 21 to 69% [13, 17, 31, 33]. Due to the location of the superficial medial collateral ligament and associated landmarks in the present study, focus was set primarily on the sartorial branch of the saphenous nerve,

because the infrapatellar branch is most often transected during medial knee surgical approaches. In the present study, we also did not perform an interclass correlation between different examiners to determine repeatability. However, all our measurements were made by one examiner to minimize this variance, and further consultation from orthopedic surgeons and anatomists was commonly utilized to verify the measured structures and pertinent landmarks. The study also had a limited number of non-paired cadaveric specimens available, and despite our consistent numbers and low standard deviation, a more extensive anatomical study may provide insights into potential variances not previously described.

Conclusion

We have characterized the surgically relevant landmark anatomy of the sartorial branch of the saphenous nerve in regards to performing a repair or reconstruction of the medial knee structures. Familiarity with these anatomic landmarks and associated distances from the sartorial branch of the saphenous nerve, we can assess the potential area of vulnerability to this nerve branch intraoperatively. The clinical relevance of this study is to assist surgeons in minimizing the risk of injury to the nerve during the selection of the surgical approach, dissection strategy, and retractor placement.

Acknowledgments This research study was supported by a grant from the Research Council of Norway grant # 175047/D15 and Health East Norway grant # 10703604.

References

- Abram LJ, Froimson AI (1991) Saphenous nerve injury. An unusual arthroscopic complication. *Am J Sports Med* 19:668–669
- Anderson DJ, Fallat LM (1999) Complex regional pain syndrome of the lower extremity: a retrospective study of 33 patients. *J Foot Ankle Surg* 38:381–387
- Arthornthurasook A, Gaew-Im K (1990) The sartorial nerve: its relationship to the medial aspect of the knee. *Am J Sports Med* 18:41–42
- Bertram C, Porsch M, Hackenbroch MH, Terhaag D (2000) Saphenous neuralgia after arthroscopically assisted anterior cruciate ligament reconstruction with a semitendinosus and gracilis tendon graft. *Arthroscopy* 16:763–766
- Borden PS, Kantaras AT, Caborn DN (2002) Medial collateral ligament reconstruction with allograft using a double-bundle technique. *Arthroscopy* E18:E19
- Coobs BR, Wijdicks CW, Armitage BM, Spiridonov SI, West-erhaus BD, Johansen S, Engebretsen L, LaPrade RF (2009) An in vitro analysis of an anatomic medial knee reconstruction. *Am J Sports Med*. doi:10.1177/0363546509347996
- Dunaway DJ, Steensen RN, Wiand W, Dopirak RM (2005) The sartorial branch of the saphenous nerve: its anatomy at the joint line of the knee. *Arthroscopy* 21:547–551
- Ebraheim NA, Mekhail AO (1997) The infrapatellar branch of the saphenous nerve: an anatomic study. *J Orthop Trauma* 11:195–199
- Espejo-Baena A, Golano P, Meschian S, Garcia-Herrera JM, Serrano Jimenez JM (2007) Complications in medial meniscus suture: a cadaveric study. *Knee Surg Sports Traumatol Arthrosc* 15:811–816
- Fanelli GC, Harris JD (2006) Surgical treatment of acute medial collateral ligament and posteromedial corner injuries of the knee. *Sports Med Arthrosc* 14:78–83
- Feeley BT, Muller MS, Allen AA, Granchi CC, Pearle AD (2009) Biomechanical comparison of medial collateral ligament reconstructions using computer-assisted navigation. *Am J Sports Med* 37:1123–1130
- Fetto JF, Marshall JL (1978) Medial collateral ligament injuries of the knee: a rationale for treatment. *Clin Orthop Relat Res* 132:206–218
- Freeman BL III, Beaty JH, Haynes DB (1982) The pes anserinus transfer. A long-term follow-up. *J Bone Joint Surg Am* 64:202–207
- Gray H, Pick TP, Howden R (1977) Anatomy, descriptive and surgical. A rev American, from the 15th English edn. Bounty Books, New York
- Grood ES, Noyes FR, Butler DL, Suntay WJ (1981) Ligamentous and capsular restraints preventing straight medial and lateral laxity in intact human cadaver knees. *J Bone Joint Surg Am* 63:1257–1269
- House JH, Ahmed K (1977) Entrapment neuropathy of the infrapatellar branch of the saphenous nerve. *Am J Sports Med* 5:217–224
- Hunter LY, Louis DS, Ricciardi JR, O'Connor GA (1979) The saphenous nerve: its course and importance in medial arthrotomy. *Am J Sports Med* 7:227–230
- Iizuka M, Yao R, Wainapel S (2005) Saphenous nerve injury following medial knee joint injection: a case report. *Arch Phys Med Rehabil* 86:2062–2065
- Kennedy JC, Alexander IJ, Hayes KC (1982) Nerve supply of the human knee and its functional importance. *Am J Sports Med* 10:329–335
- Kim SJ, Lee DH, Kim TE, Choi NH (2008) Concomitant reconstruction of the medial collateral and posterior oblique ligaments for medial instability of the knee. *J Bone Joint Surg Br* 90:1323–1327
- LaPrade RF, Engebretsen AH, Ly TV, Johansen S, Wentorf FA, Engebretsen L (2007) The anatomy of the medial part of the knee. *J Bone Joint Surg Am* 89:2000–2010
- LaPrade RF (1999) The medial collateral ligament complex and the posterolateral aspect of the knee. In: Arendt EA (ed) *Orthopaedic knowledge update: sports medicine 2*. Amer Acad of Orthopaedic Surgeons, Rosemont, pp 327–340
- Lind M, Jakobsen BW, Lund B, Hansen MS, Abdallah O, Christiansen SE (2009) Anatomical reconstruction of the medial collateral ligament and posteromedial corner of the knee in patients with chronic medial collateral ligament instability. *Am J Sports Med* 37:1116–1122
- Moore KL, Dalley AF, Agur AMR (2006) Clinically oriented anatomy, 5th edn. Lippincott Williams & Wilkins, Philadelphia
- Mountney J, Wilkinson GA (1999) Saphenous neuralgia after coronary artery bypass grafting. *Eur J Cardiothorac Surg* 16:440–443
- Najibi S, Albright JP (2005) The use of knee braces, part 1: prophylactic knee braces in contact sports. *Am J Sports Med* 33:602–611
- Papastergiou SG, Voulgaropoulos H, Mikalef P, Ziogas E, Pappis G, Giannakopoulos I (2006) Injuries to the infrapatellar branch(es) of the saphenous nerve in anterior cruciate ligament

- reconstruction with four-strand hamstring tendon autograft: vertical versus horizontal incision for harvest. *Knee Surg Sports Traumatol Arthrosc* 14:789–793
28. Pyne D, Jawad AS, Padhiar N (2003) Saphenous nerve injury after fasciotomy for compartment syndrome. *Br J Sports Med* 37:541–542
 29. Sanders B, Rolf R, McClelland W, Xerogeanes J (2007) Prevalence of saphenous nerve injury after autogenous hamstring harvest: an anatomic and clinical study of sartorial branch injury. *Arthroscopy* 23:956–963
 30. Senegor M (1991) Iatrogenic saphenous neuralgia: successful therapy with neuroma resection. *Neurosurgery* 28:295–298
 31. Sgaglione NA, Warren RF, Wickiewicz TL, Gold DA, Panariello RA (1990) Primary repair with semitendinosus tendon augmentation of acute anterior cruciate ligament injuries. *Am J Sports Med* 18:64–73
 32. Slocum DB, Larson RL, James SL (1974) Late reconstruction of ligamentous injuries of the medial compartment of the knee. *Clin Orthop Relat Res* 100:23–55
 33. Spicer DD, Blagg SE, Unwin AJ, Allum RL (2000) Anterior knee symptoms after four-strand hamstring tendon anterior cruciate ligament reconstruction. *Knee Surg Sports Traumatol Arthrosc* 8:286–289
 34. Wijdicks CA, Griffith CJ, LaPrade RF, Johansen S, Sunderland A, Arendt EA, Engebretsen L (2009) Radiographic identification of the primary medial knee structures. *J Bone Joint Surg Am* 91:521–529
 35. Yoshiya S, Kuroda R, Mizuno K, Yamamoto T, Kurosaka M (2005) Medial collateral ligament reconstruction using autogenous hamstring tendons: technique and results in initial cases. *Am J Sports Med* 33:1380–1385