Trochlear Dysplasia and the Role of Trochleoplasty

Robert F. LaPrade, MD, PhD[a,b,*], Tyler R. Cram, MA, ATC, OTC[a], Evan W. James, BS[b], Matthew T. Rasmussen, BS[c]

KEYWORDS

• Patellar instability • Trochleoplasty • Trochlear dysplasia • Patellofemoral joint

KEY POINTS

- Patients with trochlear dysplasia frequently have recurrent patellar instability.
- Imaging is the most useful diagnostic technique for classifying trochlear morphology, assessing the severity of dysplasia, and assisting in preoperative planning.
- In many patients, a trochleoplasty permanently restores bony patellofemoral joint stability.
- A trochleoplasty is often performed alongside other patellar reconstruction procedures, including a medial patellofemoral ligament reconstruction or a tibial tubercle osteotomy.
- Patients with open physes or with advanced patellofemoral arthritis should not be considered candidates for a trochleoplasty.

INTRODUCTION

The incidence of primary patellar dislocation is estimated at 5.8 cases per 100,000 individuals.[1] In the at-risk population, which includes patients from 10 to 17 years of age, the incidence of patellar dislocation increases to 29 cases per 100,000 individuals. Recurrent dislocations reportedly occur in 17% of all cases following a primary dislocation event. After a second dislocation, the chance of additional dislocations increases to approximately 50%. For this reason, treatment is imperative for patients

Conflict of interest: The authors report no conflicts regarding board member/owner/officer/committee appointments, royalties, speaker's bureau/paid presentations, unpaid consultantships, research or institutional support from publishers, or stock or stock options. R.F. LaPrade is a paid consultant for Arthrex and receives research or institutional support from the Steadman Philippon Research Institute, which receives financial support from Smith & Nephew Endoscopy; Arthrex, Inc; Siemens Medical Solutions, USA; Sonoma Orthopedics, Inc; ConMed Linvatec; Össur Americas; Small Bone Innovations, Inc; Opedix; and Evidence Based Apparel.

[a] The Steadman Clinic, 181 West Meadow Drive, Suite 400, Vail, CO 81657, USA; [b] Center for Outcomes-based Orthopaedic Research, Steadman Philippon Research Institute, 181 West Meadow Drive, Suite 1000, Vail, CO 81657, USA; [c] Department of BioMedical Engineering, Steadman, Philippon Research Institute, 181 West Meadow Drive, Suite 1000, Vail, CO 81657, USA
* Corresponding author. The Steadman Clinic, 181 West Meadow Drive, Suite 400, Vail, CO 81657.
E-mail address: drlaprade@sprivail.org

Clin Sports Med 33 (2014) 531–545
http://dx.doi.org/10.1016/j.csm.2014.03.005 sportsmed.theclinics.com
0278-5919/14/$ – see front matter

who experience recurrent patellofemoral dislocations because symptoms often do not spontaneously resolve.

Chronic patellar instability is thought to have a multifactorial cause. In a normal patellofemoral joint, the combination of osseous stabilizers in the trochlea and medial soft tissue static stabilizers such as the medial patellofemoral ligament function to resist lateral patellar translation and to maintain patellofemoral stability. Patients with chronic instability routinely present with risk factors for recurrent dislocations, including trochlear dysplasia, patella alta, an increased tibial tubercle–trochlear groove (TT-TG) distance, and insufficiencies in the medial retinacular structures.[2]

Trochlear dysplasia is reportedly present in 85% of patients with patellar instability.[3] For patients with chronic instability secondary to trochlear dysplasia, the trochleoplasty procedure can be an effective treatment option to permanently restore stability.[4] This article highlights the basic anatomy and biomechanics of the patellofemoral joint, describes diagnostic imaging techniques to define and classify trochlear dysplasia, presents indications and the surgical technique for a sulcus-deepening trochleoplasty, and summarizes postsurgical outcomes.

NORMAL TROCHLEAR ANATOMY AND BIOMECHANICS

Anatomy

Normal trochlear bony anatomy confers many biomechanical advantages that contribute to patellofemoral joint stability. The trochlea is located on the anterodistal end of the femur and comprises medial and lateral facets and a central trochlear groove. The lateral facet is the larger of the two facets and extends further proximally.[5,6] The trochlear groove courses through the middle of the trochlea and divides the medial and lateral facets.[5,7] The trochlear groove deepens as it courses distally and its alignment deviates laterally with respect to the anatomic axis of the femoral shaft.[6,8,9] The mean angle of this lateral deviation has been reported to be 19° for cartilaginous surfaces and 16.8° for the osseous surfaces. This angle allows the tibiofemoral joint to be parallel with the ground when viewed in the coronal plane.[10,11] The sulcus angle, which reflects the depth of the trochlear groove, averages 138° ± 6° in a normal trochlea[7] and has been correlated with symptoms of patellofemoral instability.[12] Across the general population, the sulcus angle may vary considerably between individuals.[11]

Biomechanics

The trochlea functions as the counterpart to the patella in patellofemoral joint articulation. At first, as the knee transitions from full extension into flexion, the patella translates medially until the knee reaches 20° of flexion, at which point the patella engages the trochlear groove and translates an average of 11.5 mm laterally up to 90° of flexion.[13] The initial medial deflection of the patella into the trochlear groove is commonly referred to as the catching mechanism.[11] Laterally directed patellar tracking can be attributed to the normal off-axis valgus alignment of the trochlear groove relative to the femur.[13]

The patella is most susceptible to dislocation between 0° and 20° of flexion because of disengagement with the trochlea and a slack medial patellofemoral ligament restraint.[13] The dynamic traction force exerted by the quadriceps muscles is minimized in extension, which further contributes to patellar instability in this position. However, beyond 30° of flexion, the quadriceps are again able to exert a sufficient traction force to stabilize the patella within the trochlear groove.[11,14] In addition, in deep knee flexion, the patella becomes further stabilized to pathologic lateral displacement because of the posteriorly directed resultant force of the quadriceps muscles that ensures close contact with the lateral trochlear facet.[11,14]

THE ANATOMY AND BIOMECHANICS OF TROCHLEAR DYSPLASIA

Anatomy

Trochlear dysplasia is defined as any bony change or variation in the trochlear groove or medial or lateral facet. The defining characteristic of trochlear dysplasia is a shallow, flattened trochlea,[15] which is quantitatively defined as an increased sulcus angle. A sulcus angle greater than 145° is considered dysplastic and is generally defined as a shallow trochlea.[3,7,16] In addition, abnormal patellar tilt and patellar height may also contribute to an abnormally increased sulcus angle.[12] As the sulcus angle increases, the depth of the trochlear groove relative to the medial and lateral facets decreases. In one study, patients presenting with symptomatic patellar instability had a reported depth of 2.3 ± 1.8 mm compared with a depth of 7.8 ± 1.5 mm in an asymptomatic control group.[3]

Biomechanics

Abnormal bony anatomy associated with a dysplastic trochlea alters the biomechanics of the patellofemoral joint substantially because of a lack of inherent bony stability. A dysplastic trochlea is strongly correlated with a history of patellofemoral joint instability.[3,17] A shallow trochlea permits unbounded and pathologic lateral displacement of the patella.[18] The decreased resistance to lateral patellar translation resulting from a shallow lateral facet places increased stress on the medial soft tissue restraints, primarily the medial patellofemoral ligament (MPFL).[15] It has been reported that a dysplastic trochlea is more likely to result in lateral patellar displacement than either a ruptured medial retinaculum or a vastus medialis obliquus release.[18] For this reason, when patellar instability is suspected, it is important to assess trochlear morphology as the possible cause because of its significant contributions to patellar stability.

DIAGNOSIS OF TROCHLEAR DYSPLASIA

History and Physical Examination

When evaluating patients with suspected trochlear dysplasia, it is essential to begin by obtaining a detailed history to discern whether the presenting symptoms are the result of an acute dislocation or chronic instability. Inspection of the knee may reveal a patella that sits laterally and proximal relative to the trochlea. Other changes such as bruising, swelling, or effusion should also be assessed. On physical examination, the clinician must check patellar mobility to test for excessive laxity. The patella can be separated into 4 equal sections, also known as quadrants, which divide the patella into quarters from medial to lateral. When a laterally directed force is applied to the patella, normal patellar mobility should remain within 2 quadrants compared with the resting state.

The patellar apprehension test is also an excellent indicator of patellofemoral instability.[19,20] The patellar apprehension test is performed by applying a laterally directed force on the patella as the knee transitions from full extension into flexion. This test functionally mimics a lateral patellar dislocation.[21] A positive test is defined as visible apprehension or activation of the quadriceps muscles. The diagnostic accuracy of this test is high, as seen in one series with a reported sensitivity of 100%, a specificity of 88.4%, a positive predictive value of 89.2%, a negative predictive value of 100%, and an accuracy of 94.1%.[21]

Although widely used, the interobserver reliability of the physical examination for assessing patellofemoral joint instability is poor and the intraobserver reliability is only moderate.[22] Even when a thorough history is elicited and a comprehensive physical examination is performed, trochlear dysplasia is challenging to diagnose and is

best evaluated using imaging, which renders a more comprehensive and objective assessment of trochlear morphology.

Radiographic Evaluation

Previous studies have described the use of lateral radiographs for the assessment of abnormal trochlear morphology.[3,23] Lateral radiographs are useful for classifying abnormal trochlear morphology according to the widely used Dejour classification system.[3,24] In the Dejour system, trochlear dysplasia is classified using lateral radiographs as types A through D depending on the presence of a crossing sign, supratrochlear spur, and/or a double contour (**Figs. 1** and **2**). The Dejour grade not only helps to characterize the various manifestations of trochlear dysplasia but may also be useful for formulating a preoperative plan uniquely tailored to each patient.

In addition to lateral radiographs, axial radiographs captured with the knee in 30° of flexion enable assessment of the sulcus angle and the depth of the trochlear groove (**Fig. 3**).[23] A sulcus angle of 145° or greater indicates a dysplastic trochlea.[3] Although the sulcus angle is widely used and well described in the literature, it has several

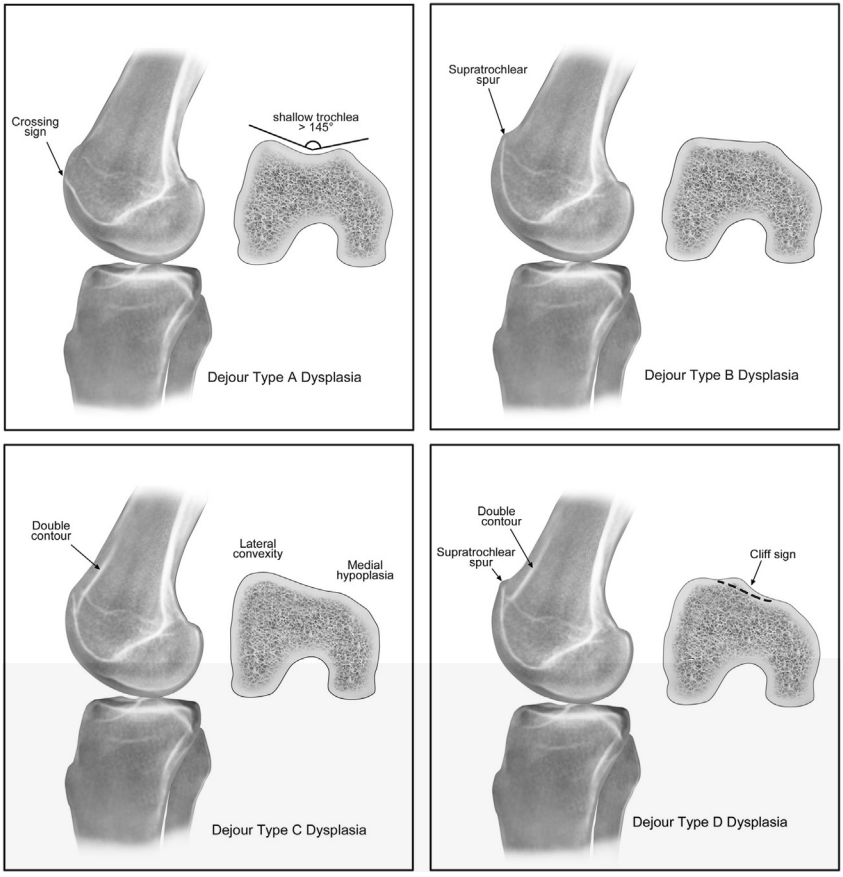

Fig. 1. Lateral radiographic views and axial cross sections representing the 4-part Dejour classification system for trochlear dysplasia. (*Courtesy of* the Steadman Philippon Research Institute, Vail, CO; with permission.)

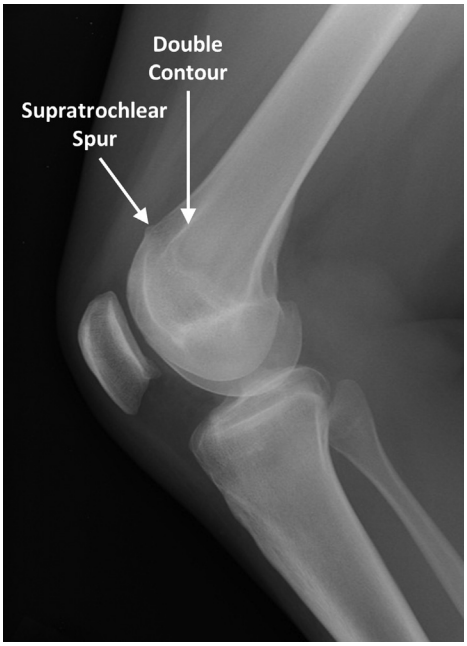

Fig. 2. Features of trochlear dysplasia shown on a lateral radiograph: the double contour and supratrochlear spur.

potential weaknesses. The sulcus angle describes the flatness of the trochlear groove in the transverse plane, but it does not describe side-to-side differences in the inclination of the medial and lateral trochlear facets.[25] For example, a shallow trochlear groove with the same sulcus angle measurement may be caused by a shallow

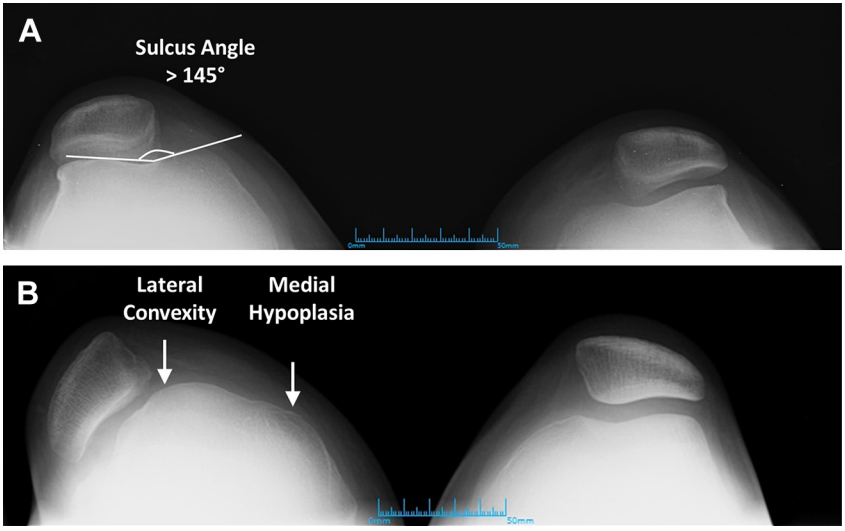

Fig. 3. Sunrise radiographic views showing the Dejour classification system for trochlear dysplasia: (*A*) dysplasia type A with a shallow sulcus angle (right knee); (*B*) dysplasia type C with lateral convexity and medial hypoplasia of the trochlea (left knee).

inclination of the medial and/or lateral facets. Therefore, the medial and lateral trochlear inclination measurements, which describe the inclination of the medial and lateral facets, have been proposed to more precisely characterize abnormal trochlear bony morphology.

Numerous other quantitative radiographic measurements have been described in the literature for trochlear dysplasia. Among the various quantitative radiographic methods for characterizing trochlear morphology, including the sulcus angle, lateral trochlear inclination, and medial trochlear inclination, a flattened lateral trochlear inclination is considered the best predictor of both lateral patellar displacement and lateral patellofemoral articular cartilage lesions.[25,26] However, these quantitative measurements do not correlate with the Dejour 4-grade classification system and may be unreliable when performed for high grades of dysplasia.[27,28] In cases of extreme trochlear disorder in which a trochleoplasty is the treatment of choice, some trochlear landmarks appear amorphic on imaging, making quantitative measurements difficult to perform. Therefore, because of the strengths and weaknesses of each radiographic diagnostic technique, trochlear dysplasia is best characterized using a combination of quantitative radiographic measurements and the Dejour classification system.

Magnetic Resonance Imaging

Magnetic resonance imaging (MRI) is also an important diagnostic tool to evaluate soft tissue injury and the health of the articular cartilage in patients with patellofemoral instability. In addition, MRI can be used to calculate the lateral trochlear inclination.[25,26] The lateral trochlear inclination is a measure of the angle created between a line adjacent to the posterior edges of the femoral condyles and a second line tangential to the subchondral bone of the lateral trochlear facet.[9] A shallow lateral trochlear inclination has been positively correlated with the presence of anterior knee pain.[29] On the axial view, Biedert and Bachmann[30] reported that the height of the central trochlear groove to the medial facet was decreased in 83% of patients with patellar instability. By comparison, the height of the central trochlear groove relative to the lateral facet was decreased in only 17% of patients. Lippacher and colleagues[31] reported the best overall agreement between type B Dejour dysplasia and measurements performed on MRI. By comparison, lateral radiographs generally underestimated trochlear dysplasia compared with axial MRI.

TT-TG Distance

The TT-TG distance is used to determine the degree of lateralization of the tibial tubercle in relation to the deepest part of the trochlear groove (**Fig. 4**). A TT-TG distance of more than 20 mm on computed tomography (CT) scans is considered to be pathologic and is a significant risk factor for patellar instability.[3] In one study, patients with patellar dislocation had an average TT-TG distance that was 4 mm larger than healthy patients.[32] There has been some debate as to whether to normalize the TT-TG distance, because the TT-TG distance has been shown to vary with increasing age and height.[33] At present, CT is considered the gold standard for measurement, but there is disagreement as to whether TT-TG distances measured on MRI can be considered interchangeable with those measured on CT.[34,35]

Arthroscopy

Arthroscopic classification of trochlear dysplasia has recently been described with excellent intraobserver and interobserver reliability.[36] Neiltz and colleagues described a 2-part classification system for trochlear dysplasia that could be distinguished on arthroscopic examination.[37] Neiltz type I trochlear dysplasia was defined as a flat

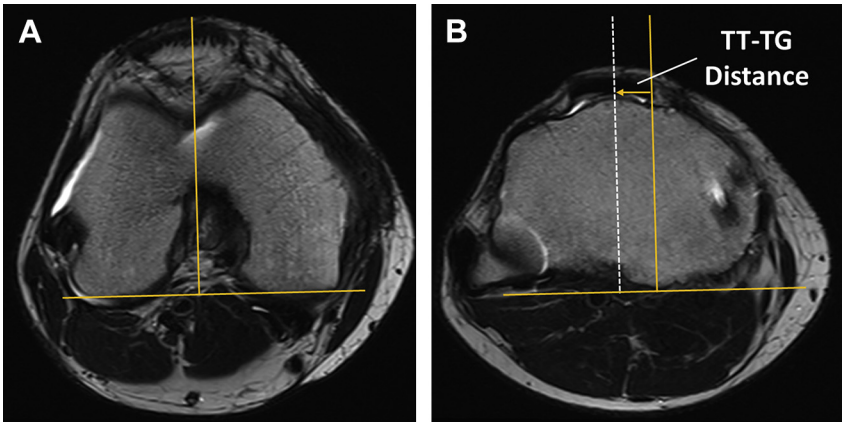

Fig. 4. (*A*) The measurement technique for the TT-TG distance consists of creating a posterior intercondylar line and 2 perpendicular lines to the posterior intercondylar line: one extended through the center of the deepest part of the trochlear groove and a second through the center of the patellar tendon attachment on the tibial tubercle. (*B*) The distance between the trochlear groove and tibial tubercle lines represents the TT-TG distance.

trochlear groove and an elevated trochlear floor. Neiltz type II trochlear dysplasia was defined as a convex proximal trochlea combined with a lateral trochlear bump. However, these types did not correspond with the standard Dejour classification system.

NATURAL HISTORY

The natural history of recurrent patellar dislocation caused by trochlear dysplasia has been well defined. For acute dislocations, Colvin and West[38] investigated nonoperative treatment after an acute lateral patellar dislocation and showed that physical therapy and bracing can be effective. However, after an acute dislocation event, the presence of trochlear dysplasia increases the risk of recurrent dislocations[39] and outcomes are worse for patients with chronic patellofemoral instability. Arnbjornsson and colleagues[40] showed poor outcomes after nonoperative treatment of chronic instability including physical therapy, with 5 of 21 knees showing degenerative changes in patients with a mean age of just 39 years. Lewallen and colleagues[41] studied the risk factors associated with development of recurrent patellar dislocation in a pediatric and adolescent population after a first-time dislocation. In these patients, recurrent instability was significantly correlated with trochlear dysplasia. Patients with open physes and trochlear dysplasia had a recurrence rate of 69%. Nonoperative management in these patients was successful in only 31% of cases. In another series, trochlear dysplasia was present in 85% of patients with recurrent instability.[3] Because patellofemoral instability is often recurrent in patients with trochlear dysplasia, surgical correction must be strongly considered when nonoperative treatment fails.

TREATMENT OPTIONS

Patellar instability in the setting of trochlear dysplasia can be problematic to treat. Patients with a history of more than one dislocation and failed conservative treatment, such as physical therapy and bracing, should consider surgical intervention. Trochleoplasty is recommended for patients with recurrent instability and trochlear dysplasia. Several techniques for trochleoplasty have been described in the literature, but the

elevation of the lateral trochlear facet and the trochlear-deepening procedure are currently the most widely used.

Elevation of the lateral facet for treatment of trochlear dysplasia was first described by Albee.[42] In this procedure, an opening wedge osteotomy of the lateral facet is performed by elevating the facet with a bone wedge to effectively deepen the trochlea. There are some concerns that when the lateral facet is elevated by more than 6 mm it may increase contact pressures in the patellofemoral joint.[43] The trochlear-deepening procedure was first described by Masse[44] in 1978 before being modified by Dejour and Saggin[6] in 1987. Bereiter and Gaultier[45] also described similar procedure. In general, to perform the trochlear-deepening procedure the articular cartilage is peeled off and the subchondral bone is resected in order to recreate a normal-shaped trochlea. The deepening procedure is favored rather than the lateral facet elevation procedure because of the risk of overconstraining the patellofemoral joint and increasing the stress on the articular cartilage.

When performing a trochleoplasty on a patient with recurrent instability, it is imperative to assess the entire patellofemoral joint and to treat associated disorders concurrently. First, the medial soft tissue structures should be evaluated on MRI during the preoperative planning phase and assessed again using direct visualization during the surgery. Because the MPFL has been shown to provide up to 60% of resistance to lateral displacement of the patella,[46] anyone with recurrent instability should be considered for an MPFL reconstruction with the goal of restoring normal patellofemoral kinematics.

Patients with patella alta or a TT-TG distance greater than 20 mm may require a tibial tubercle osteotomy. A distalization of the tubercle is recommended for patients presenting with patella alta. A medialization and/or an anteriorization of the tubercle is recommended for patients with a TT-TG measurement greater than 20 mm to decrease contact pressures on the lateral trochlear and patellar facets. In light of a recent study that reported a decreased TT-TG in young and short patients,[33] some patients with a TT-TG distance only slightly less than the traditional 20 mm threshold may still be considered candidates for a tibial tubercle osteotomy at the discretion of the treating surgeon.

INDICATIONS FOR A TROCHLEOPLASTY

First-time acute patellar dislocations should be treated nonoperatively in a brace. Patients with a history of chronic dislocations with Dejour type A trochlear dysplasia should undergo a medial-sided soft tissue reconstruction rather than a trochleoplasty. A sulcus-deepening trochleoplasty is recommended for Dejour types B, C, and D dysplasia. Specifically, type C can also be considered for a lateral facet–elevating trochleoplasty, although this remains controversial because of the theoretic risk of increasing contact pressures in the patellofemoral joint. An MPFL reconstruction should be performed in conjunction with any trochleoplasty procedure.[6]

A trochleoplasty is contraindicated in patients with open physes. Instead, a medial soft tissue procedure such as an MPFL reconstruction should be proposed as a safe surgical alternative in these patients. In addition, a trochleoplasty is also contraindicated in patients with diffuse patellofemoral arthritis because of a significant risk of increasing pain levels.

SULCUS-DEEPENING TROCHLEOPLASTY AND MPFL RECONSTRUCTION

Surgical Procedure

The patient is induced under general anesthesia and positioned supine on the operating table. A high thigh tourniquet is placed and a thorough examination under

anesthesia is performed to confirm the preoperative diagnosis. An anterior midline incision is created along with a medial parapatellar arthrotomy.

The course of the MPFL is followed along the distal edge of the vastus medialis obliquus (VMO) with a sharp dissection medially, and the adductor magnus tendon is identified. Using the adductor magnus tendon as a landmark, the adductor tubercle and medial epicondyle are identified. The femoral attachment of the MPFL is located at a point 1.9 mm anterior and 3.8 mm distal to the adductor tubercle[47] and 2 suture anchors are placed in this location. The MPFL attachment on the patella is then identified, which is approximately 41% from the proximal pole, and a guide pin is placed transversely across the patella. A cannulated 5-mm reamer is used to ream a tunnel across the patella, and a passing suture is placed through the tunnel. As an alternative, for a small patella, a small trough can be created with a bur and a cortical button device can be used to secure the graft to the medial patella.

If an autograft is used, the semitendinosus tendon is identified within the pes anserine bursa and harvested with an open tendon stripper. The graft is then tubularized and prepared on the back table. The graft should be at least 16 cm in length.

Attention is then turned to exposing the trochlea (**Fig. 5**). A scalpel is used to elevate the periosteum 5 to 6 mm away from the articular cartilage margins along the proximal femur. From medial to lateral, 3 Kirschner wires (K-wires) are placed parallel to the joint, 3 to 4 mm posterior to the subchondral bone of the trochlea with the use of an anterior cruciate ligament guide (**Fig. 6**). An osteotome is then used to connect the K-wires in a proximal to distal fashion down to the sulcus terminalis. Once the articular cartilage is elevated from the femur, the osteotome is used to carefully create a V shape in the subchondral bone. Once this is completed, a high-speed burr is used to undermine the subchondral bone on the articular cartilage flap to help press the cartilage margins into position (**Fig. 7**). The flap is then pushed into the newly created trough. When good trochlear position is confirmed, the flap is secured with 2 biocompression screws into both the medial and lateral trochlear facets.

Next, the MPFL graft is passed transversely across the previously created channel along the normal course of the native MPFL deep to the superficial layer of the medial retinaculum, just distal to the VMO, and is tied to the suture anchors at the femoral attachment. Using the passing suture in the patella, the graft is pulled through the patella and brought back and tied on itself in a neutral position in the trochlea at 40°of knee flexion while being careful not to overmedalize the patella. Once the graft has a few sutures in place, the patella is tested with lateral translation at varying degrees of

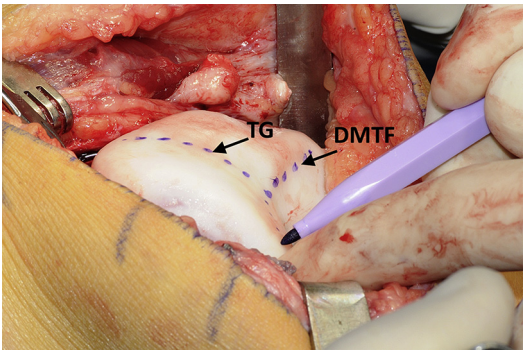

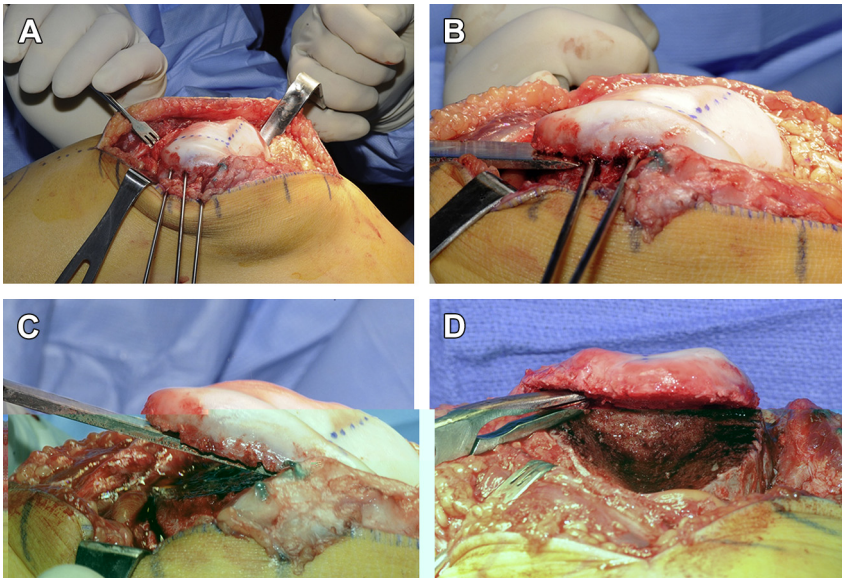

Fig. 6. (*A*) A trochleoplasty is performed by making a parapatellar longitudinal incision and placing guide pins underneath and parallel to the trochlear groove; (*B*) an osteotome is used to free the trochlea by following the guide pins; (*C*) the trochlea is elevated; (*D*) bone is resected below the trochlea to create a deepened sulcus (left knee).

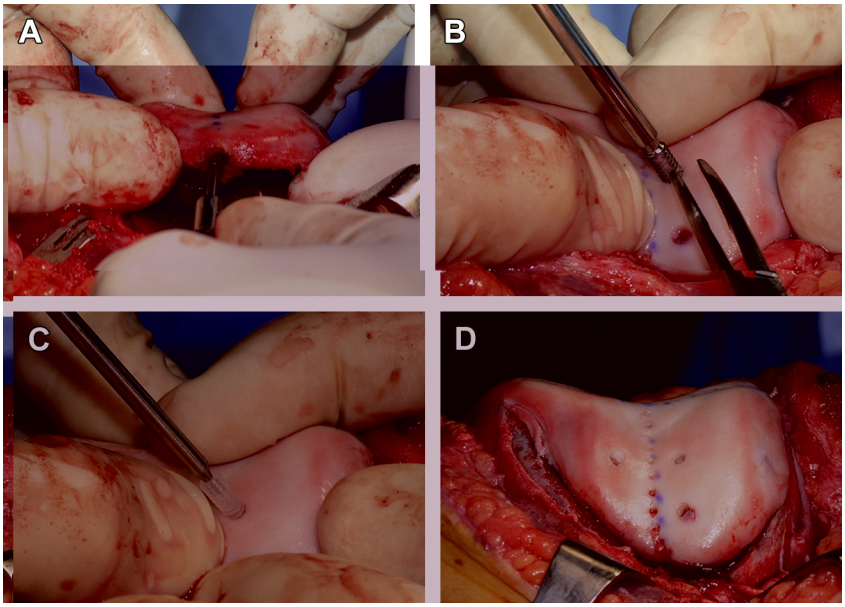

Fig. 7. (*A*) The trochleoplasty is performed using a bur to facilitate creation of a decreased sulcus angle; a tap (*B*) is used to prepare attachment sites for bioabsorbable screws (*C*), which secure the deepened trochlea as it heals; (*D*) the completed sulcus-deepening trochleoplasty (left knee).

Table 1
Review of outcomes after trochleoplasty

Author Ref, Year	Number of Knees	Mean and Range of Follow-Up (mo)	Outcomes
Goutallier et al,[51] 2002	12	48 (24–72)	67% satisfaction rate
Schöttle et al,[53] 2005	19	36 (24–48)	16 of 19 knees improved subjectively Kujala score increased from 56 to 80 points
Verdonk et al,[49] 2005	13	18 (8–34)	Larsen-Lauridsen scoring system: 7 patients scored poor, 3 fair, 3 good; 77% of patients reported good or very good results subjectively
Donell et al,[54] 2006	17	36 (12–108)	Seven patients were very satisfied, 6 were satisfied, and 2 were disappointed. Kujala score average of 48 (range 13–75) to 75 (range 51–98) out of 100
von Knoch et al,[50] 2006	48	100 (48–168)	Mean Kujala score, 94.9 (range, 80–100)
Fucentese et al,[55] 2007	17	36 (24–48)	Trochleoplasty created more normal anatomy
Utting et al,[4] 2008	59	24 (12–58)	92.6% of patients satisfied Oxford knee score, 26 (12–43) to 19 (12–44) WOMAC score, 23 (12–35) to 17 (12–34) IKDC score, 54 (26–89) to 72 (23–100) Kujala score, 62 (29–92) to 76 (26–100) Lysholm score, 57 (25–91) to 78 (30–100)
Zaki et al,[56] 2010	27	54 (12–72)	33% had residual symptoms Lysholm score improved from a mean preoperative score of 54 (range, 32–61) to a mean 83 (good to excellent) in 19 (70%) and 65–83 (fair) in 8 (30%) knees
Thaunat et al,[57] 2011	19	34 (12–71)	Kujala score, 80 (±17) KOOS score, 70 (±18) IKDC score, 67 (±17)
Faruqui et al,[20] 2012	6	68.3	WOMAC score increased by 20% KOOS score increased by 74.50%
Koch et al,[58] 2011	2	24	Stable patella with correct tracking Both patients rated their result as excellent
Dejour et al,[59] 2013	24	66 (24–191)	No patellar redislocation Kujala score improved from 44 (25–73) to 81 (53–100)
Nelitz et al,[36] 2013	26	30 (24–42)	Kujala scores improved from 79 to 96 IKDC scores improved from 74 to 90 VAS scores improved from 3 to 1 95.7% of patients were satisfied or very satisfied No recurrent dislocation occurred after surgery
Ntagiopoulos et al,[60] 2013	31	84 (24–108)	IKDC score improved from 51 (range, 25–80) to 82 (range, 40–100) Kujala score improved from 59 (range, 28–81) to 87 (range, 49–100)

Kujala score refers to the Kujala scale for patellofemoral pain.

Abbreviations: IKDC, International Knee Documentation Committee; KOOS, Knee Injury and Osteoarthritis Outcome Score; VAS, Visual Analog Pain Scale; WOMAC, Western Ontario and McMaster Universities Osteoarthritis Index.

knee flexion to confirm restoration of an adequate restraint to lateral translation with no evidence of overtightening medially. Once this is confirmed, the remaining sutures are secured. In addition, the arthrotomy is copiously irrigated and closed. Steri-Strips and a sterile dressing are placed over the incision, and the knee is placed in an immobilizer.

Postoperative Rehabilitation

Patients should remain non–weight bearing for 6 weeks. A continuous passive motion (CPM) machine is used to cycle the knee from 0° to 30° of flexion in order to minimize the risk of arthrofibrosis and to maintain articular cartilage viability. The CPM should be used for 6 to 8 hours per day for a total of 6 weeks after surgery. Passive range of motion should be limited from 0° to 90° of flexion for the first 2 weeks and increased as tolerated thereafter. Return to normal levels of activity generally occurs after 6 to 9 months.

Complications

Postsurgical complications include deep vein thrombosis, infection, and residual skin numbness. Complications specific to trochleoplasty include trochlear cartilage damage, patellar incongruence, and overcorrection.[6] Articular cartilage cell viability is also a concern following trochleoplasty. In one study, Schöttle and colleagues[48] investigated histologic changes in the trochlear articular cartilage following a trochleoplasty procedure in 13 patients. Using confocal microscopy and histologic examination, the articular cartilage appeared normal after undergoing a trochleoplasty procedure. However, small changes were noted in the calcified layer, which requires further investigation. Overall, the results of this study suggest there is minimal risk of cartilage damage after trochleoplasty.

Some patients also experience arthrofibrosis after surgery, although reports on the incidence of this complication are mixed and likely vary as a function of range of motion exercises during postoperative rehabilitation. Verdonk and colleagues[49] reported 5 of 13 patients experienced arthrofibrosis after trochleoplasty, whereas von Knoch and colleagues[50] reported that all of the patients in their cohort had gained full range of motion by the final follow-up with no signs of arthrofibrosis. Early range of motion is critical and may decrease the risk of patients developing postoperative arthrofibrosis.

OUTCOMES AFTER TROCHLEOPLASTY

Outcomes after trochleoplasty with or without MPFL reconstruction are mixed. Previous studies have reported a patient satisfaction rate as low as 67%[51] to as high as 95.7%.[36] Although many outcome measures have been used in the literature to describe results after trochleoplasty, only the Fulkerson and Lysholm scales have been reported to be reliable and valid for differentiating between patients with and without recurrent patellar instability.[52] A summary of outcomes after sulcus-deepening trochleoplasty with or without MPFL reconstruction is presented in **Table 1**.

SUMMARY

The diagnosis and treatment of chronic patellar instability caused by trochlear dysplasia can be challenging. A dysplastic trochlea leads to biomechanical and kinematic changes that often require surgical correction when symptomatic. In the past, trochlear dysplasia was classified using the 4-part Dejour classification system. More recently, new classification systems have been proposed. Future studies are needed to investigate long-term outcomes after trochleoplasty.

REFERENCES

1. Fithian DC, Paxton EW, Stone ML, et al. Epidemiology and natural history of acute patellar dislocation. Am J Sports Med 2004;32:1114–21.
2. Mehta VM, Inoue M, Nomura E, et al. An algorithm guiding the evaluation and treatment of acute primary patellar dislocations. Sports Med Arthrosc 2007;15(2):78–81.
3. Dejour H, Walch G, Nove-Josserand L, et al. Factors of patellar instability: an anatomic radiographic study. Knee Surg Sports Traumatol Arthrosc 1994;2:19–26.
4. Utting MR, Mulford JS, Eldridge JD. A prospective evaluation of trochleoplasty for the treatment of patellofemoral dislocation and instability. J Bone Joint Surg Br 2008;90:180–5.
5. O'Brien M. Clinical anatomy of the patellofemoral joint. Int J Sports Med 2001;2:1–8.
6. Dejour D, Saggin P. The sulcus deepening trochleoplasty – the Lyon's procedure. Int Orthop 2010;34:311–6.
7. Tecklenburg K, Dejour D, Hoser C, et al. Bony and cartilaginous anatomy of the patellofemoral joint. Knee Surg Sports Traumatol Arthrosc 2006;14:235–40.
8. Eckhoff DG, Burke BJ, Dwyer TF, et al. Sulcus morphology of the distal femur. Clin Orthop 1996;331:23–8.
9. Shih YF, Bull AM, Amis AA. The cartilaginous and osseous geometry of the femoral trochlear groove. Knee Surg Sports Traumatol Arthrosc 2004;12:300–6.
10. Shih YF, Bull AM, Amis AA. Geometry of the distal femur: comparison of the cartilaginous and osseous characteristics of the trochlear groove. Knee Surg Sports Traumatol Arthrosc 2003;12:300–6.
11. Amis AA. Current concepts on anatomy and biomechanics of patellar stability. Sports Med Arthrosc 2007;15:48–56.
12. Davies AP, Costa ML, Shepstone L, et al. The sulcus angle and malalignment of the extensor mechanism of the knee. J Bone Joint Surg Br 2000;82(8):1162–6.
13. Amis AA, Senavongse W, Bull AM. Patellofemoral kinematics during knee flexion-extension: an in vitro study. J Orthop Res 2006;24:2201–11.
14. Amis AA, Farahmand F. Biomechanics masterclass: extensor mechanism of the knee. Curr Orthop 1996;10:102–9.
15. Bollier M, Fulkerson JP. The role of trochlear dysplasia in patellofemoral instability. J Am Acad Orthop Surg 2011;19:8–16.
16. van Huyssteen AL, Hendrix MR, Barnett AJ, et al. Cartilage-bone mismatch in the dysplastic trochlea: an MRI study. J Bone Joint Surg Br 2006;88:688–91.
17. Eckhoff DG, Montgomery WK, Stamm ER, et al. Location of the femoral sulcus in the osteoarthritic knee. J Arthroplasty 1996;11(2):163–5.
18. Senavongse W, Amis AA. The effects of articular, retinacular, or muscular deficiencies on patellofemoral joint stability. J Bone Joint Surg Br 2005;87:577–82.
19. Sallay PI, Poggi J, Speer KP, et al. Acute dislocation of the patella. A correlative pathoanatomic study. Am J Sports Med 1996;24:52–60.
20. Faruqui S, Bollier M, Wolf B, et al. Outcomes after trochleoplasty. Iowa Orthop J 2012;32:196–206.
21. Ahmad CS, McCarthy M, Gomez JA, et al. The moving patellar apprehension test for lateral patellar instability. Am J Sports Med 2009;37:791–6.
22. Smith TO, Clark A, Neda S, et al. The intra- and inter-observer reliability of the physical examination methods used to assess patients with patellofemoral joint instability. Knee 2012;19:404–10.
23. Malghem J, Maldague B. Depth insufficiency of the proximal trochlear groove on lateral radiographs of the knee: relation to patellar dislocation. Radiology 1989;170:507–10.

24. Dejour D, Le Coultre B. Osteotomies in patellofemoral instabilities. Sports Med Arthrosc 2007;15:40.
25. Stefanik JJ, Roemer FW, Zumwalt AC, et al. Association between measures of trochlear morphology and structural features of patellofemoral joint osteoarthritis on MRI: the MOST study. J Orthop Res 2012;30:1–8.
26. Stefanik JJ, Zumwalt AC, Segal NA, et al. Association between measures of patella height, morphologic features of the trochlea, and patellofemoral joint alignment: the MOST study. Clin Orthop Relat Res 2013;471:2641–8.
27. Nelitz M, Lippacher S, Reichel H, et al. Evaluation of trochlear dysplasia using MRI: correlation between the classification system of Dejour and objective parameters of trochlear dysplasia. Knee Surg Sports Traumatol Arthrosc 2014;22(1):120–7.
28. Carrillon Y, Abidi H, Dejour D, et al. Patellar instability: assessment on MR images by measuring the lateral trochlear inclination-initial experience. Radiology 2000;216:582–5.
29. Keser S, Savranlar A, Bayar A, et al. Is there a relationship between anterior knee pain and femoral trochlear dysplasia? Assessment of lateral trochlear inclination by magnetic resonance imaging. Knee Surg Sports Traumatol Arthrosc 2008;16:911–5.
30. Biedert RM, Bachmann M. Anterior-posterior trochlear measurements of normal and dysplastic trochlea by axial magnetic resonance imaging. Knee Surg Sports Traumatol Arthrosc 2009;17:1225–30.
31. Lippacher S, Dejour D, Elsharkawi M, et al. Observer agreement on the Dejour trochlear dysplasia classification: a comparison of true lateral radiographs and axial magnetic resonance images. Am J Sports Med 2012;40:837–43.
32. Balcarek P, Ammon J, Frosch S, et al. Magnetic resonance imaging characteristics of the medial patellofemoral ligament lesion in acute lateral patellar dislocations considering trochlear dysplasia, patella alta, and tibial tuberosity-trochlear groove distance. Arthroscopy 2010;26:926–35.
33. Pennock AT, Alam M, Bastrom T. Variation in tibial tubercle-trochlear groove measurement as a function of age, sex, size, and patellar instability. Am J Sports Med 2014;42(2):389–93.
34. Schoettle PB, Zanetti M, Seifert B, et al. The tibial tuberosity-trochlear groove distance; a comparative study between CT and MRI scanning. Knee 2006;13:26–31.
35. Camp CL, Stuart MJ, Krych AJ, et al. CT and MRI measurements of tibial tubercle-trochlear groove distances are not equivalent in patients with patellar instability. Am J Sports Med 2013;41:1835–40.
36. Nelitz M, Dreyhaupt J, Lippacher S. Combined trochleoplasty and medial patellofemoral ligament reconstruction for recurrent patellar dislocations in severe trochlear dysplasia: a minimum 2-year follow-up study. Am J Sports Med 2013;41:1005–12.
37. Nelitz M, Lippacher S. Arthroscopic evaluation of trochlear dysplasia as an aid in decision making for the treatment of patellofemoral instability. Knee Surg Sports Traumatol Arthrosc 2013. [Epub ahead of print].
38. Colvin AC, West RV. Patellar instability. J Bone Joint Surg Am 2008;90:2751–62.
39. Cash J, Hughston JC. Treatment of acute patellar dislocation. Am J Sports Med 1988;16:244–9.
40. Arnbjornsson A, Egund N, Ryding O, et al. The natural history of recurrent dislocation of the patella: long-term results of conservative and operative treatment. J Bone Joint Surg Br 1992;72:140–2.
41. Lewallen LW, McIntosh AL, Dahm DL. Predictors of recurrent instability after acute patellofemoral dislocation in pediatric and adolescent patients. Am J Sports Med 2013;41:575–81.

42. Albee FH. The bone graft wedge in the treatment of habitual dislocation of the patella. Med Rec 1915;88:257–9.
43. Kuroda R, Kambic H, Valdevit A, et al. Distribution of patellofemoral joint pressures after femoral trochlear osteotomy. Knee Surg Sports Traumatol Arthrosc 2002;10:33–7.
44. Masse Y. Trochleoplasty. Restoration of the intercondylar groove in subluxations and dislocations of the patella. Rev Chir Orthop Reparatrice Appar Mot 1978;64: 3–17.
45. Bereiter HG, Gautier E. Die Trochleoplastik ale chirurgishe Therapie der rezidivierenden Patellauxation bei Trochleodysplasie des Femurs. Arthroskopie 1994; 7:281–6.
46. Desio SM, Burks RT, Bachus KN. Soft tissue restraints to lateral patellar translation in the human knee. Am J Sports Med 1998;26(1):59–65.
47. LaPrade RF, Engebretsen AH, Ly TV, et al. The anatomy of the medial part of the knee. J Bone Joint Surg Am 2007;89(9):2000–10.
48. Schottle PB, Schell H, Duda G, et al. Cartilage viability after trochleoplasty. Knee Surg Sports Traumatol Arthrosc 2007;15:161–7.
49. Verdonk R, Jansegers E, Stuyts B. Trochleoplasty in dysplastic knee trochlea. Knee Surg Sports Traumatol Arthrosc 2005;13:529–33.
50. von Knoch F, Böhm T, Bürgi ML, et al. Trochleoplasty for recurrent patellar dislocation in association with trochlear dysplasia. A 4- to 14-year follow-up study. J Bone Joint Surg Br 2006;88:1331–5.
51. Paxton EW, Fithian DC, Stone ML, et al. The reliability and validity of knee-specific and general health instruments in assessing acute patellar dislocation outcomes. Am J Sports Med 2003;31:487–92.
52. Goutallier D, Raou D, Van Driessche S. Retro-trochlear wedge reduction trochleoplasty for the treatment of painful patella syndrome with protruding trochleae. Technical note and early results. Rev Chir Orthop Reparatrice Appar Mot 2002; 88(7):678–85.
53. Schöttle PB, Fucentese SF, Pfirrmann C, et al. Trochleoplasty for patellar instability due to trochlear dysplasia: a minimum 2-year clinical and radiological follow-up of 19 knees. Acta Orthop 2005;76:693–8.
54. Donell ST, Joseph G, Hing CB, et al. Modified Dejour trochleoplasty for severe dysplasia: operative technique and early clinical results. Knee 2006;13:266–73.
55. Fucentese SF, Schöttle PB, Pfirrmann CW, et al. CT changes after trochleoplasty for symptomatic trochlear dysplasia. Knee Surg Sports Traumatol Arthrosc 2007;15:168–74.
56. Zaki SH, Rae PJ. Femoral trochleoplasty for recurrent patellar instability: a modified surgical technique and its medium-term results. Curr Orthop Pract 2010;21: 153–7.
57. Thaunat M, Bessiere C, Pujol N, et al. Recession wedge trochleoplasty as an additional procedure in the surgical treatment of patellar instability with major trochlear dysplasia: early results. Orthop Traumatol Surg Res 2011;97:833–45.
58. Koch PP, Fuchs B, Meyer DC, et al. Closing wedge patellar osteotomy in combination with trochleoplasty. Acta Orthop Belg 2011;77:116–21.
59. Dejour D, Byn P, Ntagiopoulos PG. The Lyon's sulcus-deepening trochleoplasty in previous unsuccessful patellofemoral surgery. Int Orthop 2013;37:433–9.
60. Ntagiopoulos PG, Byn P, Dejour D. Midterm results of comprehensive surgical reconstruction including sulcus-deepening trochleoplasty in recurrent patellar dislocations with high-grade trochlear dysplasia. Am J Sports Med 2013;41: 998–1004.