Isolated and Combined Grade-III Posterior Cruciate Ligament Tears Treated with Double-Bundle Reconstruction with Use of Endoscopically Placed Femoral Tunnels and Grafts

Operative Technique and Clinical Outcomes

Stanislav I. Spiridonov, MD, Nathaniel J. Slinkard, MD, and Robert F. LaPrade, MD, PhD

Investigation performed at the University of Minnesota, Minneapolis, Minnesota

The reported prevalence of posterior cruciate ligament (PCL) tears has been reported to range between 3% and 37% of patients with knee ligament injuries[1,2]. It has been reported that the majority of PCL tears are either sports or trauma-related[3]. As grade-III isolated and combined PCL tears may cause subjective and objective functional limitations, it has been recommended that most symptomatic grade-III and most combined ligament injuries be surgically reconstructed[3,4]. Important concerns in chronic grade-III PCL tears and, more importantly, in chronic combined PCL and posterolateral knee injuries are the potential long-term sequelae of functional limitations and the potential development of osteoarthritis[5]. Patients often report continued pain, instability, and loss of function at the time of long-term follow-up with nonoperative treatment[6-8]. Poorer outcomes have also been reported for patients who have increased time between the initial injury and surgical treatment[9,10]. There is also increased articular cartilage degeneration in PCL-deficient knees, most notably in the medial and patellofemoral compartment[8,11].

Disclosure: None of the authors received payments or services, either directly or indirectly (i.e., via his institution), from a third party in support of any aspect of this work. One or more of the authors, or his institution, has had a financial relationship, in the thirty-six months prior to submission of this work, with an entity in the biomedical arena that could be perceived to influence or have the potential to influence what is written in this work. No author has had any other relationships, or has engaged in any other activities, that could be perceived to influence or have the potential to influence what is written in this work. The complete **Disclosures of Potential Conflicts of Interest** submitted by authors are always provided with the online version of the article.

The PCL has been reported to have two functional bundles, the anterolateral and posteromedial bundle[10,12]. The larger anterolateral bundle serves as the main restraint to posterior translation[13-16] and has been reported to be under the greatest tension when the knee is at 90° of flexion[17]. The smaller posteromedial bundle provides posterior translation stability as the knee nears full extension and functions as a secondary restraint to external rotation[18-20].

Single-bundle PCL reconstructions primarily reconstruct the anterolateral bundle[4,19]. It has been theorized that solely reconstructing the anterolateral bundle, especially for chronic PCL tears, may result in residual posterior knee laxity[21]. However, biomechanical studies comparing single and double-bundle PCL reconstructions have been inconclusive. While significant improvements for transtibial double-bundle compared with single-bundle PCL reconstructions were reported in one study[22], another reported no difference between double-bundle PCL and tibial inlay reconstructions[23].

It is recognized that the quadriceps muscle is an important dynamic stabilizer in patients with PCL injuries. Restoration of quadriceps strength is an important principle for both nonoperative and postoperative PCL rehabilitation protocols[3,4]. Thus, surgical techniques in which an incision through the vastus medialis obliquus is avoided (an all-inside femoral tunnel and graft method) can theoretically restore quadriceps muscle strength and function more effectively and earlier during postoperative rehabilitation.

Historically, it has been reported that the outcomes of surgical reconstruction for the treatment of symptomatic PCL tears have varied results and need to be improved[4,21]. We believe that this may be due to a lack of reconstruction of both functional bundles of the PCL and to surgical techniques that violate the vastus medialis obliquus. Our purpose was to follow prospectively the outcomes of patients undergoing double-bundle PCL reconstructions placed endoscopically in the femur through a lateral arthroscopic portal to treat grade-III isolated and combined PCL tears. Our hypothesis was that patients would have significantly improved subjective and objective outcomes after an endoscopic technique for double-bundle PCL reconstruction.

Materials and Methods

Patient Demographics

This study was approved by the institutional review board at the University of Minnesota. All patients who underwent an endoscopic double-bundle PCL reconstruction for grade-III isolated or combined PCL tears between June 2005 and April 2008 were followed prospectively. Patients with evidence of an unstable knee with acute multiple ligament injuries, a chronic PCL tear that had not responded to nonoperative treatment, or a chronic combined injury of the PCL and posterolateral or medial and/or posteromedial ligaments of the knee were enrolled. Patients were excluded if they had Kellgren-Lawrence[24] arthritic changes of greater than grade 2, were on corticosteroids, had severe arthrofibrosis, or had an infection. All patients had anteroposterior, lateral, and long-leg alignment radiographs. Four patients with chronic combined PCL and posterolateral injuries of the knee with concurrent genu varus alignment had an initial proximal tibial biplanar osteotomy to correct the alignment prior to a staged double-bundle PCL and anatomic posterolateral knee reconstruction because of the reported high risk of failure of a chronic posterolateral knee reconstruction in patients with genu varus alignment[25,26].

Posterior stress radiographs of both knees with use of the kneeling technique to measure posterior instability were made preoperatively, six months postoperatively, and at the yearly postoperative follow-up visits[27]. While the technique of making posterior stress radiographs of the knee with the patient kneeling has been reported to be equivalent to Telos stress radiographs, there is a potential for error in measurement due to rotation[27]. Our radiology technicians were trained to make true lateral radiographs with minimal rotation of the posterior aspect of the femoral condyles in all patients to minimize any potential measurement error due to rotation. The amount of increased posterior translation for each knee was calculated by a comparison with the normal, contralateral knee according to a previously described technique[27]. In addition, subjective evaluations with the modified Cincinnati[28] and International Knee Documentation Committee (IKDC)[29] knee surveys were completed by all patients both preoperatively and at the time of the final follow-up. The IKDC objective subscores for posterior translation at 90°, single-leg hop, Lachman test, varus opening at 20°, and valgus opening at 20° were also recorded.

Surgical Technique for Endoscopic Double-Bundle PCL Reconstruction

The endoscopic double-bundle PCL reconstruction was performed with use of vertical inferomedial and inferolateral parapatellar arthroscopic portals made adjacent to the patellar tendon. The anterolateral bundle graft was prepared from an Achilles tendon allograft with an 11-mm-diameter and 25-mm-long calcaneal bone plug, and the distal soft-tissue aspect of the graft was trimmed and tubularized at its end with a number-5 nonabsorbable suture. The posteromedial bundle graft was similarly prepared from a 7-mm-diameter semitendinosus tendon allograft by tubularizing each end of the allograft.

The femoral attachments of the anterolateral and posteromedial bundles were marked with an arthroscopic coagulator. A 70° arthroscope was utilized to visualize an arthroscopic shaver placed through a posteromedial arthroscopic portal to debride the PCL tibial attachment. The PCL tibial attachment site was identified by debridement distally along the PCL facet until the popliteus muscle fibers were visualized. Next, a guide pin was drilled, entering the anteromedial aspect of the tibia approximately 6 cm distal to the joint line, which was centered between the anterior tibial crest and the medial tibial border, and exiting posteriorly at the PCL tibial attachment. Intraoperative anteroposterior and lateral radiographs were made to verify pin-placement location, which was desired to be approximately 6 to 7 mm proximal to the so-called champagne-glass drop-off at the PCL facet on the posterior part of the tibia on the lateral radiograph and visualized at the medial aspect of the lateral tibial eminence on the anteroposterior radiograph (Fig. 1).

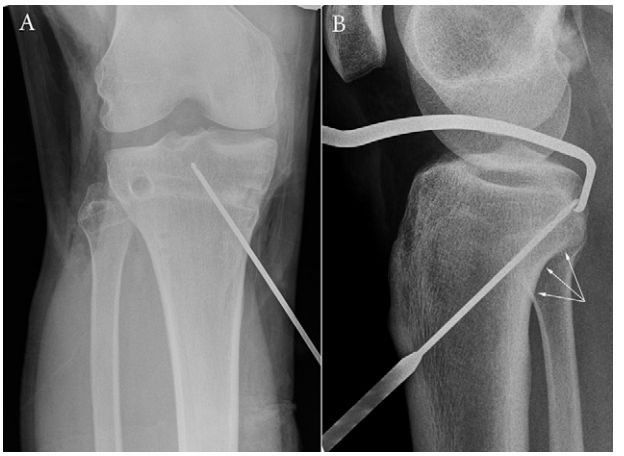

Fig. 1

Intraoperative anteroposterior radiograph of a right knee **(Fig. 1-A)** and lateral radiograph of a left knee **(Fig. 1-B),** demonstrating the desired tibial position for the PCL tibial tunnel guide pin. (The arrows indicate the location of the ''champagne-glass drop-off'' of the posterior part of the tibia.)

The femoral tunnels were prepared while the digital radiographs were developed. An 11-mm reamer attached to a drill chuck was placed through the anterolateral arthroscopic portal and was used as the anterolateral bundle tunnel guide. It was positioned at the previously marked center of the anterolateral bundle of the PCL so that the reamer edges were against the margins of the articular cartilage at the top of the intercondylar roof and along the anterior aspect of the medial femoral condyle. An eyelet pin was then drilled through the reamer anteromedially out of the knee. The 11-mm reamer and drill chuck were then switched to power, and a closed socket tunnel was reamed over the eyelet pin to a depth of 25 mm. With use of the same technique, a 7-mm reamer was placed against the outline of the posteromedial bundle, approximately 8 to 9 mm posterior to the edge of the articular cartilage of the medial femoral condyle and slightly posterior to the anterolateral bundle tunnel, and an eyelet pin was also drilled through this reamer, which exited the anteromedial aspect of the knee. A 25-mm-deep closed socket was likewise reamed. A 2-mm distance was maintained between the two femoral PCL bundle tunnels.

Once radiographic confirmation of the desired tibial guide-pin location was confirmed and/or the guide pin was repositioned as necessary, a 12-mm acorn reamer overreamed the tibial guide pin under direct posterior arthroscopic visualization. A large curet passed through the posteromedial arthroscopic portal, retracted the posterior tissues away from the reamer, and protected against guide-pin protrusion (Fig. 2).

Next, a large smoother (Gore Smoother; W.L. Gore, Flagstaff, Arizona) was passed proximally up the tibial tunnel, and a grasper pulled it out the anteromedial arthroscopic portal. The smoother was gently cycled several times to smooth the intra-articular tibial tunnel aperture. The closed loop tip of the smoother was then pulled back into the joint and passed out the anterolateral arthroscopic portal. An eyelet pin was then reinserted into the posteromedial bundle femoral tunnel through the anterolateral portal. The posteromedial bundle graft was passed into its respective femoral tunnel through the anterolateral arthroscopic portal and into the joint by placing the sutures into the eyelet tip and pulling the pin out the anteromedial aspect of the knee. The posteromedial bundle graft was then fixed with a 7-mm-diameter bioabsorbable interference screw in its femoral tunnel. The bone plug for the anterolateral bundle graft was then similarly passed into its femoral tunnel and secured in the tunnel with a 7-mm-titanium interference screw. The sutures in the ends of both grafts were then tied through the loop tip of the smoother. The grafts were then pulled distally into the tibial tunnel and out the anteromedial aspect of the tibia and individually cycled several times. Arthroscopic verification confirmed that the anterior cruciate ligament (ACL) was reduced to its normal position, while traction was placed on the grafts. In addition, it was verified that the normal tibiofemoral step-off was restored. The anterolateral bundle was now secured to the tibia with a small bone staple with the knee flexed to 90°, in neutral rotation, with an anterior reduction force to the tibia and distal traction applied to the graft. Verification of obliteration of the posterior drawer sign at 90° of knee flexion was confirmed. The posteromedial bundle was then secured to the tibia with the knee in full extension with a medium bone staple placed 2 cm distal to the first staple, while distal traction was placed on the graft.

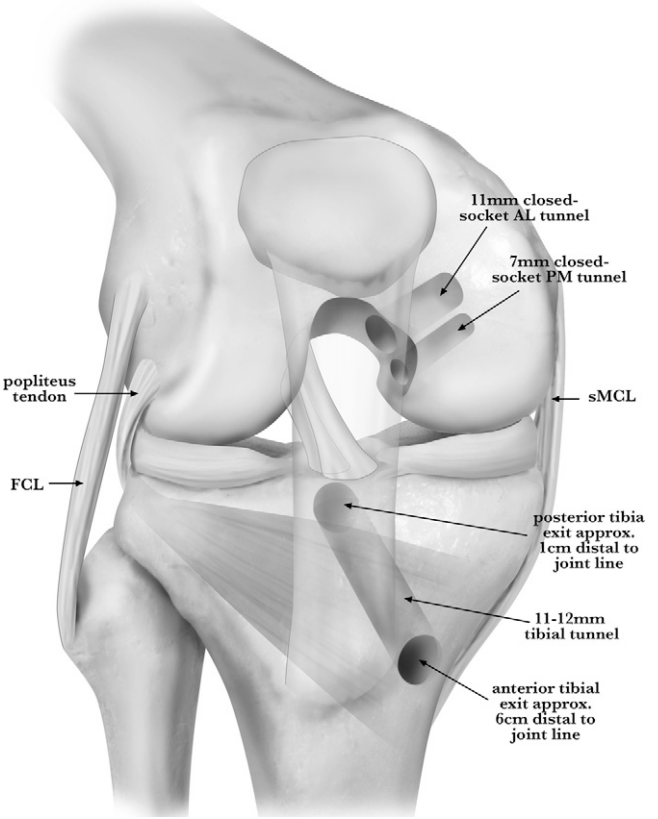

Fig. 2

Illustration of the surgical placement of the endoscopic double-bundle femoral tunnel and tibial tunnel placement in a right knee. FCL = fibular collateral ligament, AL = anterolateral, PM = posteromedial, and sMCL = superficial medial collateral ligament.

Postoperative Rehabilitation

Postoperatively, all patients were non-weight-bearing for six weeks. Physical therapy emphasized quadriceps muscle activation and prone knee flexion from 0° to 90°, and patients were managed with a Jack PCL brace (Albrecht, Stephanskirchen, Germany). Knee motion was increased as tolerated at this time, with prone knee flexion exercises.

Six weeks postoperatively, patients initiated weight-bearing exercises. The use of a stationary bike with low resistance settings and leg presses to a maximum of 70° of knee flexion was initiated. Additional increases in low-impact knee exercises were also allowed as tolerated, starting at twelve weeks postoperatively.

Six months postoperatively, the patients were evaluated clinically and posterior stress radiographs of the knee were made (Fig. 3). If there was objective evidence of adequate healing of the double-bundle PCL reconstructions (<2 mm of increased posterior translation compared with the contralateral knee), patients discontinued the use of the Jack PCL brace, with the exception of patients with ≥2 mm of increased posterior translation, a revision PCL reconstruction, or a body-mass index (BMI) of >35 kg/m^2. The latter patients were instructed to continue wearing the brace at night until one year postoperatively. Patients who were allowed to discontinue the brace initiated a jogging program and side-to-side and proprioceptive exercises. Functional testing was performed between nine and twelve months postoperatively to determine the ability of the patients to return to full activities.

Statistical Analysis

Subjective and objective measures were analyzed preoperatively and at a minimum two-year follow-up with the use of SAS software (version 9.1.3 for Windows; SAS Institute, Cary, North Carolina). The Shapiro-Wilk test determined data distribution. A paired t test compared the preoperative and postoperative subjective and objective data.

Source of Funding

There was no external source of funding.

Results

Patient Data

The patient cohort included thirty-nine patients with an average age of thirty-three years (range, fifteen to sixty-two years), a BMI of 30 kg/m^2 (range, 21 to 41 kg/m^2), a height of 1.8 m (range, 1.6 to 2.0 m), and a weight of 96.9 kg (range, 59.1

TABLE I Demographic Data on Patients Treated with Double-Bundle PCL Reconstruction with Endoscopically Placed Femoral Tunnels and Grafts

Total no. of patients	39
Sex (M/F)	33/6
Average age (range) *(yr)*	33 (15-62)
BMI (kg/m^2)	30 (21-41)
Acute injury/chronic injury *(no. of patients)*	18/21
Procedure type *(no. of patients)*	
Primary/revision	32/7
Isolated/combined	7/32
Follow-up time *(yr)*	2.5 (2.0-4.3)

to 154.5 kg) (Table I). The average range of knee motion was –2° to 127° preoperatively and –2° to 130° postoperatively. Eighteen patients had acute injuries (surgery within six weeks after the injury), and twenty-one had chronic injuries. Seven patients had an isolated reconstruction, while thirty-two had a combined procedure (Table II). The seven patients with an isolated injury were symptomatic for both pain and instability. On the average, they were symptomatic for 15.3 months (range, one to thirty-six months) after the injury and before PCL reconstruction. Eight patients were lost to follow-up prior to a minimum two-year postoperative follow-up, leaving thirty-one patients with an average follow-up of 2.5 years (range, 2.0 to 4.3 years).

Subjective Outcomes Analysis

The mean modified Cincinnati subjective score (and standard deviation) was 34.5 ± 22.2 preoperatively and improved to 73.2 ± 27.3 postoperatively ($p < 0.0001$). The average preoperative subscores for symptoms and function were 13.6 ± 12.6 and 20.8 ± 10.5, respectively. Postoperatively, the average subscores for symptoms and function both significantly improved to 35.4 ± 15.5 ($p < 0.0001$) and 38.2 ± 12.6 ($p < 0.0001$), respectively. A similar significant increase in the postoperative IKDC subjective scores was observed. The average IKDC subjective score increased from 39.3 ± 18.8 preoperatively to 74.3 ± 23.1 postoperatively ($p < 0.0001$).

Data were also analyzed on the basis of whether the injuries were isolated or combined. For the seven patients who had an isolated injury, the average Cincinnati score significantly increased from 49.0 ± 18.4 preoperatively to 87.4 ± 18.0 at the time of the final follow-up ($p < 0.0001$). The average IKDC subjective scores significantly increased from 53.5 ± 12.2 preoperatively to 88.3 ± 14.6 postoperatively ($p < 0.001$), and the posterior stress radiographs demonstrated a significant improvement in average posterior translation from 10.4 ± 1.6 mm preoperatively to 0.7 ± 1.1 mm postoperatively ($p < 0.01$). For the thirty-two patients who had combined injuries, the average Cincinnati scores significantly increased from 33.6 ± 22.3 preoperatively to 67.5 ± 28.0 at the time of final follow-up ($p < 0.0001$), the average IKDC subjective scores increased from 37.7 ± 19.0 preoperatively to 69.3 ± 23.5 postoperatively ($p < 0.0001$), and the average increase in posterior translation on the posterior stress radiographs improved significantly from 16.1 ± 3.7 mm to 0.8 ± 1.1 mm postoperatively ($p < 0.0001$).

The data were also analyzed according to sex. Male patients had a significant increase in the average Cincinnati score from 34.8 ± 21.9 preoperatively to 73.0 ± 26.1 postoperatively ($p < 0.001$). Female patients had a significant increase in the average Cincinnati score from 32.3 ± 26.4 preoperatively to 74.7 ± 27.1 at the time of the final follow-up ($p < 0.001$). No significant difference was detected in the preoperative or

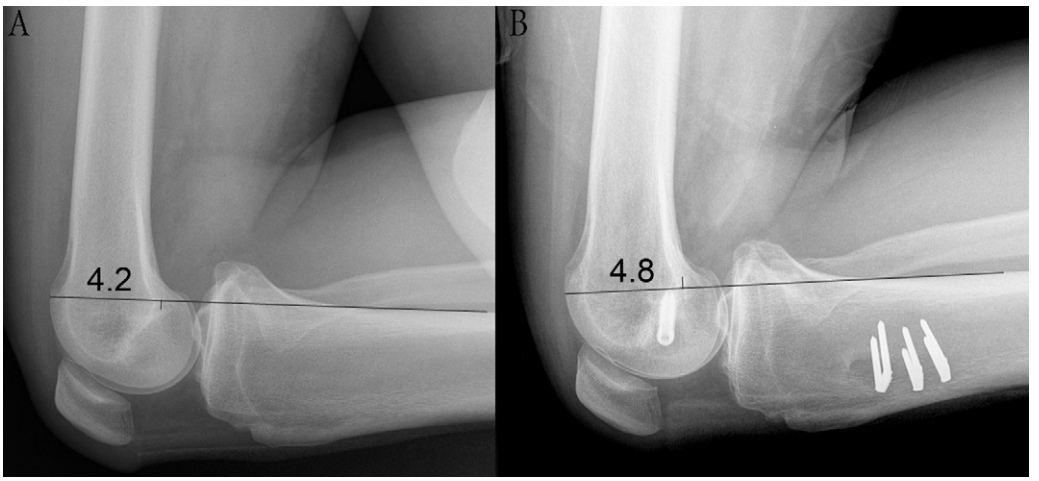

Fig. 3

Figs. 3-A and 3-B Posterior stress radiographs of a right knee for the measurement of posterior instability, demonstrating a 9-mm side-to-side difference in posterior translation between the preoperative and postoperative values. The horizontal line is drawn along the posterior tibial cortex. The vertical line is drawn perpendicular to the horizontal line and touches the posterior aspect of the Blumensaat line in the intercondylar notch. **Fig. 3-A** Preoperative radiograph. **Fig. 3-B** Radiograph made two years postoperatively.

TABLE II Combined Procedures Performed in Thirty-two Patients Treated with Double-Bundle PCL Reconstructions with Endoscopically Placed Femoral Tunnels and Grafts

Procedure*	No. of Patients
PCL and medial knee reconstruction	9
PCL and PLC reconstruction	7
PCL and ACL reconstruction	1
PCL, ACL, and medial knee reconstruction	3
PCL, ACL, and PLC reconstruction	10
PCL, PLC, and medial knee reconstruction	1
PCL, ACL, PLC, and medial knee reconstruction	1

*PCL = posterior cruciate ligament, PLC = posterolateral corner, and ACL = anterior cruciate ligament.

postoperative modified Cincinnati scores between the sexes. For male patients, the average IKDC subjective scores significantly improved from 41.0 ± 18.6 preoperatively to 75.2 ± 22.0 postoperatively ($p < 0.001$). Female patients also had a significant increase in the average IKDC scores from 29.7 ± 16.2 preoperatively to 65.9 ± 18.6 postoperatively ($p < 0.001$). The age of the patients was normally distributed and had no association with sex.

Data were also analyzed on the basis of whether injuries were acute or chronic. For the eighteen patients with an acute injury, the average Cincinnati score was 27.6 ± 22.7 preoperatively and significantly improved to 81.9 ± 21.4 at the time of the final follow-up ($p < 0.0001$). The average IKDC subjective scores significantly increased from 30.1 ± 17.1 preoperatively to 78.6 ± 19.7 postoperatively ($p < 0.0001$), and the increase in posterior translation on posterior stress radiographs significantly improved from an average of 15.6 ± 4.2 mm preoperatively to 0.7 ± 1.2 mm postoperatively ($p < 0.0001$). For the twenty-one patients with a chronic injury, the average Cincinnati scores increased significantly from 40.4 ± 20.5 preoperatively to 68.1 ± 27.7 at the time of the final follow-up ($p < 0.001$), the average IKDC subjective scores increased from 47.1 ± 16.2 preoperatively to 71.8 ± 24.0 postoperatively ($p < 0.001$), and the increase in posterior translation on the posterior stress radiographs improved significantly from 14.5 ± 4.0 mm preoperatively to 1.0 ± 1.2 mm postoperatively ($p < 0.0001$). A significant difference was detected between the acute and chronic groups with respect to preoperative Cincinnati ($p < 0.04$) and IKDC subjective scores ($p < 0.003$), but no significant difference was found between the groups with respect to the postoperative outcomes scores.

Objective Outcomes

Preoperatively, the increased posterior translation on the posterior stress radiographs made with the kneeling technique was an average of 15 ± 4.1 mm compared with the contralateral side. Postoperatively, the average posterior translation demonstrated a significant decrease of 0.9 ± 2.0 mm ($p < 0.001$) compared with the contralateral knee. On preoperative varus stress radiographs of nineteen patients, the increased varus translation was an average of 8.0 ± 5.4 mm. Postoperatively, the average varus translation demonstrated a significant decrease, with an increase of 0.6 ± 1.4 mm compared with the contralateral knee ($p < 0.0001$). Preoperative valgus stress radiographs of fourteen patients demonstrated an average of 5.5 ± 1.5 mm of increased valgus translation. There was a significant postoperative decrease in valgus translation, which averaged 0.4 ± 0.8 mm of increased medial compartment opening compared with the contralateral, normal knee ($p < 0.001$). Preoperative and postoperative IKDC objective subscores for knee stability are listed in Table III and Figure 4.

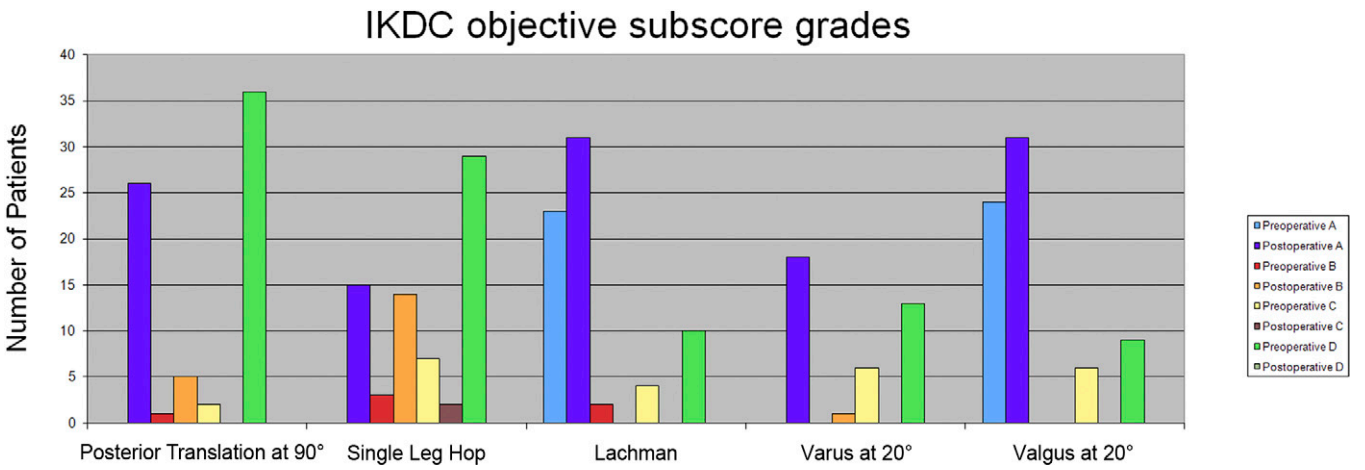

Fig. 4

Preoperative and postoperative International Knee Documentation Committee (IKDC) objective subscores for patients treated with double-bundle PCL reconstructions with endoscopic placement of femoral tunnels and grafts. No patient had grade D postoperatively. A = normal, B = nearly normal, C = abnormal, and D = severely abnormal.

TABLE III Preoperative and Postoperative IKDC Objective Subscores for Patients Treated with Double Bundle PCL Reconstructions with Endoscopically Placed Femoral Tunnels and Grafts

	Preoperative Score* *(no. of patients)*				Postoperative Score* *(no. of patients)*			
Grade	A	B	C	D	A	B	C	D
Posterior translation at 90°	0	1	2	36	26	5	0	0
Single-leg hop	0	3	7	29	15	14	2	0
Lachman test	23	2	4	10	31	0	0	0
Varus opening at 20°	0	0	6	13	18	1	0	0
Valgus opening at 20°	24	0	6	9	31	0	0	0

*Data are given for thirty-one patients who had complete follow-up. A = normal, B = nearly normal, C = abnormal, and D = severely abnormal.

All patients reported compliance with instructions to wear the Jack PCL brace according to protocol. There were no intraoperative neurovascular injuries or postoperative deep venous thromboses or infections. One patient had 4 mm of increased posterior translation but was satisfied with the outcome. Three patients subsequently required deep implant removal.

Discussion

In this study, we confirmed our hypothesis that subjective and objective patient outcomes were significantly improved with endoscopic double-bundle PCL reconstructions. Significant improvements in the modified Cincinnati and the IKDC subjective scores and in objective outcomes were found when sex and acuity of injury were compared. While we did not directly compare our technique with a single-bundle or tibial inlay PCL reconstruction techniques, our postoperative outcomes validate previous biomechanical studies that have noted that a double-bundle PCL reconstruction can restore nearly normal posterior translation stability to a PCL-deficient knee[21,22].

An endoscopic technique of double-bundle PCL femoral tunnel placement provides two clear benefits. First, there is no surgical injury to the vastus medialis obliquus muscle, and postoperative quadriceps reactivation occurs more quickly than with an outside-in technique, which requires an anteromedial incision for the femoral tunnel reaming[30]. With a potential for fewer muscle-splitting incisions, we believe this technique leads to a quicker return of lower-extremity function, decreased scar tissue, and potentially less stress on the healing PCL reconstruction graft. It has been reported that quadriceps muscle dysfunction can last up to two years following an arthroscopic outside-in femoral tunnel PCL reconstruction[30]. Second, graft passage through the tibial tunnel was facilitated when the grafts were passed distally through the anterolateral arthroscopic portal, which decreased the complexity and procedure time for the PCL reconstructions. With a potential for decreased operating time and fewer incisions with this technique, we theorize that patients would be less likely to develop postoperative muscle atrophy and have a more rapid return of knee motion and motor function.

A significant improvement was detected in postoperative posterior knee translation on stress radiographs for both acute and chronic primary and revision double-bundle PCL reconstructions. We theorize that there may be several reasons for this significant improvement in objective knee stability between these varying pathologic conditions. First, the increased volume of the PCL reconstruction graft and the reconstruction of both bundles of the PCL were possible factors in the increased objective stability. Second, the senior author (R.F.L.) established a conservative postoperative rehabilitation program at the initiation of this study because previous studies had noted that objective stability achieved with PCL reconstructions generally was not as good as that achieved with ACL reconstructions[21,31]. It was thought that a more conservative rehabilitation program was indicated on the basis of the recommendations from the workshop on PCL and posterolateral reconstructions at the International Society of Arthroscopy, Knee Surgery, and Orthopaedic Sports Medicine Knee Committee Closed Interim Meeting in Florence, Italy, in 2002[31]. As noted by others[4], the effects of rehabilitation variables on PCL reconstruction outcomes have not been studied to date. Third, PCL reconstructions with concurrent untreated and unrecognized injuries of the posterolateral or medial and/or posteromedial structures of the knee result in increased stress placed on the PCL graft with a higher risk of these grafts stretching out over time[3,32]. The majority of our patients had combined ligament reconstructions; therefore, it is believed that their improved objective outcomes were due to the recognition of this combined ligament pathology and treatment with combined concurrent reconstruction procedures. Finally, all patients in this series reported that they had complied with wearing their Jack PCL brace as prescribed. In addition to helping to negate the deleterious effects of a posterior translation force from gravity on the healing PCL reconstruction graft, it is possible that the brace also assisted with decreasing the patients' activity levels until approximately six months postoperatively, which would allow more time for the grafts to heal.

The operative treatment of PCL injuries continues to be challenging. According to a recent systematic review by Watsend et al.[33], current published studies should be interpreted carefully because of their low methodological quality. Their study was a meta-analysis of forty papers that described the clinical outcomes

of isolated PCL and combined PCL and/or multiple ligament injuries. The authors of the paper hypothesized that studies with high success rates would have low methodological scores based on the Coleman methodology scale. Overall, their study found low scores for current published studies and suggested guidelines for future investigation. From their research, they devised a set of requirements for improving the quality of PCL reconstruction studies, which included the use of a prospective study design, randomized controlled trial, preoperative magnetic resonance imaging and stress radiography, detailed rehabilitation protocols, clinical and functional assessment at a two-year follow-up, written follow-up assessment forms completed by the patient, inclusion and exclusion criteria being clearly established, use of a validated outcome measure, and having no commercial entity pay for or direct the study. With regard to these guidelines, our study was not a randomized controlled trial but met the other eight requirements.

The results of published data for PCL and combined PCL and/or multiple ligament reconstructions, with either single or double-bundle reconstructions, vary not only in their techniques but also in patient outcomes[4]. Some reports on outside-in arthroscopically assisted single-bundle PCL and combined posterolateral reconstructions have noted significant improvements between mean increased side-to-side preoperative (10.4 mm and 12.7 mm) and postoperative (2.3 mm and 2.4 mm) posterior displacement on stress radiography[34,35]. However, others have found that posterior stress radiographs [0] of the knee after reconstruction for a chronic PCL injury continued to have significant clinical amounts of residual posterior translation (>6 mm) in many patients[5,36].

This study has some limitations. First, the double-bundle PCL reconstruction was not the only ligament reconstruction procedure performed for most patients. However, it is well recognized that most PCL reconstructions are not performed in isolation and are usually needed with a concurrent reconstruction of posterolateral or medial and/or posteromedial ligaments. In addition, this report was based solely on the results of double-bundle PCL reconstructions and there was no comparison with a single-bundle PCL reconstruction group. Additional studies to assess differences between this endoscopic technique for femoral tunnel placement and other techniques, as well as studies that minimize quadriceps dysfunction in PCL reconstructions, and a randomized clinical trial comparing this endoscopic technique for femoral tunnel placement with other techniques would be recommended.

In conclusion, we confirmed our hypothesis that the double-bundle PCL reconstruction with use of endoscopic placement of femoral tunnels resulted in significantly improved patient subjective and objective outcome scores. We also found a significant increase in objective knee stability for double-bundle PCL reconstructions with use of endoscopically placed femoral tunnels and grafts. We recommend our approach for double-bundle PCL reconstructions and encourage further studies by other groups to evaluate our surgical technique. ■

Stanislav I. Spiridonov, MD
Nathaniel J. Slinkard, MD
Department of Orthopaedic Surgery,
University of Minnesota, 2515 South 7th Street,
Suite R-200, Minneapolis, MN 55454

Robert F. LaPrade, MD, PhD
The Steadman Clinic, 181 West Meadow Drive,
Suite 400, Vail, CO 81657.
E-mail address: drlaprade@sprivail.org

References

1. Fanelli GC, Edson CJ. Posterior cruciate ligament injuries in trauma patients: part II. Arthroscopy. 1995;11:526-9.

2. Miyasaka KC, Daniel DM, Stone ML, Hirschman P. The incidence of knee ligament injuries in the general population. Am J Knee Surg. 1991;4:43-8.

3. Harner CD, Höher J. Evaluation and treatment of posterior cruciate ligament injuries. Am J Sports Med. 1998;26:471-82.

4. Matava MJ, Ellis E, Gruber B. Surgical treatment of posterior cruciate ligament tears: an evolving technique. J Am Acad Orthop Surg. 2009;17:435-46.

5. Strobel MJ, Weiler A, Schulz MS, Russe K, Eichhorn HJ. Arthroscopic evaluation of articular cartilage lesions in posterior-cruciate-ligament-deficient knees. Arthroscopy. 2003;19:262-8.

6. Jung YB, Tae SK, Lee YS, Jung HJ, Nam CH, Park SJ. Active non-operative treatment of acute isolated posterior cruciate ligament injury with cylinder cast immobilization. Knee Surg Sports Traumatol Arthrosc. 2008;16:729-33.

7. McAllister DR, Petrigliano FA. Diagnosis and treatment of posterior cruciate ligament injuries. Curr Sports Med Rep. 2007;6:293-9.

8. Richter M, Kiefer H, Hehl G, Kinzl L. Primary repair for posterior cruciate ligament injuries. An eight-year followup of fifty-three patients. Am J Sports Med. 1996;24:298-305.

9. Clancy WG Jr, Shelbourne KD, Zoellner GB, Keene JS, Reider B, Rosenberg TD. Treatment of knee joint instability secondary to rupture of the posterior cruciate ligament. Report of a new procedure. J Bone Joint Surg Am. 1983;65:310-22.

10. Harner CD, Xerogeanes JW, Livesay GA, Carlin GJ, Smith BA, Kusayama T, Kashiwaguchi S, Woo SL. The human posterior cruciate ligament complex: an interdisciplinary study. Ligament morphology and biomechanical evaluation. Am J Sports Med. 1995;23:736-45.

11. Van de Velde SK, Bingham JT, Gill TJ, Li G. Analysis of tibiofemoral cartilage deformation in the posterior cruciate ligament-deficient knee. J Bone Joint Surg Am. 2009;91:167-75.

12. Markolf KL, Zemanovic JR, McAllister DR. Cyclic loading of posterior cruciate ligament replacements fixed with tibial tunnel and tibial inlay methods. J Bone Joint Surg Am. 2002;84:518-24.

13. Butler DL, Noyes FR, Grood ES. Ligamentous restraints to anterior-posterior drawer in the human knee. A biomechanical study. J Bone Joint Surg Am. 1980;62:259-70.

14. Fox RJ, Harner CD, Sakane M, Carlin GJ, Woo SL. Determination of the in situ forces in the human posterior cruciate ligament using robotic technology. A cadaveric study. Am J Sports Med. 1998;26:395-401.

15. Gollehon DL, Torzilli PA, Warren RF. The role of the posterolateral and cruciate ligaments in the stability of the human knee. A biomechanical study. J Bone Joint Surg Am. 1987;69:233-42.

16. Markolf KL, Slauterbeck JR, Armstrong KL, Shapiro MS, Finerman GA. A biomechanical study of replacement of the posterior cruciate ligament with a graft. Part II: Forces in the graft compared with forces in the intact ligament. J Bone Joint Surg Am. 1997;79:381-6.

17. Covey DC, Sapega AA, Riffenburgh RH. The effects of sequential sectioning of defined posterior cruciate ligament fiber regions on translational knee motion. Am J Sports Med. 2008;36:480-6.

18. Sekiya JK, Whiddon DR, Zehms CT, Miller MD. A clinically relevant assessment of posterior cruciate ligament and posterolateral corner injuries. Evaluation of isolated and combined deficiency. J Bone Joint Surg Am. 2008;90:1621-7.

19. Sekiya JK, West RV, Ong BC, Irrgang JJ, Fu FH, Harner CD. Clinical outcomes after isolated arthroscopic single-bundle posterior cruciate ligament reconstruction. Arthroscopy. 2005;21:1042-50.

20. Markolf KL, Feeley BT, Tejwani SG, Martin DE, McAllister DR. Changes in knee laxity and ligament force after sectioning the posteromedial bundle of the posterior cruciate ligament. Arthroscopy. 2006;22:1100-6.

21. Lenschow S, Zantop T, Weimann A, Lemburg T, Raschke M, Strobel M, Petersen W. Joint kinematics and in situ forces after single bundle PCL reconstruction: a graft placed at the center of the femoral attachment does not restore normal posterior laxity. Arch Orthop Trauma Surg. 2006;126:253-9.

22. Harner CD, Janaushek MA, Kanamori A, Yagi M, Vogrin TM, Woo SL. Biomechanical analysis of a double-bundle posterior cruciate ligament reconstruction. Am J Sports Med. 2000;28:144-51.

23. Bergfeld JA, Graham SM, Parker RD, Valdevit AD, Kambic HE. A biomechanical comparison of posterior cruciate ligament reconstructions using single- and double-bundle tibial inlay techniques. Am J Sports Med. 2005;33:976-81.

24. Kellgren JH, Lawrence JS. Radiological assessment of osteo-arthrosis. Ann Rheum Dis. 1957;16:494-502.

25. LaPrade RF, Johansen S, Agel J, Risberg MA, Moksnes H, Engebretsen L. Outcomes of an anatomic posterolateral knee reconstruction. J Bone Joint Surg Am. 2010;92:16-22.

26. Arthur A, LaPrade RF, Agel J. Proximal tibial opening wedge osteotomy as the initial treatment for chronic posterolateral corner deficiency in the varus knee: a prospective clinical study. Am J Sports Med. 2007;35:1844-50.

27. Jackman T, LaPrade RF, Pontinen T, Lender PA. Intraobserver and interobserver reliability of the kneeling technique of stress radiography for the evaluation of posterior knee laxity. Am J Sports Med. 2008;36:1571-6.

28. Noyes FR, Barber SD, Mooar LA. A rationale for assessing sports activity levels and limitations in knee disorders. Clin Orthop Relat Res. 1989;246:238-49.

29. Irrgang JJ, Anderson AF, Boland AL, Harner CD, Kurosaka M, Neyret P, Richmond JC, Shelborne KD. Development and validation of the International Knee Documentation Committee Subjective Knee Form. Am J Sports Med. 2001;29:600-13.

30. Goudie EB, Will EM, Keating JF. Functional outcome following PCL and complex knee ligament reconstruction. Knee. 2010;17:230-4.

31. Aglietti P. PCL/PLS reconstruction. ISAKOS (International Society of Arthroscopy, Knee Surgery, and Orthopaedic Sports Medicine) Knee Committee Closed Interim Meeting; Cartei, Florence, Italy; 2003. p 1-303.

32. LaPrade RF, Muench C, Wentorf F, Lewis JL. The effect of injury to the posterolateral structures of the knee on force in a posterior cruciate ligament graft: a biomechanical study. Am J Sports Med. 2002;30:233-8.

33. Watsend AM, Osestad TM, Jakobsen RB, Engebretsen L. Clinical studies on posterior cruciate ligament tears have weak design. Knee Surg Sports Traumatol Arthrosc. 2009;17:140-9.

34. Fanelli GC, Edson CJ. Combined posterior cruciate ligament-posterolateral reconstructions with Achilles tendon allograft and biceps femoris tendon tenodesis: 2- to 10-year follow-up. Arthroscopy. 2004;20:339-45.

35. Yoon KH, Bae DK, Song SJ, Lim CT. Arthroscopic double-bundle augmentation of posterior cruciate ligament using split Achilles allograft. Arthroscopy. 2005;21:1436-42.

36. Garofalo R, Jolles BM, Moretti B, Siegrist O. Double-bundle transtibial posterior cruciate ligament reconstruction with a tendon-patellar bone-semitendinosus tendon autograft: clinical results with a minimum of 2 years' follow-up. Arthroscopy. 2006;22:1331-8.e1.