

## Technical Note

# Coracoclavicular Ligament Reconstruction Using a Semitendinosus Graft for Failed Acromioclavicular Separation Surgery

Robert F. LaPrade, M.D., Ph.D., and Brad Hilger, M.D.

---

**Abstract:** Although acromioclavicular joint separations are fairly common, the occurrence of high-grade acromioclavicular separations that require surgery is low. Various modifications of the Weaver-Dunn procedure have been popular and fairly successful methods to treat severe acromioclavicular separations, despite the fact that reconstructions have been done a number of ways. We report on the results of a technique for salvaging failed modified Weaver-Dunn reconstructions using a semitendinosus graft through bone tunnels in the distal clavicle and coracoid to reconstruct the coracoclavicular ligament. **Key Words:** Acromioclavicular separation—Coracoclavicular ligament reconstruction.

---

**A** cromioclavicular (AC) joint separations are fairly common,<sup>1</sup> but the occurrence of high-grade AC separations that require surgery is low.<sup>2,3</sup> Those patients who have had AC joint reconstructions but continue to be symptomatic pose a treatment problem. Whether the issue is a failed surgery with recurrent deformity, chronic symptomatic postoperative pain, or simply a cosmetic deformity, patients and physicians alike strive for preinjury status.

Various modifications of the Weaver-Dunn procedure have been popular and fairly successful<sup>4</sup> methods to treat severe AC separations, despite the fact that

reconstructions have performed a number of ways.<sup>5</sup> Furthermore, it has been accepted that most grade 4-6 AC separations should receive some sort of surgical correction.<sup>5</sup> With the incidence rate of unsatisfactory outcomes of original AC reconstructions estimated to be about 10%,<sup>4-6</sup> the decision needs to be made on how to treat these patients. Therefore, we report the results of a technique for salvaging failed modified Weaver-Dunn reconstructions using a semitendinosus graft to reconstruct the coracoclavicular ligament.

## CASE REPORTS

### Case 1

A 35-year-old, right-hand dominant white man fell off his bicycle onto his right shoulder in June of 1998, resulting in severe pain and deformity. His previous physician's initial plan was to treat this injury conservatively. However, he continued to have significant pain, so a modified Weaver-Dunn reconstruction was performed in November 1999. As soon as the dressing came off the shoulder, the patient immediately noticed a recurrent deformity of the right distal clavicle.

We saw the patient for the first time in January

---

*From the Department of Orthopaedic Surgery, the University of Minnesota, Minneapolis, Minnesota, U.S.A.*

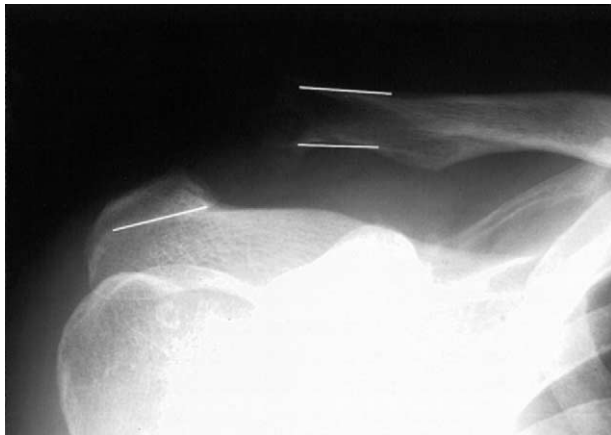
*Address correspondence and reprint requests to Robert F. LaPrade, M.D., Ph.D., Sports Medicine and Shoulder Divisions, Department of Orthopaedic Surgery, University of Minnesota, 2450 Riverside Ave, R200, Minneapolis, MN 55454, U.S.A. E-mail: Lapra001@umn.edu*

© 2005 by the Arthroscopy Association of North America

*Cite this article as: LaPrade RF, Hilger B. Coracoclavicular ligament reconstruction using a semitendinosus graft for failed acromioclavicular separation surgery. Arthroscopy 2005;21:1279.e1-1279.e5 [doi:10.1016/j.arthro.2005.07.020].*

0749-8063/05/2110-4493\$30.00/0

doi:10.1016/j.arthro.2005.07.020



**FIGURE 1.** Anteroposterior radiographic view, right shoulder, shows proximal migration of the distal clavicle after a failed modified Weaver-Dunn reconstruction (white lines drawn to supplement visualization under acromion and superior/inferior surfaces of distal clavicle).

2000. His chief concerns were persistent deformity and limited function of the injured right shoulder, which made his employment as a truck loader difficult while lifting heavy objects over his head.

Physical examination showed a deformity of the right distal AC joint with the distal clavicle prominent and mildly stretching the skin. The right AC joint was able to be reduced by an axial force to the arm, in neutral flexion, through the elbow and by applying posteroinferior pressure to the distal clavicle. Active right shoulder range of motion testing showed forward flexion to 170°, abduction to 170°, external rotation to 70°, and internal rotation to T6. He had normal 5/5 strength testing of the entire right extremity, including the rotator cuff musculature, with some mild giving way of his supraspinatus and anterior deltoid musculature with stress testing as a result of pain. He had pain with cross-body adduction of the arm across the chest. His diagnosis with the help of radiographs was a failed right shoulder Weaver-Dunn reconstruction with a recurrent grade 5 AC joint separation (Fig 1).

## Case 2

A 30-year-old white male supermarket stocker was pinned between 2 vehicles when a van slipped off its supporting jack in May of 2000. He suffered a right shoulder AC separation that was treated 2 weeks later with a modified Weaver-Dunn reconstruction.

Ten months later he presented to our clinic with complaints of persistent pain and deformity despite finishing physical therapy treatments 3 months earlier

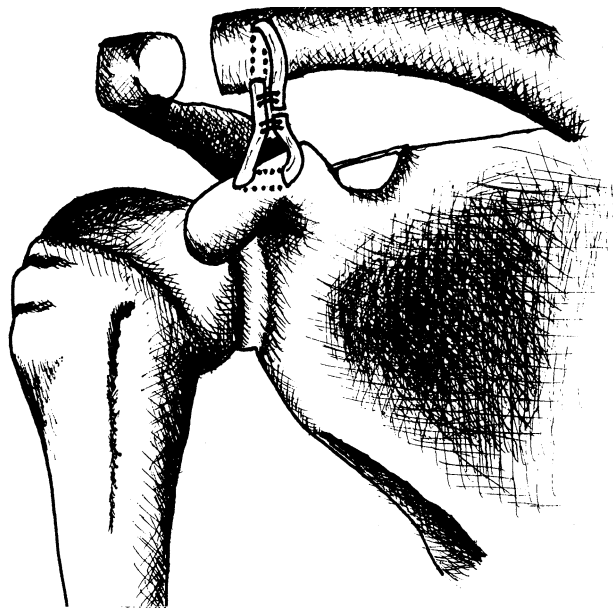
and receiving a postoperative right AC joint corticosteroid injection for pain. On examination, he had significant right scapular winging with fatigue and right levator scapular irritation and spasm to palpation. There was pain both with active range of motion and cross-body adduction testing from a high-riding distal clavicle, as well as pain to palpation of the right AC joint with a clinically significant AC separation.

His specific motion testing for the right shoulder revealed active flexion to 135°, abduction to 135°, external rotation to 50°, and internal rotation to T10. Passive range of motion was full and comparable to the normal contralateral left shoulder. Neer's impingement sign was positive and Hawkin's and Yerguson's test results were negative. Radiographs showed a completely displaced superiorly riding clavicle, shortened 2 cm distally, with a suture anchor at the lateral tip of the clavicle from the previous procedure. His diagnosis was a failed right shoulder Weaver-Dunn reconstruction with a recurrent grade 5 AC separation.

## SURGICAL TECHNIQUE

Patients were placed in the beach-chair position. The incision allowed for visualization of the distal clavicle and coracoid and used previous incisions as necessary. The deltopectoral groove was identified and the cephalic vein was retracted medially. The coracoid was identified as well as the conjoined tendon and pectoralis minor attachments on the coracoid. The superior aspect of the distal clavicle was exposed over its borders by subperiosteal dissection to allow for complete visualization for the revision procedure from its lateral aspect to the level of the normal coracoclavicular ligament attachment medially on the clavicle, leaving the anterior deltoid attachment on the clavicle intact.

We then prepared for placement of the semitendinosus graft by first drilling a hole, 6 mm superior to inferior, at approximately the anterior third of the distal clavicle at the region of the normal coracoclavicular ligament attachment (Fig 2). An 8- to 10-mm bone bridge from the anterior aspect of the clavicle was preserved. A Chandler retractor, placed inferiorly, protected against overpenetration by the drill when reaming superior to inferior through the distal clavicle for this passing tunnel. The coracoid was then identified with an attempt to minimally detach the medial deltoid attachments on the clavicle. A coracoid tunnel was then drilled slightly proximal and medial to the conjoined tendon from lateral to medial. A Chandler retractor was placed posterior to the coracoid for pro-



**FIGURE 2.** A right shoulder semitendinosus graft reconstructing the coracoclavicular ligaments sutured on itself with horizontal mattress fixation after it is pulled through the coracoid and clavicle.

tection. Two 6-mm holes were drilled along the medial and lateral edges of the coracoid and a 90° angled hemostat was placed into each tunnel and gently twisted to complete the tunnel between the 2 drill holes.

The graft was prepared on the back table by tubularizing each end of the semitendinosus allograft with No. 2 sutures to allow it to be passed through the bony tunnels. A No. 2 suture was then placed through the coracoid tunnel and tied to the passing stitches within the hamstring allograft and the sutures were pulled through the coracoid tunnel. The graft was pulled through the tunnel, routed under the deltoid, and positioned under the distal clavicle. The graft was passed from inferior to superior through the distal clavicle tunnel. The 2 arms of the graft were pulled under the deltoid by axial traction until the distal clavicle elevation was completely reduced. Multiple No. 2 non-absorbable sutures were stitched in a horizontal mattress fashion to fix both ends of the graft together in the reduced clavicle position. The clavicle was then tested in the newly reduced position to confirm there was no slack of the graft in situ and stiff graft resistance occurred while attempting to elevate the clavicle superiorly away from the coracoid. Motion was tested to observe the tension on the repair. If greater than 90° of forward elevation could be achieved with no obvious tension on the hamstring/coracoclavicular recon-

struction suture repair, the tail ends of the newly sutured graft loop were excised and the wound was closed.

After skin closure, 30 mL of 0.25% bupivacaine without epinephrine was injected to aid in postoperative analgesia, and patients were placed in a cold compression device and shoulder sling and taken to the recovery room. Initial physical activities for the operative shoulder included pendulum exercises 4 times daily and passive elevation 4 times daily to a maximum of 90° for 6 weeks. Patients were allowed to initiate active motion at 6 weeks postoperatively and rotator cuff and scapular stabilizer exercises were started at 8 weeks. Full activities were allowed once full strength had occurred after 4 months postoperatively.

## FOLLOW-UP

### Case 1

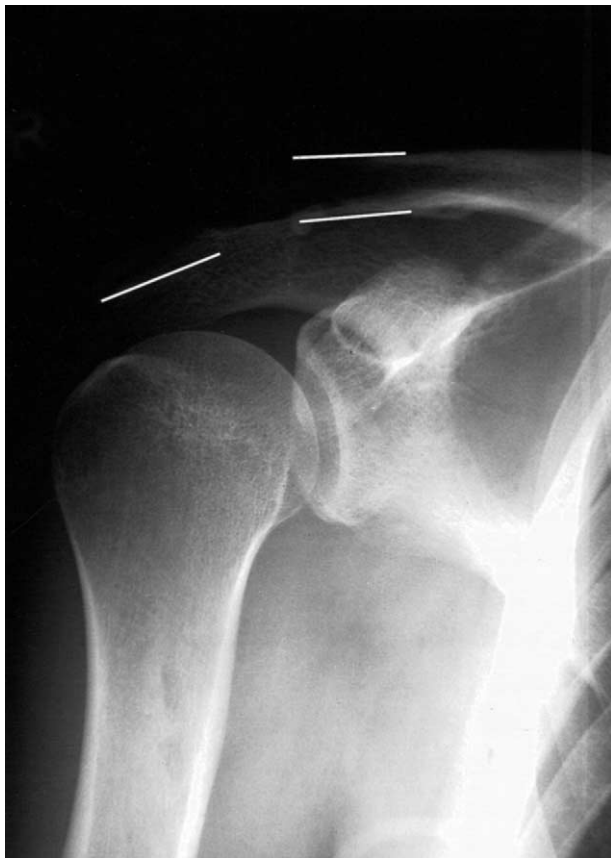Five months after his revision right coracoclavicular ligament reconstruction surgery, the patient was asymptomatic with 5/5 bilateral rotator cuff and anterior deltoid strength with minimal proximal migration of his AC joint in his right shoulder (Fig 3). He was allowed to return to full activities as tolerated. At follow-up at 37 months, he reported no functional limitations and had no recurrent AC joint deformity.

### Case 2

Nine months postoperatively, the patient was able to perform heavy lifting, including weight-room activities like forward military press and latissimus dorsi pull-downs. On examination, he had no step-off deformity of his AC joint with continued equal bilateral shoulder range of motion. He was asymptomatic with cross-body adduction and all muscles in both the operated right and contralateral left shoulder were 5/5 strength. At the final follow-up at 27 months, he noted no functional limitations on the use of his operative shoulder.

## DISCUSSION

We prefer using a semitendinosus graft for coracoclavicular ligament reconstructions for a couple of reasons. The coracoclavicular ligament complex and the semitendinosus graft have similar strength when tested in biomechanical studies.<sup>7,8</sup> Although it is reported in the literature that bicortical screw augmentation provides superior strength and comparable stiff-



**FIGURE 3.** Anteroposterior radiographic view, right shoulder, shows the appearance after reconstruction of the coracoclavicular ligament with a semitendinosus graft for a failed right modified Weaver-Dunn reconstruction (white lines drawn to supplement visualization under acromion and superior/inferior surfaces of distal clavicle).

ness,<sup>9</sup> reconstruction of the coracoclavicular ligament with a semitendinosus graft through bony tunnels attempts to reconstruct the normal anatomy of the coracoclavicular ligament and there is no need for removing hardware with a second operation or concerns for hardware migration.<sup>10</sup> If patients agree to an autologous tendon harvest, one can even eliminate the small risk of a graft rejection.

Morrison and Lemos<sup>11</sup> described a similar technique to reconstruct the coracoclavicular ligament using a Gore-Tex graft (Gore-Tex, Flagstaff, AZ) synthetic loop. Jones et al.<sup>12</sup> described a case where a semitendinosus graft was first looped under the coracoid and then passed through a drill hole in the clavicle to reconstruct the coracoclavicular ligament for a failed Gore-Tex loop augmentation procedure. We believe that by placing the graft through the base of the coracoid, we can increase the reconstructed liga-

ment stiffness, prevent migration of reconstruction material, and obtain secure bone to tendon fixation at both ends of the reconstruction.

Educating patients with failed AC reconstructions before a revision surgery is vital. The chances of a successful surgical result diminish after each failed attempt to correct the original AC problem, and patient noncompliance can be detrimental in terms of future morbidity.<sup>13</sup> Therefore, it is imperative to inform patients that semitendinosus graft transfer is a salvage procedure and, even with total compliance, stretching of the graft could occur, causing a slight superior riding clavicle. Strict compliance with postoperative therapy and appropriate gradual shoulder activities are important for the best cosmetic and functional outcome.

We believe that reconstruction of the coracoclavicular ligaments with a semitendinosus graft through bony tunnels in the clavicle and coracoid is an excellent method to salvage failures of previous AC reconstruction procedures. Our main goal is to ensure that the ligament reconstruction in the distal clavicle and coracoid heal within the bone simultaneously to prevent stress risers. By using a semitendinosus graft through bony tunnels to reconstruct the coracoclavicular ligament, we are providing strong fixation that shows promise in patient outcome, but further studies are needed for the long-term outcomes in this difficult patient population.

## REFERENCES

1. Nordqvist A, Petersson CJ. Incidence and causes of shoulder girdle injuries in an urban population. *J Shoulder Elbow Surg* 1995;4:107-112.
2. Rowe CR, Marble HC. Shoulder girdle injuries. In: Cave EF, ed. *Fractures and other injuries*. Chicago: Year Book, 1958; 250-289.
3. Urist MR. The treatment of dislocations of the acromioclavicular joint: A survey of the last decade. *Am J Surg* 1959;98: 423-431.
4. Weaver JK, Dunn HK. Treatment of acromioclavicular injuries especially complete acromioclavicular separation. *J Bone Joint Surg Am* 1972;54:1187-1194.
5. Rockwood CA, Williams GR, Young DC. Injuries to the acromioclavicular joint. In: Rockwood CA, Green DP, eds. *Fractures in adults*. Philadelphia: Lippincott-Raven, 1996; 1342-1413.
6. Phillips AM, Smart C, Groom AF. Acromioclavicular dislocation: Conservative or surgical therapy. *Clin Orthop Rel Res* 1998;353:10-17.
7. Hamner DL, Brown CH, Steiner ME, et al. Hamstring tendon grafts for reconstruction of the anterior cruciate ligament: Biomechanical evaluation of the use of multiple strands and tensioning techniques. *J Bone Joint Surg Am* 1999;81:549-557.
8. Motamedi AR, Blevins FT, Willis MC, et al. Biomechanics of the coracoclavicular ligament complex and augmentations

- used in its repair and reconstruction. *Am J Sports Med* 2000;28:380-384.
9. Harris RI, Wallace AL, Harper GD, et al. Structural properties of the intact and reconstructed coracoclavicular ligament complex. *Am J Sports Med* 2000;28:103-108.
  10. Lyons FA, CA Rockwood. Migration of pins used in operations on the shoulder. *J Bone Joint Surg Am* 1990;72:1262-1267.
  11. Morrison DS, Lemos MJ. Acromioclavicular separation: Reconstruction using synthetic loop augmentation. *Am J Sports Med* 1995;23:105-110.
  12. Jones HP, Lemos MJ, Schepsis AA. Salvage of failed acromioclavicular joint reconstruction using autogenous semitendinosus tendon from the knee: Surgical technique and case report. *Am J Sports Med* 2001;29:234-237.
  13. Guy DK, Wirth MA, Griffin JL, et al. Reconstruction of chronic and complete dislocations of the acromioclavicular joint. *Clin Orthop Rel Res* 1998;347:138-149.