

Cervical Spine Alignment in the Immobilized Ice Hockey Player

A Computed Tomographic Analysis of the Effects of Helmet Removal*

Robert F. LaPrade,†‡ MD, Kent A. Schnetzler,† MD, Robert J. Broxterman,§ MS, ATC, Fred Wentorf,† MS, Erik Wendland,† and Thomas J. Gilbert,|| MD

From the Departments of †Orthopaedic Surgery and §Men's Intercollegiate Athletics, University of Minnesota, Minneapolis, and ||Center for Diagnostic Imaging, St. Louis Park, Minnesota

ABSTRACT

To determine if helmet removal causes a significant increase in lordosis of the cervical spine in ice hockey players, we radiographically assessed the position of the cervical spine in subjects immobilized to a standard spine backboard wearing shoulder pads both with and without a helmet. Ten adult male volunteers (ages, 18 to 28 years) with no previous history of cervical spine injuries were fitted with an appropriately sized ice hockey helmet and shoulder pads and immobilized in a supine position to a standard spine backboard. Computerized tomographic lateral scout scans were obtained of the cervical spine for three conditions: 1) no equipment (control), 2) helmet and shoulder pads, and 3) shoulder pads only (helmet removed). With the helmet removed and the shoulder pads remaining, a significant increase in C2 to C7 lordosis was found when compared with the other two conditions. Individual segmental measurements revealed a significant increase in cervical lordosis at the C6–7 level with the helmet removed compared with the helmet and shoulder pads condition. Our results demonstrate that the removal of an ice hockey helmet from a supine player causes a significant increase in lordosis (extension) of the cervical spine. We recommend that ice hockey helmets not be removed from injured players, with rare exceptions, because doing so results in unnecessary motion of the cervical spine.

It has been noted over the course of the last 2 decades that the annual incidence of hockey-related spinal injuries in Canada has increased markedly.^{14–16} Before this time, hockey-related cervical spine injuries were rare.¹⁴ The increase in these potentially catastrophic cervical spine injuries is important because of the severe loss of function in the injured player and the huge cost of these injuries over time. Researchers agree that the most common cause of these cervical spine injuries is an illegal check from behind,^{14–16} but the correct method of treatment of a potentially injured player once he is down on the ice has been controversial. The protective helmet and shoulder pads worn by ice hockey players can present special challenges to emergency personnel when immobilizing the injured athlete for transport. In fact, there are different protocols that emergency medical technicians often follow, depending on local protocol, regarding removal of protective equipment. They are sometimes taught that helmets should be carefully removed from persons with head or neck injuries before immobilization and transport.¹¹ In contrast, other recommendations are that the helmet should only be removed in special circumstances, such as to evaluate bleeding.⁸

It has been demonstrated from analysis of immobilized supine football players that a statistically significant increase in cervical lordosis occurs when the helmet is removed compared with continued wearing of the helmet.^{7,9,12} As in football, ice hockey shoulder pads elevate the chest from the playing surface (ice) when a player is lying supine or prone. Therefore, any effect the helmet may have on sagittal cervical alignment must be assessed while also taking into account the presence of the shoulder pads on the athlete.

The purpose of this study was to determine whether removal of an ice hockey helmet from an injured supine

* Presented at the 25th annual meeting of the AOSSM, Traverse City, Michigan, June 1999.

† Address correspondence and reprint requests to Robert F. LaPrade, MD, Sports Medicine and Shoulder Divisions, Department of Orthopaedic Surgery, M/C 492, University of Minnesota, 420 Delaware Street SE, Minneapolis, MN 55455.

No author or related institution has received any financial benefit from research in this study. See "Acknowledgments" for funding information.

player causes a significant increase in lordosis (extension) of the cervical spine. In addition, we wanted to determine which areas of the cervical spine would be most at risk with removal of the ice hockey helmet. Finally, we hoped to assist in the development of a consistent and appropriate on-ice management protocol for handling a hockey player with a suspected cervical spine injury.

MATERIALS AND METHODS

Ten adult male volunteers with an average age of 22.2 years (range, 18 to 28) and no history of cervical spine abnormality were enrolled in the study. All participants signed an informed consent form and the study was approved by the Institutional Review Board Human Subjects Committee (University of Minnesota, Human Subjects Code # 9708M00014).

Each participant served as his own control. Before cervical spine imaging was obtained, each subject was fitted with an appropriate-sized ice hockey helmet (Model HH 3000 M, Cooper, St. Jerome, Quebec, Canada) and a pair of shoulder pads (Douglas Pads, Houston, Texas). The protective equipment provided to the enrollees was of the same type provided to varsity athletes on the University of Minnesota men's ice hockey team. The standard spine backboard used at Mariucci Arena at the University of Minnesota was used to immobilize the participants in a supine position. Straps and lateral foam pads were attached to the backboard to secure the head in the neutral position.

Computerized tomography lateral scout scans of the cervical spine were obtained. The radiographic imaging sequences used were 1) participants wearing no protective equipment (and serving as their own initial control), 2) participants wearing an ice hockey helmet and shoulder pads, and 3) participants wearing only shoulder pads after the helmet was removed (Fig. 1).

The lateral cervical spine CTs were analyzed, and sagittal cervical kyphosis or lordosis was defined as the angle formed by lines projecting parallel to the inferior surface of the vertebral bodies.⁴ Measurements were performed by adjusting the brightness and contrast of the digitized CT images on Adobe Photoshop 5.0 (Adobe Systems, Inc., San Jose, California) until clear and distinct vertebral endplates were visualized at all measured levels. The measurement tool of Adobe Photoshop 5.0 was used to calculate the angle each individual line made to the horizontal plane. The overall angle between individual vertebral endplates was then determined based on the differences between these computer-generated inferior endplate angles. Negative angles indicated cervical kyphosis (flexion) and positive angles indicated cervical lordosis (extension). Both subaxial cervical spine alignment (C2 to C7) and individual cervical spine intersegmental alignments (C2–3, C3–4, C4–5, C5–6, C6–7) were measured. Blinding was not possible between states because of the presence of protective equipment on the CT scans.

A paired *t*-test was used to assess differences in mean values between the three experimental states for overall alignment. A paired *t*-test was also used to assess differ-

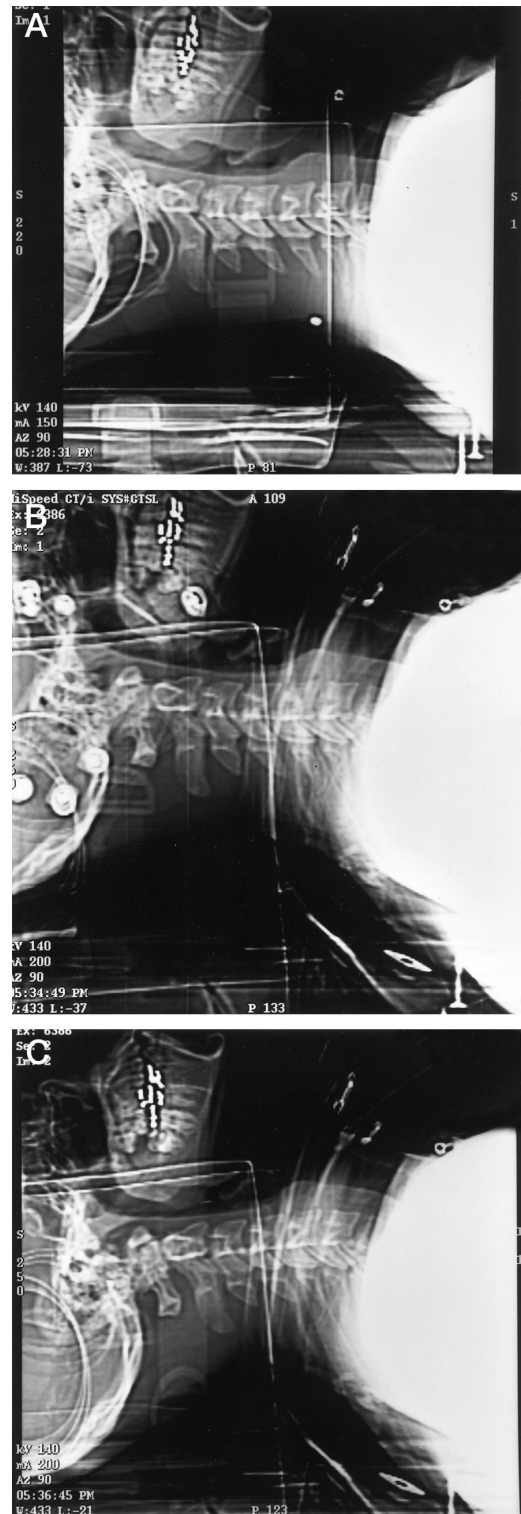


Figure 1. Demonstration of the lateral CT scans of the cervical spine in a 20-year-old man immobilized to a backboard. A, no protective equipment (control). B, wearing an ice hockey helmet and shoulder pads. A minimal change in cervical alignment occurs compared with the control. C, wearing only shoulder pads (helmet removed). An increase of lordosis occurs in overall subaxial cervical spine alignment.

TABLE 1
Changes in Overall Cervical Spine Lordosis

Comparison	Average change (deg)	P Value
Control versus shoulder pads and helmet	4.4	0.03
Control versus shoulder pads only	13.4	0.0002
Shoulder pads and helmet versus shoulder pads only	9.0	0.003

ences in mean values for individual intersegmental alignment between the shoulder pad and helmet condition compared with the shoulder pads only condition. The null hypothesis was that there would be no differences in sagittal cervical spinal alignment between the experimental testing conditions. Statistical significance was set at $P < 0.05$.

RESULTS

A significant increase in lordosis of subaxial cervical spine alignment (C2 to C7) was found when the helmet was removed compared with the helmet and shoulder pads intact ($P < 0.003$) and compared with the control situation ($P < 0.0002$) (Table 1). Individual segmental measurements revealed a significant increase in lordosis at the C6–7 level when the helmet was removed compared with the helmet and shoulder pads intact condition ($P < 0.008$) (Table 2).

DISCUSSION

Over the past 2 decades, much attention has been given to the occurrence of cervical spine injuries in American football.^{1–3, 7, 9, 12, 17–20} However, recent studies have indicated that the occurrence of cervical spine injury (any fracture or dislocation of the spine, with or without a permanent neurologic deficit) per player is three times greater in ice hockey than in American football.¹⁶ Most players and coaches seem unaware of the risk posed to the cervical spine in ice hockey.¹³ The majority of these injuries occur in participants in their late teens or early 20s who are playing in supervised competitions where they sustain an illegal check from behind.¹³ Some researchers believe this increase in injuries may be due to the athletes playing

TABLE 2
Changes in Individual Intersegmental Subaxial Cervical Spine Lordosis Between the Shoulder Pads and Helmet Condition and the Shoulder Pads Only Condition^a

Subaxial spine segment	Average change (deg)	P value
C2–3	2.4	0.07
C3–4	0.0	0.96
C4–5	3.3	0.06
C5–6	-0.3	0.79
C6–7	3.6	0.008

^a Negative values indicate cervical spine kyphosis.

more aggressively with the use of a face mask,¹⁰ but the only study to analyze this link found no increased injury incidence with the use of face masks.⁵

Although the relationship between cervical spine alignment and protective equipment in immobilized players has been studied extensively in football players,^{7, 9, 12} few studies have examined this relationship in ice hockey players.^{6, 9} Our study demonstrates that an ice hockey player with a suspected cervical spine injury should not have his helmet removed, and that the helmet should be left in situ when a player is placed on the standard backboard because removing the helmet significantly increases motion of both the entire subaxial cervical spine (C2 to C7) and the C6–7 level (Fig. 2).

Currently, the worldwide annual incidence of reported cervical spine injuries due to ice hockey injuries is estimated to be 20.3 per year, and approximately 9 per year in the United States (J. Carson, personal communication, 1998). This incidence of 20.3 injuries per year equates to an average of one reported cervical spine injury worldwide per week during the standard ice hockey season. Therefore, it is important that all personnel who provide medical coverage for ice hockey teams or events be well educated in the proper on-ice management of players with a potential cervical spine injury. Although little can be done to reverse the effects of primary neurologic injury, we believe secondary injury can be avoided by proper prehospital management of an athlete with a cervical spine injury by avoidance of unnecessary increased motion of the cervical spine. The initial handling of the athlete until the nature and extent of the possible skeletal and neurologic injury have been defined is essential to the best functional outcome.

Exceptions to our recommendation of not removing the helmet in a ice hockey player with a possible cervical spine injury are limited. The first exception would be when prehospital personnel are unable to remove the face mask



Figure 2. Recommended method of immobilization of an ice hockey player with a potential cervical spine injury. The helmet is left in place, lateral foam pads secure the helmet in position, and straps secure the athlete to the backboard.

or visor to access an airway. Current ice hockey helmets most commonly have face masks that swing away from the face, which should not necessitate removal of the entire helmet to access an airway. The second instance would be when the helmet needs to be removed for a head injury that requires immediate inspection and if there is suspected cranial hemorrhaging. Finally, if the helmet is found to be too loose to permit adequate immobilization, it should be either removed or resecured. In any of these circumstances, we recommend that a cervical collar be applied and that the helmetless head be secured so that an increase in lordosis will not occur. Circumstances that could require helmet removal occur infrequently in ice hockey; therefore, we recommend that ice hockey helmets be left in place, except with rare exceptions, to prevent the significant increase in lordosis of the subaxial cervical spine that this study found occurs when a helmet is removed.

CONCLUSIONS

We recommend that injured ice hockey players with a potential cervical spine injury be immobilized supine with both the ice hockey helmet and shoulder pads left in place until the athlete is transported to a medical facility where he can be clinically and radiographically evaluated for a potential cervical spine injury. All coaching or medical personnel who provide medical coverage for ice hockey teams or events must be educated that this is the proper on-ice management of a player with a potential cervical spine injury.

ACKNOWLEDGMENTS

This study was supported by the Sports Medicine Research Fund at the University of Minnesota. The authors also acknowledge the assistance of Kirkham B. Wood, MD, in the radiographic analysis performed in this study.

REFERENCES

1. Bishop PJ: Factors related to quadriplegia in football and the implications for intervention strategies. *Am J Sports Med* 24: 235-239, 1996
2. Cantu RC, Mueller FO: Catastrophic spine injuries in football (1977-1989). *J Spinal Disord* 3: 227-231, 1990
3. Carter DR, Frankel VH: Biomechanics of hyperextension injuries to the cervical spine in football. *Am J Sports Med* 8: 302-309, 1980
4. Cobb JR: Outline for the study of scoliosis. *Inst Course Lect* 5: 261-275, 1948
5. LaPrade RF, Burnett QM, Zarzour R, et al: The effect of the mandatory use of face masks on facial lacerations and head and neck injuries in ice hockey. A prospective study. *Am J Sports Med* 23: 773-775, 1995
6. Metz CM, Kuhn JE, Greenfield ML: Cervical spine alignment in immobilized hockey players: Radiographic analysis with and without helmets and shoulder pads. *Clin J Sport Med* 8: 92-95, 1998
7. Palumbo MA, Hulstyn MJ, Fadale PD, et al: The effect of protective football equipment on alignment of the injured cervical spine. Radiographic analysis in a cadaveric model. *Am J Sports Med* 24: 446-453, 1996
8. Patel MN, Rund DA: Emergency removal of football helmets. *Physician Sportsmed* 22(9): 57-59, 1994
9. Prinsen RKE, Syrotuik DG, Reid DC: Position of the cervical vertebrae during helmet removal and cervical collar application in football and hockey. *Clin J Sport Med* 5: 155-161, 1995
10. Reynen PD, Clancy WG Jr: Cervical spine injury, hockey helmets, and face masks. *Am J Sports Med* 22: 167-170, 1994
11. Segan RD, Cassidy C, Bentkowski J: A discussion of the issue of football helmet removal in suspected cervical spine injuries. *J Athl Train* 28: 294-305, 1993
12. Swenson TM, Lauerman WC, Blanc RO, et al: Cervical spine alignment in the immobilized football player. Radiographic analysis before and after helmet removal. *Am J Sports Med* 25: 226-230, 1997
13. Tator CH, Carson JD, Edmonds VE: Spinal injuries in ice hockey. *Clin Sports Med* 17: 183-194, 1998
14. Tator CH, Carson JD, Edmonds VE: New spinal injuries in hockey. *Clin J Sport Med* 7: 17-21, 1997
15. Tator CH, Edmonds VE: National survey of spinal injuries in hockey players. *Can Med Assoc J* 130: 875-880, 1984
16. Tator CH, Edmonds VE, Lapczak L, et al: Spinal injuries in ice hockey players, 1966 - 1987. *Can J Surg* 34: 63-69, 1991
17. Torg JS, Sennett B, Vegso JJ, et al: Axial loading injuries to the middle cervical spine segment: An analysis and classification of twenty-five cases. *Am J Sports Med* 19: 6-20, 1991
18. Torg JS, Truex R Jr, Quendenfeld TC, et al: The National Football Head and Neck Injury Registry. Report and conclusions 1978. *JAMA* 241: 1477-1479, 1979
19. Torg JS, Vegso JJ, O'Neill MJ, et al: The epidemiologic, pathologic, biomechanical, and cinematographic analysis of football-induced cervical spine trauma. *Am J Sports Med* 18: 50-57, 1990
20. Torg JS, Vegso JJ, Sennett BJ, et al: The National Football Head and Neck Injury Registry. 14-year report on cervical quadriplegia, 1971 through 1984. *JAMA* 254: 3439-3443, 1985