The American Journal of Sports Medicine
http://ajs.sagepub.com/

"At-Risk" Positioning and Hip Biomechanics of the Peewee Ice Hockey Sprint Start

Justin D. Stull, Marc J. Philippon and Robert F. LaPrade

Am J Sports Med 2011 39: 29S
DOI: 10.1177/0363546511414012

The online version of this article can be found at:
http://ajs.sagepub.com/content/39/1_suppl/29S

Published by:
SAGE
http://www.sagepublications.com

On behalf of:
AOSSM
American Orthopaedic Society for Sports Medicine

‘‘At-Risk’’ Positioning and Hip Biomechanics of the Peewee Ice Hockey Sprint Start

Justin D. Stull,*† BA, Marc J. Philippon,† MD, and Robert F. LaPrade,† MD, PhD
Investigation performed at the Steadman Philippon Research Institute, Vail, Colorado

Background: Femoroacetabular impingement (FAI) is becoming a prevalent overuse injury diagnosis among hockey players. In the adult ice hockey stride, the ‘‘at-risk’’ hip position, defined by internal rotation during flexion and external rotation during abduction, reportedly increases hip vulnerability to labral injury as a result of FAI.

Hypothesis: Peewee youth ice hockey players display the kinematics for both described at-risk hip positions (internal rotation during flexion and external rotation during abduction) in the ice hockey sprint start.

Study Design: Descriptive laboratory study.

Methods: Twelve healthy male Peewee ice hockey players (mean age, 10.8 ± 0.6 years) participated in this study. Thirty-five anatomic landmarks were used to analyze the 3-dimensional kinematic and kinetic variables of the hip associated with the ice hockey sprint start. Ten high-speed (120-Hz) infrared cameras recorded the trials, which were subsequently analyzed with Motion Monitor software. The sprint start was recorded over 4 defined periods of motion: start, push, swing, and even.

Results: In the ‘‘push’’ period, 11.5° of external rotation was observed concurrently with 13.2° of abduction in the push leg, and 6.8° of internal rotation occurred with 33.8° of flexion in the lead leg. During the recovery phase of the ‘‘swing’’ period, maximum internal rotation was 5.6° with concurrent hip flexion of 44.2° in the push leg, while lead leg internal rotation reached a maximum of 10.8° with hip flexion of 35.1° during the ‘‘even’’ period.

Conclusion: During the sprint start, youth ice hockey players externally rotate in abduction during the push-off phase and internally rotate through increasing hip flexion during the recovery phase, displaying the at-risk hip positions of the ice hockey skating stride.

Clinical Relevance: During the sprint start, youth ice hockey players position their hips in a manner that can cause impingement of the femoral neck against the acetabulum and potentially lead to labral tears and/or articular cartilage damage. This knowledge could be applied to assist in the prevention of overuse injuries of the hip as youth hockey players mature and increase in skill level.

Keywords: hip; biomechanics; ‘‘at risk’’; femoroacetabular impingement (FAI); youth; hockey; labrum; skating

Among ice hockey players, the hip and groin region is one of the most commonly reported areas of overuse or noncontact injuries.[1,2,4,6,10,17,20] The mechanism for these injuries has been described in limited detail and without special attention to youth.[2,12,17] While contact injuries have been reported to be more prevalent than overuse injuries in youth ice hockey, it has also been reported that overuse injuries are becoming a more common occurrence within the youth athletic population.[3,19,22,26]

One overuse injury of the hip receiving increased attention is femoroacetabular impingement (FAI). In the past, many cases of FAI had reportedly been misdiagnosed as potential groin or abdominal strains,[11] but more recently FAI has become a commonly reported injury among elite athletes, especially hockey players.[2,11,14] Femoroacetabular impingement occurs when a bony abnormality on the femur (cam type) and/or the acetabulum (pincer type) entraps and increases pressure on the acetabular labrum during movement, potentially leading to labral tears and/or articular cartilage damage.[7] Femoroacetabular impingement is not only painful, but it can also limit athletic function, and lead to decreased hip range of motion.[11,15,16]

Two “at-risk” positions have been identified that increase the likelihood of acetabular labral impingement by the femoral neck during ice hockey skating. The characteristic abduction and external rotation positioning of the hip during the push-off phase (Figure 1A) represents 1 at-risk position; the second at-risk position (Figures 1B and 1C) is defined by flexion and internal rotation at the culmination of the recovery phase of the hockey stride.[2,8,12,17] There has also been a reported association between increased speed and the risk of nonimpact injury to the musculature surrounding the hip, specifically increasing the risk for a groin strain, reportedly a common misdiagnosis of FAI.[5,11] However, there has been no study to date, to our knowledge, analyzing the sprint

*Address correspondence to Justin D. Stull, 181 W. Meadow Dr, Suite 1000, Vail, CO 81657 (e-mail: justin.stull@sprivail.org).
†Steadman Philippon Research Institute, Vail, Colorado.
The authors declared that they have no conflicts of interest in the authorship or publication of this contribution.

The American Journal of Sports Medicine, Vol. 39, Supplement 1
DOI: 10.1177/0363546511414012



Figure 1. Photographic presentation of at-risk hip positions during the ice hockey sprint start. A, abduction and external rotation during the right leg push-off phase. B, right leg recovery phase with internal rotation during flexion. C, left leg recovery phase (arrows designate hip at risk). At-risk hip positions, defined by external rotation during abduction and internal rotation during flexion, are both demonstrated by Peewee ice hockey players during the ice hockey sprint start.

start of players at specific earlier stages of physical development to identify potential at-risk positions of the femoral head and neck associated with FAI in a younger cohort.

While there has been a reported association between genetics and the development of FAI, it has also been speculated that FAI onset could occur as a result of overuse and recurrent contact (microtrauma) between the femoral epiphysis and the acetabulum from repetitive motion.[7,18] Thus, the injury mechanism of FAI in hockey appears to be, at least in part, a product of the style of play, amount of on-ice exposure, and the biomechanics of skating, potentially including on-ice participation beginning at a young age. Youth ice hockey participation is growing,[9,25] and the prevalence of overuse injuries has been reported to increase with the level of play among youth athletics.[3,9,21,25] Therefore, it is important to investigate the ice skating biomechanics that could lead to future hip injuries as a player ages and increases in skill level in an effort to determine if possible interventions to decrease the sequelae of FAI injury are possible.

As FAI becomes a more common diagnosis among young ice hockey players, it is important that the kinematics of youth ice hockey skating are evaluated as the first step in identifying and potentially reducing the prevalence of future overuse injuries, including FAI, as a result of at-risk hip positioning. The purpose of this study was to identify the biomechanics of the sprint start in youth ice hockey players and evaluate the youth ice hockey sprint form with special attention toward the identified at-risk kinematics of ice hockey skating. Our hypothesis was that Peewee ice hockey players would display at-risk hip positioning during the sprint start of the ice hockey skating stride.

METHODS

Data Collection

Twelve uninjured, healthy male ice hockey players (mean age, 10.8 ± 0.6 years; mean height, 150.2 ± 6.5 cm; mean body mass, 37.6 ± 4.0 kg) with no history of neurologic, orthopaedic, or cardiovascular disease participated in a kinematic analysis of their ice hockey sprint start. All of the participants were Peewee ice hockey players and by USA Hockey definition were between the ages of 10 and 13 years.[25] Testing protocols were approved by the Steadman Philippon Research Institute and before participation, each athlete and his legal guardian provided written informed consent.

Figure 2. Photograph of anterior anatomic locations of reflective markers for recording 3-dimensional kinematics of the ice hockey sprint stride. Reflective markers were placed at anatomic locations with special attention to the hip and lower body. Kinematics and 3-dimensional Euler angles were derived from software analysis of infrared camera recordings of the markers through the sprint start.

The players were tested on a 6.4-mm–thick acrylic surface manufactured specifically for ice hockey skate testing (Viking Ice, Wilsonville, Oregon) that was subsequently sprayed with a silicon-based spray (Electric Slide, Zep, Atlanta, Georgia) to emulate melting ice and to further lower skate blade–acrylic friction. Each player wore his own skates and was given ample time to become accustomed to the testing surface before testing.

Three-dimensional kinematics for each trial were recorded through Motion Analysis EVaRT (Motion Analysis, Santa Rosa, California), using 10 high-speed (120-Hz) cameras that employ infrared technology to illuminate 35 retroreflective spherical markers attached to the upper and lower extremities of the body during the skating stride (Figure 2). Participants in the study executed 3 sprint strides beginning at rest with no crossover step, and completed 10 sprint starts in total.

Data Analysis

Trials were digitized and all marker trajectories were filtered in Motion Analysis EVaRT software using

TABLE 1
Description of the Hockey Stride Time-Point Identifiers of the Sprint Stride[a]

	Start	2	3	4	Even
Push leg (right leg)	Player in ready position; first movement	Final position of the leg before beginning initial push-off phase	Blade of skate ends contact with ice, terminating push-off phase and beginning recovery phase	Entire blade of skate comes into contact with ice; beginning push-off phase	Entire blade of skate is in contact with ice, in midcycle of push-off phase; heels are even with heel of lead leg in sagittal plane
Lead leg (left leg)	Player in ready position; first movement	Toe leaves ice, initiating the first recovery phase, and reaches in stride	Entire blade of skate comes into contact with ice; beginning push-off phase	Blade of skate ends contact with ice, terminating push-off phase and beginning recovery phase	Skate is off of ice, in midcycle of recovery phase; heels are even with push leg in sagittal plane

[a]The 5 described time points were used to evaluate the sprint start and served as the beginning and termination points for the 4 periods of the sprint start.



Figure 3. Photographic progression of the neutral position and sprint period time points during the ice hockey sprint start: A, neutral position; B, beginning of start period; C, beginning of push period; D, beginning of swing period; E, beginning of even period; F, end of sprint start. At-risk hip positioning was observed during the push, swing, and even periods of the Peewee ice hockey sprint start.

a fourth-order Butterworth 10-Hz smoothing parameter. Using Motion Monitor software (Innovative Sport Technology, Chicago, Illinois), 3-dimensional Euler angles were calculated for flexion, abduction, and rotation of the hip for both limbs at specific positions of the sprint start.

Five specific points of the ice hockey sprint start were identified that defined the first and last moments of 4 distinct periods of the skate stride. The periods were used to describe the segmented movements for both legs, the push leg and the lead leg. The push leg was the leg observed to provide the forward momentum in the first stride of the ice hockey sprint through a planted pushoff, and for consistency the right leg for each player was observed. The lead leg was the leg that reached forward, taking a step in the first stride of the ice hockey sprint, and for consistency through the group, in each observed player the lead leg was the left leg. The first point marked the beginning of the start period and was identified by the first movement of the lower body initiating forward skating (Figure 3B). The second point occurred with the push leg planted and the stride foot leaving the ice, marking the beginning of the push period (Figure 3C). The swing period began with the third time point, which was marked by the push foot leaving the ice and concurrently swinging to its maximum forward position (Figure 3D). The fourth point was marked by the lead leg leaving the ice, defining the beginning of the "even" period (Figure 3E). The end point of the even period as well as the total observed sprint start occurred when the heels of the skater were even in the sagittal plane of observation (Figure 3F and Table 1).

The 4 defined periods comprised the entirety of the ice hockey sprint start—the start period, which was defined by the first observable movement of forward skating; the push period, with the push foot down and the lead leg flexing forward in stride; the swing period, with the lead foot down and the push leg swinging from extension forward to complete a stride; and the even period, with the push foot down and the heel of the lead leg coming into an even position in the sagittal plane.

In addition, 2 phases were identified for each leg during the hockey stride. The push-off phase was defined by leg positioning on the ice, extending behind the framework of the body, propelling the skater forward. The recovery phase was defined from the point in time when the leg left the ice,

swung forward, and reached for the next step, until the skate landed on the ice again. For each individual leg, the 2 phases cycled throughout the skating motion.

Determination of hip angles and rotation were measured by the anatomic markers of the trunk, hip, and thigh using Motion Monitor analysis from an initial static trial for each individual. The participant was asked to stand normally in his skates and remain as still as possible (Figure 3A). The hip angles from this trial were averaged and the average was assigned a hip angle of 0° for all planes under observation during the recorded sprints. All subsequent trials of that participant were measured from these "zero-degree" angles. The thigh motion was measured for 3 different planes: flexion (+) and extension (−) in the sagittal plane, abduction (+) and adduction (−) in the coronal plane, and internal (+) and external rotation (−) in the transverse axial plane.

RESULTS

The start period began at the first observable movement of forward skating, and was exemplified by slight external rotation in both legs as the skater prepared for pushoff, 4.5° in the lead leg and 3.0° in the push leg, displayed in the change of lower body positioning between Figures 3B and 3C. Increasing abduction was also identified in the push leg during the start period as the player began the pushoff. The push period was characterized by a peak internal rotation (6.8°) and flexion (36.6°) in the lead leg and external rotation (11.5°) in the push leg; this positioning is shown in Figure 1C and displayed graphically in Figure 4. Additionally, as the push leg extension increased, approaching a peak, abduction reached the maximum observed value for either leg (push or lead) over the entirety of the recorded sprint start (21.9°) (Figure 1A). In both legs during the swing period, rapid changes were observed in all aspects of hip joint movement. This was the first defined time period beginning with both legs in midcycle of the forward skating motion, and several average maximum values were recorded for the period of sprint start under observation. Push leg flexion in the recovery phase (45.8°), push leg internal rotation in the recovery phase (5.6°) (Figure 1B), and lead leg external rotation in the push-off phase (7.7°) all experienced maximum values during the swing period. The greatest rates of change for flexion (2.7°/percent skate stride over 14% of the sprint stride) and internal rotation (1.1°/percent skate stride for 6% of the skate stride) during the observed sprint start were recorded during the even period in the lead leg (Figure 4).

Flexion was noted prominently during the recovery phase as the leg was driven forward, taking a new step, with an average maximum hip flexion of 48.3° ± 14.4°. Extension was observed during the push-off phase, with the leg extending behind the body to a mean peak hip extension of 11.8° ± 15.8°. The average total range of motion arc for flexion/extension was 60.1° ± 12.3°. Adduction, which was only observed in 9 of the 12 players, was displayed when the leg medially crossed its anatomically neutral positioning during the recovery phase and averaged a maximum

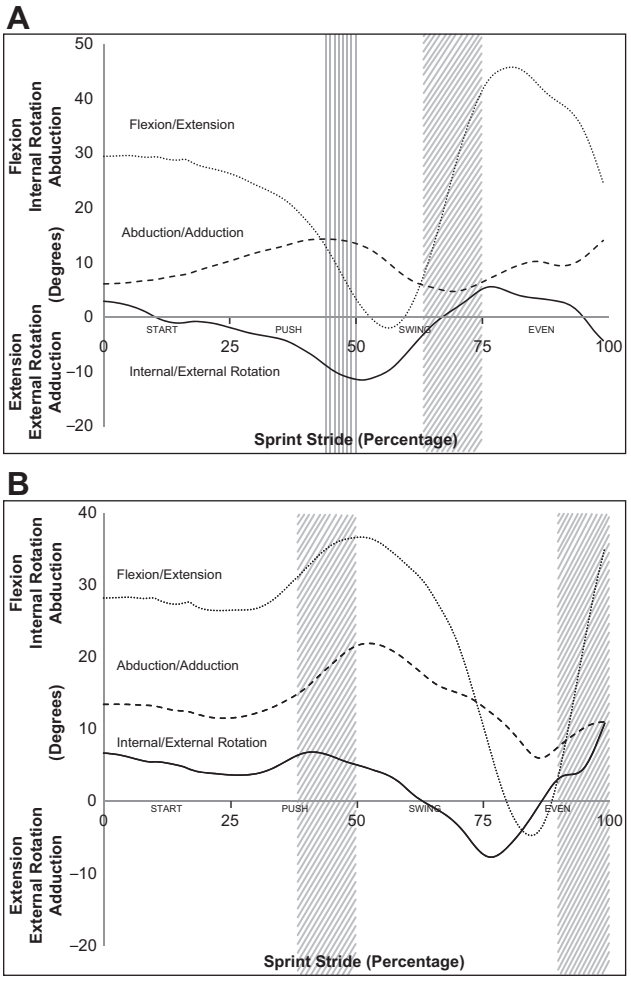

Figure 4. Peewee hip kinematics of the ice hockey sprint start: A, push (right) leg; B, lead (left) leg. Average values are reported for flexion, extension, abduction, adduction, internal rotation, and external rotation. At-risk positioning, consisting of internal rotation and flexion, were observed in every recovery phase of the Peewee ice hockey sprint start. Legend: ····· flexion/extension; – – – – – adduction/abduction; ——— internal/external rotation; diagonal lines, recovery phase at-risk position; vertical lines, push-off phase at-risk position.

value of 0.4° ± 7.6°. Abduction accompanied the leg extending laterally outward during pushoff with a mean maximum of 23.0° ± 9.5°. The abduction/adduction average range of motion arc was 23.3° ± 9.7°. Internal and external rotation were observed by leg rotation internally during the recovery phase to an average maximum of 16.3° ± 14.8° (internal rotation) and externally during the push-off phase to an average maximum of 16.8° ±11.7° (external rotation). The average total range of motion arc for internal/external rotation was 33.2° ± 14.0° (Table 2).

During the recovery phase of the sprint start, maximum internal rotation for each hip occurred concurrently with the ipsilateral hip approaching maximum flexion (lead leg: 6.8° internal rotation with 33.8° flexion [push period]

TABLE 2
Group Averages and Individual Maximum and Minimum Observed Values of Hip Motion During the Peewee Ice Hockey Sprint Start (N = 12)[a]

	Individual Maximum	Individual Minimum	Group Mean ± SD
Peak hip flexion, deg	85.4	15.5	48.3 ± 14.4
Peak hip extension, deg	63.8	−25.9	11.8 ± 15.8
Flexion/extension total arc of motion, deg	126.6	35.6	60.1 ± 12.3
Peak internal rotation, deg	70.8	−24.4	16.3 ± 14.8
Peak external rotation, deg	76.2	−23.0	16.8 ± 11.7
Internal/external rotation total arc of motion, deg	81.8	9.9	33.2 ± 14.0
Peak adduction, deg	39.9	−27.0	0.4 ± 7.6
Peak abduction, deg	48.1	6.4	23.0 ± 9.5
Adduction/abduction total arc of motion, deg	63.1	9.6	23.3 ± 9.7

[a]The total arc of motion from full extension to full flexion, full internal rotation to full external rotation, and full abduction to full adduction degree values are also reported for individual maximum, minimum, and group averages. SD, standard deviation.

and 10.8° internal rotation with 35.1° of flexion [even period]; push leg: 5.6° internal rotation with 44.2° of flexion [swing period]) (Table 3). Maximum external rotation and decreasing abduction were observed as extension neared its maximum during the push-off phase of the sprint start (11.5° of external rotation with 13.8° of extension) (Table 4).

DISCUSSION

The results of our study confirmed our hypothesis and indicated that Peewee youth ice hockey players display at-risk hip mechanics (defined by internal rotation during flexion and external rotation during abduction) during the initial push-off and each of the recovery phases of the ice hockey sprint start. Previously unidentified in youth, these kinematics mimic the identified at-risk positions in adults and could lead to labral injuries in the event of repetitive contact between the femoral head-neck junction with an abnormal femoral neck offset and the chondrolabral junction as a player matures. If cam FAI has asymptomatically developed in a youth ice hockey player, an increase in strength and speed associated with physical maturity creating greater hip forces and rates of rotation in the sprint start recovery phase could be the catalyst for acetabular labral injury. If cam FAI formation occurs later in an ice hockey player's development, our study indicates that a biomechanical predisposition has already been learned, increasing the risk for a future injury.

While femoral head-neck abutment with the acetabular labrum during skating has not been explicitly described in literature to our knowledge, it has been described preoperatively for FAI resection with regard to internal rotation in 90° of flexion. Preoperative hip internal rotation in 90° of hip flexion has been observed to be 4° ± 5°,[13] 10° ± 6.0°,[23] and having a range from 0° to 15°.[27] We observed averages for peak hip internal rotation of 6.8°, 5.6°, and 10.8° during maximum corresponding hip flexion of 33.0°, 44.2°, and 35.1°, respectively. The corresponding angles of internal rotation are based on smaller angles of hip flexion but are toward the higher limits of observed internal rotation angles in preoperative surgical studies of FAI, and therefore still raise concerns that the Peewee sprint start mechanics may lead to acetabular labral and/or articular cartilage injury if continued as a hockey player develops.

The at-risk position was observed in both phases of the Peewee ice hockey sprint start. During the push-off phase, abduction and external rotation were observed concurrently while flexion and internal rotation were observed concurrently during the recovery phase. At the termination of the push-off phase, as the skate left the ice, the hip was in abduction, external rotation, and the least amount of flexion for the sprint start, displaying 1 type of at-risk positioning. The youth ice hockey skater's flexed knee was then driven forward in the recovery phase. As the leg returned toward the coronal and sagittal anatomic midlines through adduction and flexion accompanied by internal rotation during the recovery phases of the sprint start, the players demonstrated the second at-risk position to labral impingement that has been previously described.[2,8,17] The maximum internal rotation observed was accompanied by peaks in hip flexion during the recovery phases of the sprint start. This position was noticed in alternating legs (lead, push, lead) during 3 of the 4 observed periods of the recorded movement; only the start period was without at-risk positioning. As the sprint stride progressed, the positioning of the hip increased the potential vulnerability of the joint based upon an increase in flexion and a greater rate of change with respect to internal rotation.

As players progressed through their sprint stride, the overall trend was an increase in the rate (speed) and total amount of rotation (range of motion) with respect to flexion/extension and internal/external rotation. The increased external rotation and abduction in the push-off phase was most pronounced during the first pushoff, while the increased internal rotation in the recovery phase became more exaggerated as the sprint stride progressed. As speed increased, so too did the extent of the at-risk position of the hip. Because speed has been reported to be related to increased groin strains, which have been a reported misdiagnosis of FAI in the past,[5,11] and speed is also associated with a greater rate and degree of rotation, we believe that as speed increases, the risk of possible labral impingement associated with the at-risk positioning in the ice hockey

TABLE 3
Maximum Internal Rotation Over Consecutive Periods of the Skate Stride With Corresponding Skate Phase in the Ice Hockey Sprint Start (N = 12)[a]

	Leg		
	Lead (Left)	Push (Right)	Lead (Left)
Maximum internal rotation, deg	6.8	5.6	10.8
Corresponding flexion, deg	33.8	44.2	35.1
Corresponding skate period (phase)	Push (recovery)	Swing (recovery)	Even (recovery)

[a]Internal rotation in flexion has been described as at-risk positioning for the acetabular labrum; these values demonstrate the maximum at-risk positions observed during the sprint start of Peewee hockey players in alternating legs over consecutive sprint periods.

TABLE 4
Maximum External Rotation Over Consecutive Periods of the Skate Stride With Corresponding Skate Phase in the Ice Hockey Sprint Start (N = 12)[a]

	Leg	
	Push (Right)	Lead (Left)
Maximum external rotation, deg	11.5	7.8
Corresponding abduction, deg	13.2	12.0
Corresponding skate period (phase)	Push (push-off)	Swing (push-off)

[a]External rotation in abduction has been identified as an at-risk position during the skating stride. Peewee ice hockey players display this positioning during the push period of the sprint start.

sprint stride also increases. The greatest rate of internal rotation and flexion was observed during the recovery phase of the lead leg over the last portion of the sprint stride (even period), when the players were reaching top speed. While it has been reported that the musculature of the hip is more vulnerable to injury as speed increases, it appears that the integrity of the acetabular labrum could also be in jeopardy of injury with increased speed in the presence of FAI as the sprint progresses based on the observed skating mechanics of this study.

Each period of the sprint start was characterized by slightly different risks to acetabular labral impingement. The start period of the sprint began at the first observable movement toward skating and showed little risk for injury to the hip, as skaters demonstrated slight external rotation. Slight abduction was also identified during the latter part of the start phase as the player began to push off but before the lead foot was lifted off of the ground. The push period was characterized by a peak in internal rotation and flexion in the lead leg and a high degree of abduction accompanied by external rotation in the push leg, both described as at-risk positions.[2,8,17] During the swing period, rapid changes were observed in all aspects of hip joint movement in both legs. This was the first observed period, beginning with both legs in midcycle of the forward skating motion, and several maximum values were recorded for the period of observation (push leg flexion, push leg internal rotation, and lead leg external rotation all experienced maximum values). The greatest rates of change for flexion and internal rotation during the observed skate stride were recorded during the even period in the lead leg, even though the period only represented one-half of a full leg stride. The last 3 observed periods of the sprint start all displayed significant elements of the sprint mechanics labeled as at-risk positioning.

In a kinematic study of the adult skating stride, higher-level skaters were shown to have greater angles of flexion and lesser angles of abduction and external rotation during their stride.[24] The adults were reported to have similar angles of flexion in the recovery phase of the hockey stride and similar angles of abduction and external rotation during the push-off phase. However, these observations must be interpreted cautiously; the data collected in our study were analyzed for peak angles of internal and external rotation during maximum flexion and abduction, respectively, which occur at slightly different points in the skating stride than observations reported in the adult study. Because of differences in data analysis, it is incommensurable to make a direct comparison between studies.

In an effort to prevent future hip injuries from occurring as players develop physically and skill-wise, coaches and trainers should consider avoiding excessive developmental skating drills. These drills include but are not limited to power skating, which emphasizes the full ranges of hip motion while building powerful skating strides, often through the use of resistance bands. These drills often promote extreme at-risk positions with exaggerated flexion and internal rotation in the recovery phase and exaggerated abduction and external rotation in the push-off phase. Ideal strides for the youth hockey player should be the goal, but avoiding hip overuse and the potential development of hip pathologic abnormalities from repeated abutment of the femoral neck and potential cam lesion at the chondrolabral junction should be more closely monitored as a primary step toward prevention of hip overuse injuries in ice hockey.

We acknowledge there were limitations to this study. Players were observed on a synthetic surface meant to mimic ice rather than on a real ice surface. However, the synthetic ice and silicon spray were specifically designed for use in combination to closely mimic a true ice surface after resurfacing. In addition, only 1 age group was tested in this study. However, this age group represented an average prepubital age for which contact checking begins and increased on-ice activities commence. The observed group regularly participated in the full range of ice hockey activities without a great deal of prior exposure to on-ice playing time or an increase in body mass, which have been associated with overuse injuries. Lastly, only asymptomatic volunteers were used as participants in this study without knowledge of any preexisting FAI symptoms potentially affecting the individual.

CONCLUSION

In summary, this study has identified the hip kinematics during the ice hockey sprint start in youth players. As Pee-wee hockey players performed a sprint start, their hips experienced at-risk positions that place the femoral neck in a position that may impinge on the acetabular labrum and articular cartilage in the presence of cam FAI. These findings should be taken into consideration when coaches and trainers are dealing with youth ice hockey players experiencing hip pain and precautions should be evaluated to potentially decrease repetitive at-risk positioning in youth ice hockey skating.

REFERENCES

1. Agel J, Dompier TP, Dick R, Marshall SW. Descriptive epidemiology of collegiate men's ice hockey injuries: National Collegiate Athletic Association Injury Surveillance System, 1988-1989 through 2003-2004. *J Athl Train*. 2007;42(2):241-248.
2. Bizzini M, Notzli HP, Maffiuletti NA. Femoroacetabular impingement in professional ice hockey players: a case series of 5 athletes after open surgical decompression of the hip. *Am J Sports Med*. 2007;35(11):1955-1959.
3. Brenner JS. Overuse injuries, overtraining, and burnout in child and adolescent athletes. *Pediatrics*. 2007;119(6):1242-1245.
4. Brown RA, Mascia A, Kinnear DG, Lacroix V, Feldman L, Mulder DS. An 18-year review of sports groin injuries in the elite hockey player: clinical presentation, new diagnostic imaging, treatment, and results. *Clin J Sport Med*. 2008;18(3):221-226.
5. Chang R, Turcotte R, Pearsall D. Hip adductor muscle function in forward skating. *Sports Biomech*. 2009;8(3):212-222.
6. Emery CA, Meeuwisse WH, Powell JW. Groin and abdominal strain injuries in the National Hockey League. *Clin J Sport Med*. 1999;9(3):151-156.
7. Ganz R, Parvizi J, Beck M, Leunig M, Notzli H, Siebenrock KA. Femoroacetabular impingement: a cause for osteoarthritis of the hip. *Clin Orthop Relat Res*. 2003;417:112-120.
8. Garrett WE, Kirkendall DT. *Exercise and Sport Science*. Philadelphia, PA: Lippincott Williams & Wilkins; 2000.
9. Hockey Canada Player Registration. Available at http://www.hockeycanada.ca/index.php/ci_id/23952/la_id/1.htm. Accessed May 27, 2011.
10. Irshad K, Feldman LS, Lavoie C, Lacroix VJ, Mulder DS, Brown RA. Operative management of ''hockey groin syndrome'': 12 years of experience in National Hockey League players. *Surgery*. 2001;130(4):759-764; discussion 764-766.
11. Keogh MJ, Batt ME. A review of femoroacetabular impingement in athletes. *Sports Med*. 2008;38(10):863-878.
12. Lavigne M, Parvizi J, Beck M, Siebenrock KA, Ganz R, Leunig M. Anterior femoroacetabular impingement, part I: techniques of joint preserving surgery. *Clin Orthop Relat Res*. 2004;418:61-66.
13. Notzli HP, Wyss TF, Stoecklin CH, Schmid MR, Treiber K, Hodler J. The contour of the femoral head-neck junction as a predictor for the risk of anterior impingement. *J Bone Joint Surg Br*. 2002;84(4):556-560.
14. Philippon M, Schenker M, Briggs K, Kuppersmith D. Femoroacetabular impingement in 45 professional athletes: associated pathologies and return to sport following arthroscopic decompression. *Knee Surg Sports Traumatol Arthrosc*. 2007;15(7):908-914.
15. Philippon MJ, Maxwell RB, Johnston TL, Schenker M, Briggs KK. Clinical presentation of femoroacetabular impingement. *Knee Surg Sports Traumatol Arthrosc*. 2007;15(8):1041-1047.
16. Philippon MJ, Schenker ML. Arthroscopy for the treatment of femoroacetabular impingement in the athlete. *Clin Sports Med*. 2006;25(2):299-308, ix.
17. Philippon MJ, Weiss DR, Kuppersmith DA, Briggs KK, Hay CJ. Arthroscopic labral repair and treatment of femoroacetabular impingement in professional hockey players. *Am J Sports Med*. 2010;38(1):99-104.
18. Pollard TC, Villar RN, Norton MR, et al. Genetic influences in the aetiology of femoroacetabular impingement: a sibling study. *J Bone Joint Surg Br*. 2010;92(2):209-216.
19. Shindle MK, Marx RG, Kelly BT, Bisson L, Burke CJ 3rd. Hockey injuries: a pediatric sport update. *Curr Opin Pediatr*. 2010;22(1):54-60.
20. Sim FH, Simonet WT, Melton LJ 3rd, Lehn TA. Ice hockey injuries. *Am J Sports Med*. 1987;15(1):30-40.
21. Smith AM, Stuart MJ, Wiese-Bjornstal DM, Gunnon C. Predictors of injury in ice hockey players: a multivariate, multidisciplinary approach. *Am J Sports Med*. 1997;25(4):500-507.
22. Stuart MJ, Smith AM, Nieva JJ, Rock MG. Injuries in youth ice hockey: a pilot surveillance strategy. *Mayo Clin Proc*. 1995;70(4):350-356.
23. Tannast M, Kubiak-Langer M, Langlotz F, Puls M, Murphy SB, Siebenrock KA. Noninvasive three-dimensional assessment of femoroacetabular impingement. *J Orthop Res*. 2007;25(1):122-131.
24. Upjohn T, Turcotte R, Pearsall DJ, Loh J. Three-dimensional kinematics of the lower limbs during forward ice hockey skating. *Sports Biomech*. 2008;7(2):206-221.
25. USA Hockey. Membership Statistics. Available at http://www.usahockey.com//Template_Usahockey.aspx?NAV=ME_03&ID=29074. Accessed July 29, 2010.
26. Willer B, Kroetsch B, Darling S, Hutson A, Leddy J. Injury rates in house league, select, and representative youth ice hockey. *Med Sci Sports Exerc*. 2005;37(10):1658-1663.
27. Zebala LP, Schoenecker PL, Clohisy JC. Anterior femoroacetabular impingement: a diverse disease with evolving treatment options. *Iowa Orthop J*. 2007;27:71-81.