

The American Journal of Sports Medicine

<http://ajs.sagepub.com/>

Arthroscopically Pertinent Landmarks for Tunnel Positioning in Single-Bundle and Double-Bundle Anterior Cruciate Ligament Reconstructions

Connor G. Ziegler, Sean D. Pietrini, Benjamin D. Westerhaus, Colin J. Anderson, Coen A. Wijdicks, Steinar Johansen, Lars Engebretsen and Robert F. LaPrade

Am J Sports Med 2011 39: 743 originally published online December 20, 2010

DOI: 10.1177/0363546510387511

The online version of this article can be found at:

<http://ajs.sagepub.com/content/39/4/743>

Published by:



<http://www.sagepublications.com>

On behalf of:



[American Orthopaedic Society for Sports Medicine](#)

Additional services and information for *The American Journal of Sports Medicine* can be found at:

Email Alerts: <http://ajs.sagepub.com/cgi/alerts>

Subscriptions: <http://ajs.sagepub.com/subscriptions>

Reprints: <http://www.sagepub.com/journalsReprints.nav>

Permissions: <http://www.sagepub.com/journalsPermissions.nav>

>> [Version of Record](#) - Apr 1, 2011

[OnlineFirst Version of Record](#) - Dec 20, 2010

[What is This?](#)

Arthroscopically Pertinent Landmarks for Tunnel Positioning in Single-Bundle and Double-Bundle Anterior Cruciate Ligament Reconstructions

Connor G. Ziegler,^{*} BA, Sean D. Pietrini,^{*} BS, Benjamin D. Westerhaus,^{*} Colin J. Anderson,^{*} BA, Coen A. Wijdicks,[†] PhD, Steinar Johansen,[‡] MD, Lars Engebretsen,[‡] MD, PhD, and Robert F. LaPrade,^{†§} MD, PhD
Investigation performed at the University of Minnesota, Minneapolis, Minnesota

Background: Quantification of the overall anterior cruciate ligament (ACL) and anteromedial (AM) and posterolateral (PL) bundle centers in respect to arthroscopically pertinent bony and soft tissue landmarks has not been thoroughly assessed.

Hypothesis: A standardized anatomical measurement method can quantitate the locations of the ACL and AM and PL bundle centers in reference to each other and anatomical landmarks.

Study Design: Descriptive laboratory study.

Methods: Quantification of the ACL and its bundle attachments was performed on 11 cadaveric knees using a radiofrequency-tracking device.

Results: The tibial ACL attachment center was 7.5 mm medial to the anterior horn of the lateral meniscus, 13.0 mm anterior to the retro-eminence ridge, and 10.5 mm posterior to the ACL ridge. The femoral ACL attachment center was 1.7 mm proximal to the bifurcate ridge and 6.1 mm posterior to the lateral intercondylar ridge. The tibial AM attachment center was 8.3 mm medial to the anteromedial aspect of the lateral meniscus anterior horn, 17.8 mm anterior to the retro-eminence ridge, and 5.6 mm posterior to the ACL ridge. The femoral AM attachment center was 4.8 mm proximal to the bifurcate ridge and 7.1 mm posterior to the lateral intercondylar ridge. The tibial PL bundle attachment center was 6.6 mm medial to the posteromedial aspect of the lateral meniscus anterior horn, 10.8 mm anteromedial to the root attachment of the lateral meniscus posterior horn, and 8.4 mm anterior to the retro-eminence ridge. The femoral PL bundle attachment center was 5.2 mm distal to the bifurcate ridge and 3.6 mm posterior to the lateral intercondylar ridge.

Conclusion: The authors developed a comprehensive compilation of measurements of arthroscopically pertinent bony and soft tissue landmarks that quantitate the ACL and its individual bundle attachment centers on the tibia and femur.

Clinical Relevance: These clinically relevant arthroscopic landmarks may enhance single- and double-bundle ACL reconstructions through improved tunnel placement.

Keywords: arthroscopic landmarks; double-bundle anterior cruciate ligament reconstruction; single-bundle anterior cruciate ligament reconstruction; anteromedial anterior cruciate ligament bundle; posterolateral anterior cruciate ligament bundle

[§]Address correspondence to Robert F. LaPrade, MD, PhD, Director, Biomechanics Department, Steadman Philippon Research Institute, The Steadman Clinic, 181 West Meadow Drive, Suite 400, Vail, CO 81657 (e-mail: drlaprade@sprivail.org).

^{*}Division of Sports Medicine, Department of Orthopaedic Surgery, University of Minnesota, Minneapolis, Minnesota.

[†]Steadman Philippon Research Institute, Vail, Colorado.

[‡]Department of Orthopaedics, Oslo University Hospital, University of Oslo, Oslo, Norway.

This research study was supported by a grant from Health South-East Norway (grant No. 2009064). The Minnesota Medical Foundation awarded Medical Student Summer Research Grants to 3 authors.

Ruptures of the anterior cruciate ligament (ACL) are among the most prevalent ligamentous knee injuries, particularly in younger athletes,^{18,23,40,43,44} with ACL reconstructions reported to be the sixth most common orthopaedic procedure performed in the United States.⁴² However, meta-analyses have reported that only 65% to 70% of patients undergoing ACL reconstruction return to the athletic activity level that they enjoyed before injury.^{7,17} Although good to excellent outcomes have been reported after most single-bundle ACL reconstructions,^{2,10,17} there remains a subset of patients (10% to 40%) who remain subjectively unstable and/or unable to regain prior function,^{8,18} with reports indicating continued pain and instability^{4-6,17} and the development of joint degenerative changes.^{32,34,45,52} Misplacement of tibial and femoral tunnels in single-bundle ACL reconstructions is reportedly

a primary factor resulting in clinical failure.^{1,11,26,29,49} Although the risk for tunnel misplacement may be increased in double-bundle ACL reconstruction, the more complex procedure has gained popularity in recent years because of efforts to more accurately reproduce the function and biomechanics of the native ACL, which is composed of 2 functional bundles, named the anteromedial (AM) and posterolateral (PL) bundles based on their tibial attachment sites.^{21,41,54} While the debate continues regarding whether double-bundle ACL reconstructions are superior to single-bundle ACL reconstructions in restoring normal knee biomechanics, advancements in knowledge concerning arthroscopically pertinent anatomy may help facilitate improved anatomical tunnel placement for single-bundle and double-bundle ACL reconstructions. However, there remains (1) a lack of consensus about which anatomical landmarks should be used arthroscopically to guide tunnel placement and (2) a disagreement concerning the orientation of the ACL tibial bundle attachments, with various descriptions reporting anterior-posterior, medial-lateral, and anteromedial to posterolateral oriented attachment sites.^{9,13,24,31,33,48,51} Moreover, although prior reports have evaluated the anatomical positions of the ACL and its 2 functional bundles using various methods,¹¹ the distances and locations of these structures' attachment sites in reference to arthroscopically pertinent bony and soft tissue landmarks on the femur and tibia have not been thoroughly assessed. Thus, it is important to more conclusively define clinically relevant arthroscopic anatomy regarding the attachment sites of the ACL and its respective AM and PL bundles.

The purpose of this study was to quantify distances between bony and soft tissue landmarks for the entire ACL and its individual bundles in relation to arthroscopically pertinent landmarks. Our hypothesis was twofold—first, that a comprehensive compilation of arthroscopically relevant anatomical measurements involving specific bony and soft tissue structures could be used to quantitate the locations of the ACL and AM and PL bundle centers in reference to one another and to arthroscopically pertinent anatomical landmarks of the femur and tibia; second, that a conclusive ACL bundle attachment orientation on the tibia could be defined.

MATERIALS AND METHODS

Skeletal Specimen Qualitative Analysis

We examined 14 femurs (6 right and 8 left) and 13 tibias (4 right and 9 left) from the complete skeletal bone collections archived at the University of Minnesota Anatomy Bequest Program to qualitatively assess common bony prominences and depressions on the tibial plateau and the lateral femoral condyle relative to the ACL attachments.

Cadaveric Specimen Preparation

Dissections were performed on 12 nonpaired fresh-frozen cadaveric knees (8 male, 4 female), with an average age

of 57.8 years (range, 45 to 70 years) and no signs of previous injury, abnormality, or disease. The quantitative data for 1 cadaveric knee specimen was excluded because of metallic interference during data collection that was not recognized until some structure attachment sites had already been dissected, which made retrospective identification of key landmarks and bundle attachment centers indiscernible. Each knee was stored at -20°C and thawed to room temperature before dissection. A medial parapatellar incision provided access to the ACL femoral attachments. Each knee was then carefully dissected with the ACL separated from the posterior cruciate ligament (PCL) using blunt dissection and with the PCL sectioned off its femoral and tibial insertions.

The AM and PL bundles of the ACL (Figure 1) were identified and subsequently separated on the basis of their femoral attachments at approximately 90° of knee flexion by observation of differences in bundle fiber orientation and tensioning with passive knee flexion and extension (Figure 2). A nonabsorbable braided suture was passed around the midsubstance of each bundle approximately 1 cm from the femoral and tibial attachment sites (2 sutures per bundle). To obtain an optimal view of the femoral attachment area, the femur was then divided in the sagittal plane at the apex of the roof of the intercondylar notch using an oscillating saw. The separated bundles were divided transversely at their midsubstance between the sutures. The sutures allowed the bundles to be individually tensioned to facilitate correct delineation of their perimeter attachment sites. The tibia and femur were then disarticulated to facilitate improved access to all remaining landmarks, and the anterior and posterior horns of the menisci were identified. All authors were involved in observational assessment and identification of structures.

Nomenclature

Anatomical terminology is presented pertaining to the knee in full extension. The femoral ACL footprint and corresponding landmarks are referenced in terms of anterior-posterior and proximal-distal orientation (Figure 3).

Anatomical Measurements

Measurements were made using the Polhemus Liberty (Polhemus Inc, Colchester, Vermont) electromagnetic tracking device. The system used an alternating current to create a pulsating magnetic field from the transmitter, which was received by a solenoid in the receiver sensitive to magnetic field changes. The MotionMonitor software (Innovative Sports Training, Chicago, Illinois) recorded the position and orientation of the receiver relative to the transmitter. The separation between the transmitter and receiver was 180 to 250 mm, which was within the reported optimal range of 100 to 700 mm for minimal position location error for the Polhemus system.³ The transmitter was securely fixed during testing to eliminate positional discrepancies, and sensors were placed within the optimal range of 22.5 to 64.0 cm from the transmitter. Within

¹¹References 8, 9, 12, 22, 24, 33, 37, 46, 51, 53.

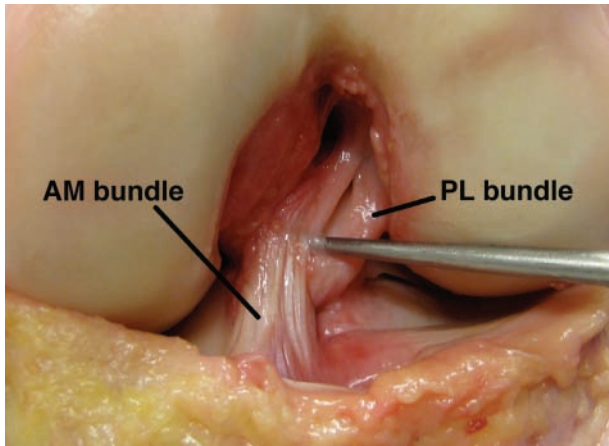


Figure 1. Anterior view of the native ACL showing the distinct anteromedial (AM) and posterolateral (PL) bundles (left knee).

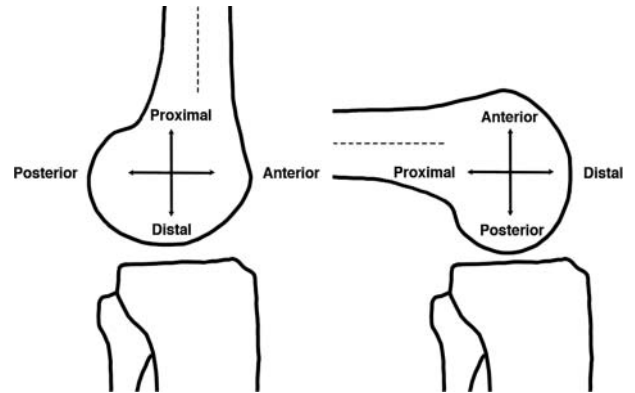


Figure 3. Illustration demonstrating the anatomical terminology used with both full extension and in 90° of knee flexion.

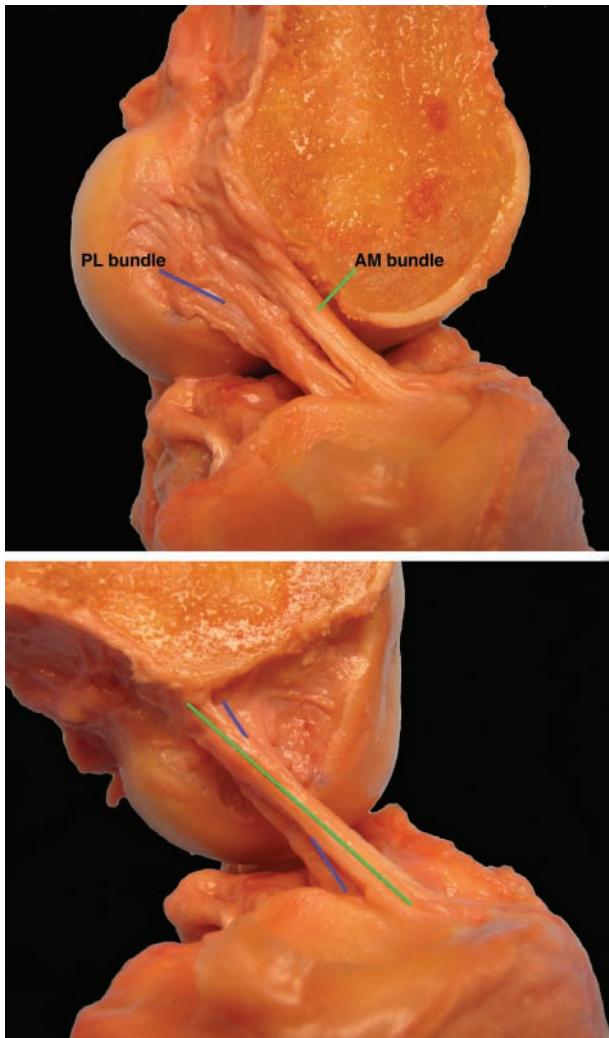


Figure 2. Lateral view of a left knee depicting the anteromedial (AM) bundle and posterolateral (PM) bundle of the ACL in extension (top) and flexion (bottom).

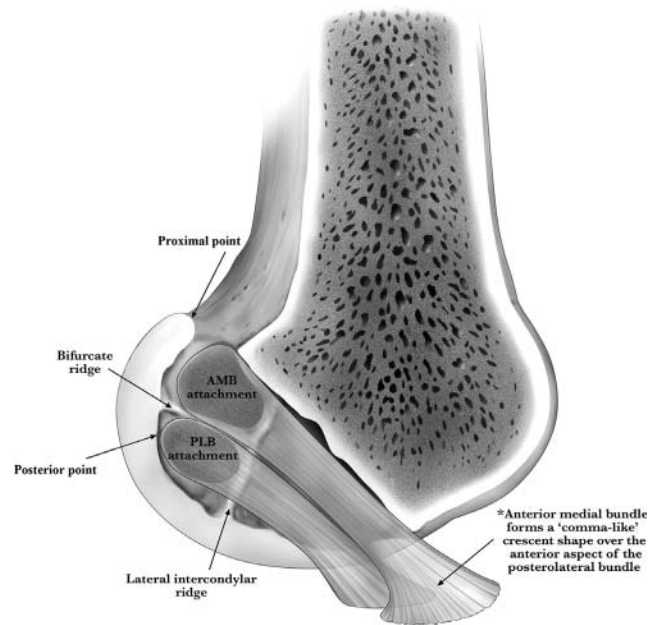


Figure 4. Illustration of a left knee lateral femoral condyle in extension demonstrating the relationship of the anteromedial bundle (AMB) and posterolateral bundle (PLB) to pertinent bony landmarks.

this range, there is a potential positional error of 0.25 mm and rotational error of 0.1°.³⁶ Each tibia or femur was potted in a cylindrical mold filled with polymethylmethacrylate (Dentsply, York, Pennsylvania) and securely fixed to a nonferrous conductive mount to eliminate magnetic field interference. One receiver was attached to a metallic Kirschner wire to serve as the stylus for recording the position data, which propagated the electromagnetic signal. The stylus was calibrated before testing each specimen. After calibration of this stylus, the proper orientation of the wire could be determined. The x , y , z coordinates of the point in question were recorded. The shortest, straight-line distances between the ACL and bundle

centers and the anatomical structures were found through calculation of the vector magnitude of the 2 points through a scientific computing program (MATLAB, Mathworks, Natick, Massachusetts). The primary author made all quantitative measurements.

The tibial and femoral attachment centers of the ACL and AM and PL bundles were identified relative to anatomical bony and soft tissue landmarks. The perimeters of the femoral and tibial ACL and bundle attachments and the meniscal attachment sites were outlined and recorded. The tibial and femoral bundle attachment centers were defined by tensioning the bundle remnants and observing the direction of the central fibers projecting onto the bony surface.⁹

Femoral Bony Landmarks

The specific bony landmarks quantitatively assessed on the lateral femoral condyle included the lateral intercondylar ridge,¹⁵ the bifurcate ridge,¹⁹ the proximal point, and the posterior point. Also called "resident's ridge," the lateral intercondylar ridge (Figures 4-6) is the elevated bony landmark found on the lateral wall of the intercondylar notch¹⁵ that runs anterior to the femoral ACL attachment²⁷ and constitutes the anterior border of the ACL footprint.^{15,19} The bifurcate ridge (Figures 4-6) is a bony landmark that separates the AM and PL bundles at their femoral attachments, running superior to inferior when the knee is at approximately 90° of flexion,^{19,20} which, according to anatomical terminology, corresponds with an anterior-to-posterior course when the knee is extended. The proximal point was defined as the point at the apex of the proximal curvature of the femoral articular cartilage margin (Figures 3-5). The posterior point was defined as the most posterior point along the posterior femoral articular cartilage margin in knee extension (Figures 3-5).

Tibial Bony and Soft Tissue Landmarks

Specific bony landmarks assessed in the vicinity of the ACL tibial attachment included the retro-eminence ridge,⁹ the lateral tibial eminence, the medial and lateral tibial plateau articular cartilage borders, and 3 newly defined bony landmarks: the ACL ridge, the ACL tubercle, and the anterolateral fossa (Figures 6-8). Specific soft-tissue landmarks measured included the anteromedial- and posteromedial-most attachments of the anterior horn of the lateral meniscus and the posterior horn of the lateral meniscus (Figure 7).

RESULTS

This section describes qualitative relationships based on skeletal bone specimen analysis and cadaveric observations from 3 examiners. Tables 1 and 2 list quantitative data for femur and tibia cadaveric specimens, respectively. For all structures, measurements of the shortest, straight-line distances from the overall ACL and bundle centers to the specific anatomical landmarks are reported as averages. The main arthroscopically pertinent reference points

are indicated in this section, with all data provided in Tables 1 and 2 as the mean and the standard error, including confidence intervals (95%).

Femoral Landmarks

With the knee in full extension, the PL bundle attached distal and slightly anterior to the AM bundle, with an average distance between bundle centers of 10.0 mm. The femoral ACL bundle attachments became more horizontally aligned with flexion exceeding 90° (Figure 2).

Lateral Intercondylar Ridge. The lateral intercondylar ridge was located anterior to the ACL femoral footprint, with structural prominence varying from visually apparent to only slightly palpable (Figures 4-6). The average length of the lateral intercondylar ridge was 18.0 mm, which spanned between the femoral articular cartilage margin and the femoral notch roof (Figures 4-6).

Bifurcate Ridge. The bifurcate ridge was relatively perpendicular to the lateral intercondylar ridge, and it extended from the lateral intercondylar ridge toward the posterior articular cartilage margin (Figures 4-6). The anterior edge of the bifurcate ridge ended at the lateral intercondylar ridge. The bifurcate ridge was observed in 12 of 14 bone box specimens and 12 of 12 cadaveric specimens, with the degree of prominence observed to vary from visibly prominent to only subtly palpable after removing all overlying soft tissue. The bifurcate ridge, located between the AM and PL bundles, was visible and palpable before soft tissue removal in only 1 knee; it required soft tissue removal for identification in the other 11 knees. The PL bundle attached in a depression distal and slightly posterior to the AM bundle attachment site. Rather than a distinct convex prominence, the bifurcate ridge resembled more of a "bifurcating ledge" that marked a distinct change in slope at the transition from the concave bony depression, which marked the PL bundle attachment, to an elevated bony plateau where the AM bundle attached. The average bifurcate ridge length was 11.6 mm.

ACL Femoral Attachment. The overall ACL attachment center was 6.1 mm posterior to the lateral intercondylar ridge, 1.7 mm proximal to the bifurcate ridge, 14.7 mm proximal to the distal cartilage margin, and 8.5 mm anterior to the posterior cartilage margin (Figures 4-6).

ACL Bundle Femoral Attachments. The AM bundle femoral attachment center was 7.1 mm posterior to the lateral intercondylar ridge, 4.8 mm proximal to the bifurcate ridge, 18.6 mm proximal to the distal cartilage margin, and 11.7 mm anterodistal to the proximal point (Figures 3-6). The PL bundle attachment center was 3.6 mm posterior to the lateral intercondylar ridge, 5.2 mm distal to the bifurcate ridge, 10.7 mm proximal to the distal cartilage margin, and 5.7 mm anterior to the posterior cartilage margin (Figures 3-6).

Tibial Landmarks

For all specimens, the division between the attachments of the AM and PL bundles on the tibia was obliquely oriented

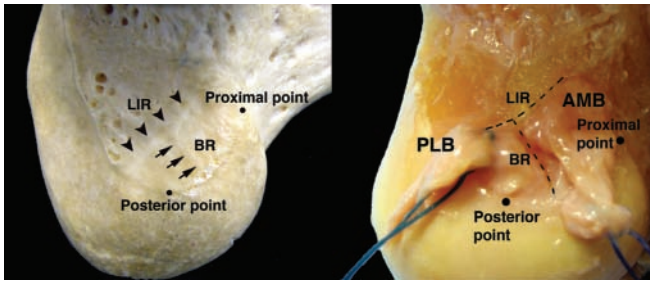
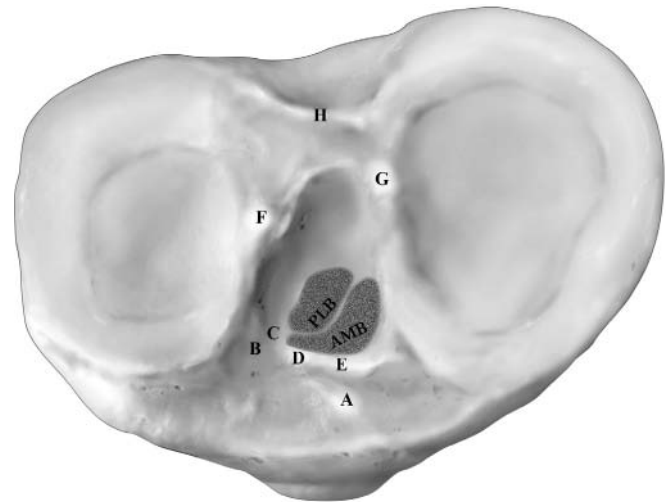


Figure 5. Skeletal (left) and cadaveric (right) views of right knee lateral femoral condyles illustrating pertinent landmarks. AMB, anteromedial bundle; PLB, posterolateral bundle; LIR, lateral intercondylar ridge; BR, bifurcate ridge.



- A=tubercle of anterior horn of medial meniscus
- B=anterolateral fossa
- C=attachment of anterior horn of lateral meniscus
- D=ACL tubercle
- E=ACL ridge
- F=lateral tibial eminence
- G=medial tibial eminence
- H=retro-eminence ridge

Figure 7. Illustration of a right tibia demonstrating the relationship of the anteromedial bundle (AMB) and posterolateral bundle (PLB) to key anatomical landmarks.

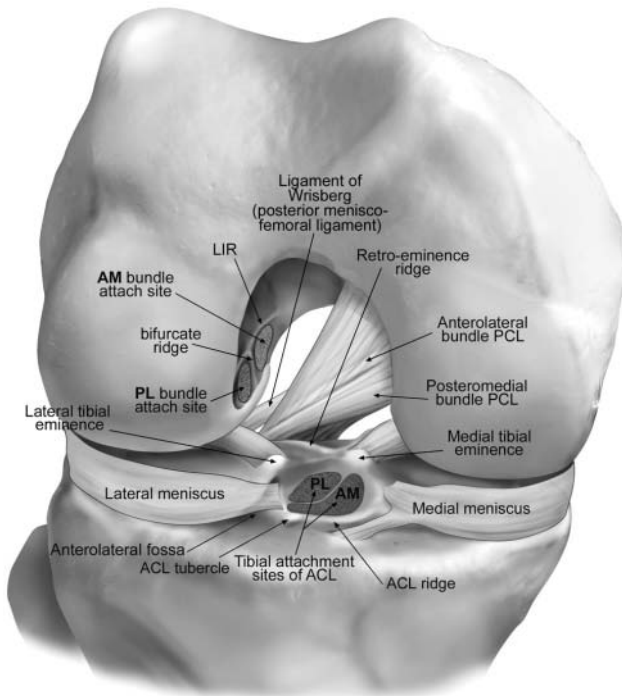


Figure 6. Illustration of an arthroscopic view of a right knee demonstrating pertinent arthroscopic landmarks on the femur and tibia, the tibial and femoral ACL bundle attachments, and the relationship of the tibial and femoral ACL attachments to each other in the native knee. AM, anteromedial bundle; PL, posterolateral bundle; LIR, lateral intercondylar ridge; PCL, posterior cruciate ligament.

and coursing in a posteromedial-to-anterolateral direction, with an average distance between the bundle centers of 10.1 mm. The distinctive contour of this division imparted a convex, comma-shaped appearance to the AM bundle footprint, which enveloped the anterior, convex contour of the PL bundle at its tibial attachment (via the tail of the comma; ie, the anterolateral extension of the AM footprint) and anteromedially (via the head of the comma; ie, the primary attachment of the AM footprint) (Figures 2, 4, 6-8).

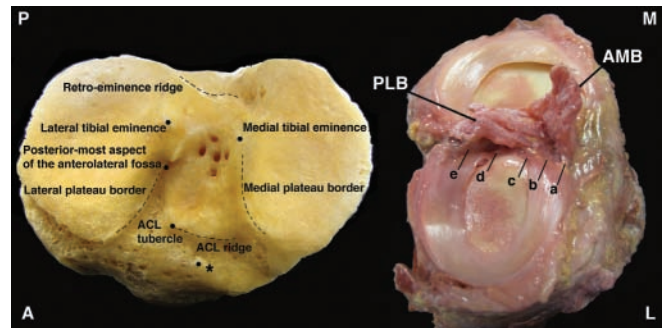


Figure 8. Skeletal (left) and cadaveric (right) tibia specimens indicating pertinent bony and soft tissue landmarks: (a) anterior-most attachment of the anterior horn of the lateral meniscus, (b) attachment midpoint of the anterior horn of the lateral meniscus, (c) posterior-most attachment of the anterior horn of the lateral meniscus attachment, (d) anterior attachment of the posterior horn of the lateral meniscus, and (e) fibrous attachment between the posterior horn of the lateral meniscus and the posterolateral bundle (PLB). The anteromedial bundle (AMB) envelops the anterior border of the PLB with the anterior portion of the ACL footprint predominated by AMB fibers. The majority of the PLB fibers are attached posteriorly within the ACL footprint. Also note the oblique division coursing posteromedial to anterolateral between the AMB and PLB. *Tubercle of the anterior horn of the medial meniscus (not to be confused with the ACL tubercle).

The main fibers of the AM bundle attached anteromedially within the ACL footprint, with the entire anterior

TABLE 1

Quantitative Relationships of the Centers of the Anterior Cruciate Ligament and the Anteromedial and Posterolateral Bundles to Landmarks on the Femur: Mean \pm SE^a

Relationship	Distance, mm	Confidence Intervals, 95%
Distance of the femoral ACL center to		
Lateral intercondylar ridge	6.1 \pm 0.5	5.0, 7.2
Bifurcate ridge	1.7 \pm 0.2	1.2, 2.1
Distal cartilage margin	14.7 \pm 0.6	13.5, 15.9
Posterior cartilage margin	8.5 \pm 0.6	7.4, 9.6
Proximal point	12.9 \pm 0.6	11.6, 14.2
Posterior point	10.0 \pm 0.7	8.7, 11.4
Distance of the AM bundle center to		
Lateral intercondylar ridge	7.1 \pm 0.6	5.8, 8.3
Bifurcate ridge	4.8 \pm 0.3	4.2, 5.3
Distal cartilage margin	18.6 \pm 0.5	17.5, 19.6
Proximal point	11.7 \pm 0.5	10.5, 12.9
Posterior point	15.1 \pm 0.5	14.1, 16.2
PL bundle center	10.0 \pm 0.3	9.4, 10.7
ACL center	5.2 \pm 0.5	4.3, 6.1
Distance of the PL bundle center to		
Lateral intercondylar ridge	3.6 \pm 0.5	2.5, 4.8
Bifurcate ridge	5.2 \pm 0.4	4.4, 6.1
Distal cartilage margin	10.7 \pm 0.3	10.0, 11.3
Posterior cartilage margin	5.7 \pm 0.3	5.0, 6.3
Proximal point	16.7 \pm 0.6	15.5, 17.8
Posterior point	6.9 \pm 0.4	6.1, 7.6
ACL center	5.2 \pm 0.5	4.3, 6.1

^aACL, anterior cruciate ligament; AM, anteromedial; PL, posterolateral.

perimeter of the ACL constituted by the AM bundle in all specimens (Figures 2, 4, 6-8).

Anterolateral Fossa. A bony depression immediately medial to the lateral tibial plateau articular cartilage border and anterior to the lateral tibial eminence was identified through observational analysis of skeletal bone specimens (Figures 6-8). Based on subsequent cadaveric observations of the same structure, this depression, which we termed the *anterolateral fossa*, corresponded to the attachment of the anterior horn of the lateral meniscus, which inserted along the medial upslope of this bony depression. The posterior-most aspect of the anterolateral fossa was located just posterior to the posterior aspect of the anterior horn of the lateral meniscus attachment (Figures 6-8).

ACL Ridge and Tubercle. Consistent among examiners and across all specimens, a bony elevation was observed coursing between the anterolateral fossa and the medial tibial plateau articular cartilage border, which corresponded to the anterior-most border of the ACL tibial attachment. This bony landmark was termed the *ACL ridge*. The ACL tubercle was defined as the protuberance located at the lateral-most edge of the ACL ridge, where it intersected the top of the medial upslope of the anterolateral fossa (Figures 6-8).

Retro-eminence Ridge. The retro-eminence ridge,⁹ also known as the "over the back" ridge^{28,35} or the "PCL

TABLE 2

Quantitative Relationships of the Centers of the Anterior Cruciate Ligament and the Anteromedial and Posterolateral Bundles to Landmarks on the Tibia: Mean \pm SE^a

Relationship	Distance, mm	Confidence Intervals, 95%
Distance of the tibial ACL center to		
ACL tubercle	10.4 \pm 0.6	9.1, 11.6
ACL ridge	10.5 \pm 0.5	9.5, 11.5
Anterior horn of lateral meniscus	7.5 \pm 0.5	6.5, 8.4
AM aspect of anterior horn of lateral meniscus attachment	10.2 \pm 0.5	9.0, 11.3
Posteromedial aspect of anterior horn of lateral meniscus attachment	8.5 \pm 0.5	7.5, 9.5
Posterior horn of lateral meniscus	15.7 \pm 0.6	14.5, 16.9
Posterior-most aspect of anterolateral fossa	10.5 \pm 0.3	9.9, 11.2
Lateral tibial eminence	11.0 \pm 0.4	10.1, 11.8
Retro-eminence ridge	13.0 \pm 0.4	12.1, 14.0
Lateral plateau cartilage border	11.7 \pm 0.5	10.7, 12.6
Medial plateau cartilage border	7.9 \pm 0.4	7.1, 8.8
Distance of the tibial AM bundle center to		
ACL tubercle	7.1 \pm 0.5	6.0, 8.1
ACL ridge	5.6 \pm 0.4	4.8, 6.5
AM aspect of anterior horn of lateral meniscus attachment	8.3 \pm 0.6	7.1, 9.6
Posterior-most aspect of anterolateral fossa	14.3 \pm 0.6	13.1, 15.6
Lateral tibial eminence	14.1 \pm 0.5	13.0, 15.2
Retro-eminence ridge	17.8 \pm 0.8	16.1, 19.5
Lateral plateau cartilage border	13.6 \pm 0.5	12.6, 14.6
Medial plateau cartilage border	8.8 \pm 0.6	7.6, 10.8
PL bundle center	10.1 \pm 0.4	9.2, 11.0
ACL center	4.8 \pm 0.3	4.1, 5.5
Distance of the tibial PL bundle center to		
ACL ridge	15.0 \pm 0.7	13.6, 16.5
Posteromedial aspect of anterior horn of lateral meniscus attachment	6.6 \pm 0.4	5.7, 7.5
Posterior horn of lateral meniscus	10.8 \pm 0.7	9.3, 12.2
Posterior-most aspect of anterolateral fossa	7.5 \pm 0.5	6.5, 8.4
Lateral tibial eminence	8.9 \pm 0.4	8.1, 9.7
Retro-eminence ridge	8.4 \pm 0.6	7.1, 9.7
Lateral plateau cartilage border	10.3 \pm 0.6	9.0, 11.5
Medial plateau cartilage border	8.5 \pm 0.4	7.6, 9.4
ACL center	5.6 \pm 0.3	5.0, 6.1

^aACL, anterior cruciate ligament; AM, anteromedial; PL, posterolateral.

notch"²⁵ was the transverse intereminence ridge located at the apex of the posterior slope of the tibial plateau just anterosuperior to the tibial PCL attachment (Figures 6-8). This bony landmark was observed in all specimens.

ACL Tibial Attachment. The ACL center was 10.5 mm posterior to the ACL ridge, 13.0 mm anterior to the retro-eminence ridge, 7.5 mm medial to the anterior horn of the lateral meniscus, 10.2 mm posteromedial to the anterior-most fibers of the anterior horn of the lateral meniscus, 8.5 mm AM to the posterior-most fibers of the anterior horn of the lateral meniscus, 15.7 mm anterior

to the posterior root attachment of the lateral meniscus, 4.8 mm posterior to the AM bundle center, and 5.6 mm anterior to the PL bundle center (Figures 6-8).

ACL Tibial Individual Bundle Attachments. The AM bundle center was 10.1 mm AM to the PL bundle, 5.6 mm posterior to the ACL ridge, 17.8 mm anterior to the retro-eminence ridge, and 8.3 mm medial to the anterior-most fibers of the anterior horn of the lateral meniscus attachment (Figures 6-8).

The AM bundle bordered the PL bundle anteromedially. The PL bundle center was 15.0 mm posterior to the ACL ridge, 8.4 mm anterior to the retro-eminence ridge, 6.6 mm medial to the posterior-most fibers of the anterior horn of the lateral meniscus attachment, and 10.8 mm anterior to the posterior root attachment of the lateral meniscus (Figures 6-8).

Lateral Meniscal Attachments to ACL. Fibrous attachments extending from the anterior horn of the lateral meniscus attachment to the ACL bundles were observed in all knees (Figure 8). The fibrous attachments from the anterior aspect of the anterior horn of the lateral meniscus attachment were aligned with the AM bundle, whereas the posterior aspect fibrous attachments were aligned with the PL bundle (Figure 8). The midpoint along the medial attachment border of the anterior horn of the lateral meniscus was aligned with the overall ACL center (Figure 8). The anterior aspect of the anterior horn of the lateral meniscus attached solely to the AM bundle in 10 of 12 knees and to the AM and PL bundles in the remaining 2 knees. The posterior aspect of the anterior horn of the lateral meniscus attached solely to the PL bundle in all knees. A fibrous attachment connected the posterior horn of the lateral meniscus and the PL bundle in 11 of 12 specimens (Figure 8).

DISCUSSION

We validated our hypothesis and developed a comprehensive compilation of quantitative anatomical measurements that quantitate the attachment centers of the overall ACL and AM and PL bundles to arthroscopically pertinent bony and soft tissue landmarks. Along with advancing knowledge of the anatomy surrounding the ACL femoral and tibial attachments, our results could be used to enhance the arthroscopic assessment of these reconstruction tunnel locations and may help prevent tunnel malposition, which is reported to be a primary factor resulting in ACL reconstruction graft failure.^{1,11,26,29,49}

Although prior studies have assessed the anatomy of the ACL and its femoral and tibial attachments, they have done so without quantifying distances to the specific osseous and soft tissue landmarks, which are important for arthroscopic placement.^{24,39} Among those reports that have quantitatively referenced specific bony and soft tissue landmarks, the measurements were typically made to the overall ACL center^{28,30,35} or only the ACL bundle centers^{8,9,14,47,48,51,53} but not to all 3 ACL reference points (as performed in our study) and with limited quantitative assessment of bony and soft tissue landmarks located exclusively within the arthroscopic view typical of ACL

reconstructions. Whereas Luites et al,³³ in particular, discussed the localization of the overall ACL and individual bundle centers, their report focused primarily on locating tunnel centers using reference lines rather than quantifying distances from specific bony and soft tissue landmarks.

Bony landmarks on the lateral femoral condyle, including the lateral intercondylar ridge, bifurcate ridge, femoral notch roof, over-the-top position, and the posterior notch outlet, have been described as landmarks for determining AM and PL bundle tunnel placement.[¶] The lateral intercondylar ridge may be a particularly useful bony landmark because of its well-defined relationship to the ACL. The lateral intercondylar ridge, which serves as the anterior border of the ACL femoral attachment, was identified on all skeletal and cadaveric specimens, which is consistent with prior reports.^{15,16} Whereas the lateral intercondylar ridge is usually identifiable arthroscopically, the bifurcate ridge, which separates the AM and PL bundle attachments, is more subtle, harder to locate, and may not always be apparent during arthroscopic surgery. It is important to note that a distinct change of slope resembling a ledge more than a convex bifurcate ridge was observed between the AM bundle and PL bundle attachment sites, and identification of this subtler feature may be difficult arthroscopically. When the bifurcate ridge is visible and palpable, the structure has the potential to serve as a useful surgical landmark. We also measured landmarks from the distal and posterior articular cartilage margins, the proximal point, and the posterior point, which can also serve as references to guide ACL femoral reconstruction tunnel placement. Particularly, based on our measurements, the perpendicular intersection of a line extending proximally from the distal articular cartilage margin and a line extending anteriorly from the posterior articular cartilage margin may be useful in bundle center localization.

Whereas bony landmarks relative to the ACL femoral attachment have been described, there has been less qualitative or quantitative information concerning tibial bony landmarks. Some studies have referenced the posterior edge of the tibia and the anterior tibial plateaus for tunnel placement.^{13,51} However, these landmarks do not appear in the arthroscopic view. Bony landmarks such as the retro-eminence ridge,⁹ the rims of the tibial plateau articular cartilage,^{25,48} and the medial tibial eminence^{13,28} have also been described. Bony landmarks have the potential to be more clinically useful references because of their arthroscopic accessibility, proximity to the ACL attachment, and overall lack of deformation compared with soft tissue structures. For example, the anterior margin of the PCL has been reported to be a landmark for ACL tibial tunnel placement at 90° of knee flexion,^{28,38} but the utility of this landmark depends on which aspect of the PCL is used as a reference, if the PCL is injured, and whether the tibia is anteriorly subluxated on the femur. Thus, we believe that the retro-eminence ridge,⁹ also referred as the over-the-back ridge^{13,28,35} or PCL notch,²⁵ is a more reliable tibial landmark for referencing the ACL

¶References 14, 15, 16, 19, 27, 46, 47, 51, 55.

attachment than the PCL, which is deformable, may be obscured by adipose and synovial tissue, and cannot be utilized in a PCL-deficient knee. In addition to the retro-emergence ridge located posteriorly on the tibia, we identified 3 new tibial bony landmarks anterior to the ACL attachment: the ACL ridge, ACL tubercle, and anterolateral fossa. The ACL ridge, which marks the anterior boundary of the ACL attachment on the tibia, is a bony structure in immediate proximity to the ACL and may have clinical applicability. The posterior aspect of the anterolateral fossa is in close association with the posterior aspect of the anterior horn of the lateral meniscus attachment. Therefore, the posterior aspect of the anterolateral fossa provides a bony reference located posterolateral to the overall ACL attachment center. Although the ACL ridge, in particular, may serve as an effective arthroscopic landmark, further research into the clinical use of these newly described tibial bony structures is recommended.

Tibial tunnel placement has also been identified with reference to soft tissue landmarks such as the anterior horn of the lateral meniscus,^{30,41,55} the posterior horn of the lateral meniscus,^{8,48} the borders of the ACL footprint on the tibia,⁹ the PCL,^{8,28,30,38,53,55} and the ACL remnant.^{30,48} Although Zantop et al⁵⁵ reported that the AM bundle aligned with the anterior horn of the lateral meniscus, we specifically observed that the anterior aspect of the anterior horn of the lateral meniscus aligned with the AM bundle center and that the posterior aspect of the lateral meniscus anterior horn aligned with the PL bundle center. Like the PCL, the anterior horn of the lateral meniscus is also a soft structure, which has the potential for deformability and deficiency. However, because of the immediate proximity of the respective meniscus attachment to the ACL and the rarity of injury to this attachment, we believe that this structure has the potential to be a more reliable soft tissue landmark than the PCL.

Our measurements of the distance between the AM bundle center and the retro-emergence ridge correlate with the results of Edwards et al¹³ and confirm a previous relationship suggested by Colombet et al⁹—namely, that the actual AM bundle center is located more anterior than what has been historically recommended for single-bundle ACL tunnel placement.^{28,35,38} As with prior reports,^{13,55} our results also indicate that the previously recommended location for single-bundle tunnel placement^{26,28,35,38,50} is actually located within the PL bundle insertion on the tibia, which is posterior to the native ACL center of attachment. Therefore, placing the single-bundle tunnel medial to the midpoint along the attachment border of the anterior horn of the lateral meniscus may be a useful arthroscopic landmark for single-bundle ACL reconstructions.

Despite various descriptions concerning the ACL bundle attachment orientation on the tibia, including anterior-posterior,^{13,24,33} anteromedial to posterolateral,^{13,48} and medial-lateral,^{9,51} we confirmed our hypothesis and found that the AM bundle of the ACL completely covered the anterior contour of the PL bundle in an oblique, anteromedial to posterolateral fashion, with the distinctive contour of this division imparting a convex, comma-shaped appearance to the AM bundle footprint (Figures 2 and 4). In all

cases, the main fibers of the AM bundle attached antero-medially within the ACL footprint, with the entire anterior perimeter of the ACL constituted by the AM bundle (Figures 6, 7, and 8). These observations were based on separation of the AM and PL bundles beginning at their femoral attachments at 90° of knee flexion, which we believe provides for a more accurate and definitive ACL bundle separation than that at the tibia because of the more distinct division between the bundles projecting off the femur at this flexion angle. This means that during an arthroscopic evaluation of the ACL, the AM bundle is the one visualized directly anterior at its tibial attachment.

Although identification of the individual bundle attachments of the ACL has been reported, identification of arthroscopically pertinent landmarks for the individual ACL bundles and the entire ACL has not been extensively examined. We chose to study the entire ACL attachment and its individual bundle attachments on the femur and tibia because it is, as yet, not defined whether a significant clinical difference exists between single- and double-bundle ACL reconstructions and for which subset of patients each type of reconstruction may be more beneficial. We believe that a primary benefit of research into double-bundle ACL reconstructions is that anatomical placement of single-bundle ACL reconstructions will be concomitantly improved. The arthroscopically relevant measurements provided in this work should also lead to more improved single-bundle ACL reconstruction graft placement.

In conclusion, utilizing the information gained from the arthroscopically pertinent measurements in reference to the bony and soft tissue landmarks described in this study will facilitate more precise arthroscopic delineation of the ACL and AM and PL bundle centers at their femoral and tibial attachments. Improving tunnel positioning in ACL reconstruction surgery is crucial to prevent tunnel misplacement and to minimize ACL reconstruction graft failure, making the anatomical measurements and illustrations provided by our study a potentially valuable resource for improved anatomical tunnel placement in single-bundle and double-bundle ACL reconstructions.

ACKNOWLEDGMENT

We acknowledge the assistance of the Anatomy Bequest Program of the University of Minnesota.

REFERENCES

1. Aglietti P, Buzzi R, Giron F, Simeone AJ, Zaccherotti G: Arthroscopic-assisted anterior cruciate ligament reconstruction with the central third patellar tendon: a 5-8-year follow-up. *Knee Surg Sports Traumatol Arthrosc.* 1997;5(3):138-144.
2. Aglietti P, Giron F, Buzzi R, Biddau F, Sasso F: Anterior cruciate ligament reconstruction: bone-patellar tendon-bone compared with double semitendinosus and gracilis tendon grafts: a prospective, randomized clinical trial. *J Bone Joint Surg Am.* 2004;86(10):2143-2155.
3. An KN, Jacobsen MC, Berglund LJ, Chao EY: Application of a magnetic tracking device to kinesiologic studies. *J Biomech.* 1988;21(7):613-620.

4. Anderson AF, Dome DC, Gautam S, Awh MH, Rennirt GW: Correlation of anthropometric measurements, strength, anterior cruciate ligament size, and intercondylar notch characteristics to sex differences in anterior cruciate ligament tear rates. *Am J Sports Med.* 2001;29(1):58-66.
5. Aune AK, Holm I, Risberg MA, Jensen HK, Steen H: Four-strand hamstring tendon autograft compared with patellar tendon-bone autograft for anterior cruciate ligament reconstruction: a randomized study with two-year follow-up. *Am J Sports Med.* 2001;29(6):722-728.
6. Barrett GR, Noojin FK, Hartzog CW, Nash CR: Reconstruction of the anterior cruciate ligament in females: a comparison of hamstring versus patellar tendon autograft. *Arthroscopy.* 2002;18(1):46-54.
7. Biau DJ, Tournoux C, Katsahian S, Schranz P, Nizard R: ACL reconstruction: a meta-analysis of functional scores. *Clin Orthop Relat Res.* 2007;458:180-187.
8. Chhabra A, Starman JS, Ferretti M, Vidal AF, Zantop T, Fu FH: Anatomic, radiographic, biomechanical, and kinematic evaluation of the anterior cruciate ligament and its two functional bundles. *J Bone Joint Surg Am.* 2006;88(suppl 4):2-10.
9. Colombet P, Robinson J, Christel P, Franceschi JP, Djian P, Bellier G, Sbihi A: Morphology of anterior cruciate ligament attachments for anatomic reconstruction: a cadaveric dissection and radiographic study. *Arthroscopy.* 2006;22(9):984-992.
10. Cooley VJ, Deffner KT, Rosenberg TD: Quadrupled semitendinosus anterior cruciate ligament reconstruction: 5-year results in patients without meniscus loss. *Arthroscopy.* 2001;17(8):795-800.
11. Diamantopoulos AP, Lorbach O, Paessler HH: Anterior cruciate ligament revision reconstruction: results in 107 patients. *Am J Sports Med.* 2008;36(5):851-860.
12. Duthon VB, Barea C, Abrassart S, Fasel JH, Fritschy D, Ménétrey J: Anatomy of the anterior cruciate ligament. *Knee Surg Sports Traumatol Arthrosc.* 2006;14(3):204-213.
13. Edwards A, Bull AM, Amis AA: The attachments of the anteromedial and posterolateral fibre bundles of the anterior cruciate ligament: part 1. Tibial attachment. *Knee Surg Sports Traumatol Arthrosc.* 2007;15(12):1414-1421.
14. Edwards A, Bull AM, Amis AA: The attachments of the anteromedial and posterolateral fibre bundles of the anterior cruciate ligament: part 2. Femoral attachment. *Knee Surg Sports Traumatol Arthrosc.* 2008;16(1):29-36.
15. Farrow LD, Chen MR, Cooperman DR, Victoroff BN, Goodfellow DB: Morphology of the femoral intercondylar notch. *J Bone Joint Surg Am.* 2007;89(10):2150-2155.
16. Ferretti M, Ekdahl M, Shen W, Fu FH: Osseous landmarks of the femoral attachment of the anterior cruciate ligament: an anatomic study. *Arthroscopy.* 2007;23(11):1218-1225.
17. Freedman KB, D'Amato MJ, Nedeff DD, Kaz A, Bach BR Jr: Arthroscopic anterior cruciate ligament reconstruction: a metaanalysis comparing patellar tendon and hamstring tendon autografts. *Am J Sports Med.* 2003;31(1):2-11.
18. Fu FH, Bennett CH, Lattermann C, Ma CB: Current trends in anterior cruciate ligament reconstruction: part 1. Biology and biomechanics of reconstruction. *Am J Sports Med.* 1999;27(6):821-830.
19. Fu FH, Jordan SS: The lateral intercondylar ridge: a key to anatomic anterior cruciate ligament reconstruction. *J Bone Joint Surg Am.* 2007;89(10):2103-2104.
20. Fu FH, Shen W, Starman JS, Okeke N, Irrgang JJ: Primary anatomic double-bundle anterior cruciate ligament reconstruction: a preliminary 2-year prospective study. *Am J Sports Med.* 2008;36(7):1263-1274.
21. Girgis FG, Marshall JL, Monajem A: The cruciate ligaments of the knee joint: anatomical, functional and experimental analysis. *Clin Orthop Relat Res.* 1975;106:216-231.
22. Giron F, Cuomo P, Aglietti P, Bull AM, Amis AA: Femoral attachment of the anterior cruciate ligament. *Knee Surg Sports Traumatol Arthrosc.* 2006;14(3):250-256.
23. Griffin LY, Agel J, Albohm MJ, et al: Noncontact anterior cruciate ligament injuries: risk factors and prevention strategies. *J Am Acad Orthop Surg.* 2000;8(3):141-150.
24. Harner CD, Baek GH, Vogrin TM, Carlin GJ, Kashiwaguchi S, Woo SL: Quantitative analysis of human cruciate ligament insertions. *Arthroscopy.* 1999;15(7):741-749.
25. Heming JF, Rand J, Steiner ME: Anatomical limitations of transtibial drilling in anterior cruciate ligament reconstruction. *Am J Sports Med.* 2007;35(10):1708-1715.
26. Howell SM: Principles for placing the tibial tunnel and avoiding roof impingement during reconstruction of a torn anterior cruciate ligament. *Knee Surg Sports Traumatol Arthrosc.* 1998;6(suppl 1):S49-S55.
27. Hutchinson MR, Ash SA: Resident's ridge: assessing the cortical thickness of the lateral wall and roof of the intercondylar notch. *Arthroscopy.* 2003;19(9):931-935.
28. Hutchinson MR, Bae TS: Reproducibility of anatomic tibial landmarks for anterior cruciate ligament reconstructions. *Am J Sports Med.* 2001;29(6):777-780.
29. Ikeda H, Muneta T, Niga S, Hoshino A, Asahina S, Yamamoto H: The long-term effects of tibial drill hole position on the outcome of anterior cruciate ligament reconstruction. *Arthroscopy.* 1999;15(3):287-291.
30. Jackson DW, Gasser SI: Tibial tunnel placement in ACL reconstruction. *Arthroscopy.* 1994;10(2):124-131.
31. Kopf S, Musahl V, Tashman S, Szczodry M, Shen W, Fu FH: A systematic review of the femoral origin and tibial insertion morphology of the ACL. *Knee Surg Sports Traumatol Arthrosc.* 2009;17(3):213-219.
32. Lohmander LS, Ostergren A, Englund M, Roos H: High prevalence of knee osteoarthritis, pain, and functional limitations in female soccer players twelve years after anterior cruciate ligament injury. *Arthritis Rheum.* 2004;50(10):3145-3152.
33. Luites JW, Wymenga AB, Blankevoort L, Kooloos JG: Description of the attachment geometry of the anteromedial and posterolateral bundles of the ACL from arthroscopic perspective for anatomical tunnel placement. *Knee Surg Sports Traumatol Arthrosc.* 2007;15(12):1422-1431.
34. Maletius W, Messner K: Eighteen- to twenty-four-year follow-up after complete rupture of the anterior cruciate ligament. *Am J Sports Med.* 1999;27(6):711-717.
35. McGuire DA, Hendricks SD, Sanders HM: The relationship between anterior cruciate ligament reconstruction tibial tunnel location and the anterior aspect of the posterior cruciate ligament insertion. *Arthroscopy.* 1997;13(4):465-473.
36. Milne AD, Chess DG, Johnson JA, King GJ: Accuracy of an electromagnetic tracking device: a study of the optimal range and metal interference. *J Biomech.* 1996;29(6):791-793.
37. Mochizuki T, Muneta T, Nagase T, Shirasawa S, Akita KI, Sekiya I: Cadaveric knee observation study for describing anatomic femoral tunnel placement for two-bundle anterior cruciate ligament reconstruction. *Arthroscopy.* 2006;22(4):356-361.
38. Morgan CD, Kalman VR, Grawl DM: Definitive landmarks for reproducible tibial tunnel placement in anterior cruciate ligament reconstruction. *Arthroscopy.* 1995;11(3):275-288.
39. Muneta T, Sekiya I, Yagishita K, Ogiuchi T, Yamamoto H, Shinomiya K: Two-bundle reconstruction of the anterior cruciate ligament using semitendinosus tendon with endobuttons: operative technique and preliminary results. *Arthroscopy.* 1999;15(6):618-624.
40. Myklebust G, Maehlum S, Engebretsen L, Strand T, Solheim E: Registration of cruciate ligament injuries in Norwegian top level team handball: a prospective study covering two seasons. *Scand J Med Sci Sports.* 1997;7(5):289-292.
41. Petersen W, Zantop T: Anatomy of the anterior cruciate ligament with regard to its two bundles. *Clin Orthop Relat Res.* 2007;454:35-47.
42. Prodromos CC, Fu FH, Howell SM, Johnson DH, Lawhorn K: Controversies in soft-tissue anterior cruciate ligament reconstruction: grafts, bundles, tunnels, fixation, and harvest. *J Am Acad Orthop Surg.* 2008;16(7):376-384.
43. Prodromos CC, Han Y, Rogowski J, Joyce B, Shi K: A meta-analysis of the incidence of anterior cruciate ligament tears as a function of

- gender, sport, and a knee injury-reduction regimen. *Arthroscopy*. 2007;23(12):1320-1325.
44. Renstrom P, Ljungqvist A, Arendt E, et al: Non-contact ACL injuries in female athletes: an International Olympic Committee current concepts statement. *Br J Sports Med*. 2008;42(6):394-412.
45. Salmon LJ, Russell VJ, Refshauge K, et al: Long-term outcome of endoscopic anterior cruciate ligament reconstruction with patellar tendon autograft: minimum 13-year review. *Am J Sports Med*. 2006;34(5):721-732.
46. Shen W, Forsythe B, Ingham SM, Honkamp NJ, Fu FH: Application of the anatomic double-bundle reconstruction concept to revision and augmentation anterior cruciate ligament surgeries. *J Bone Joint Surg Am*. 2008;90(suppl 4):20-34.
47. Siebold R, Ellert T, Metz S, Metz J: Femoral insertions of the anteromedial and posterolateral bundles of the anterior cruciate ligament: morphometry and arthroscopic orientation models for double-bundle bone tunnel placement: a cadaver study. *Arthroscopy*. 2008;24(5):585-592.
48. Siebold R, Ellert T, Metz S, Metz J: Tibial insertions of the anteromedial and posterolateral bundles of the anterior cruciate ligament: morphometry, arthroscopic landmarks, and orientation model for bone tunnel placement. *Arthroscopy*. 2008;24(2):154-161.
49. Sommer C, Friederich NF, Müller W: Improperly placed anterior cruciate ligament grafts: correlation between radiological parameters and clinical results. *Knee Surg Sports Traumatol Arthrosc*. 2000;8(4):207-213.
50. Staubli HU, Rauschnig W: Tibial attachment area of the anterior cruciate ligament in the extended knee position: anatomy and cryosections in vitro complemented by magnetic resonance arthrography in vivo. *Knee Surg Sports Traumatol Arthrosc*. 1994;2(3):138-146.
51. Takahashi M, Doi M, Abe M, Suzuki D, Nagano A: Anatomical study of the femoral and tibial insertions of the anteromedial and posterolateral bundles of human anterior cruciate ligament. *Am J Sports Med*. 2006;34(5):787-792.
52. von Porat A, Roos EM, Roos H: High prevalence of osteoarthritis 14 years after an anterior cruciate ligament tear in male soccer players: a study of radiographic and patient relevant outcomes. *Ann Rheum Dis*. 2004;63(3):269-273.
53. Yasuda K, Kondo E, Ichiyama H, et al: Anatomic reconstruction of the anteromedial and posterolateral bundles of the anterior cruciate ligament using hamstring tendon grafts. *Arthroscopy*. 2004;20(10):1015-1025.
54. Zantop T, Petersen W, Sekiya JK, Musahl V, Fu FH: Anterior cruciate ligament anatomy and function relating to anatomical reconstruction. *Knee Surg Sports Traumatol Arthrosc*. 2006;14(10):982-992.
55. Zantop T, Wellmann M, Fu FH, Petersen W: Tunnel positioning of anteromedial and posterolateral bundles in anatomic anterior cruciate ligament reconstruction: anatomic and radiographic findings. *Am J Sports Med*. 2008;36(1):65-72.

For reprints and permission queries, please visit SAGE's Web site at <http://www.sagepub.com/journalsPermissions.nav>