


Arthroscopically Pertinent Anatomy of the Anterolateral and Posteromedial Bundles of the Posterior Cruciate Ligament

Colin J. Anderson, MD, Connor G. Ziegler, MD, Coen A. Wijdicks, PhD,
Lars Engebretsen, MD, PhD, and Robert F. LaPrade, MD, PhD

Investigation performed at the Department of BioMedical Engineering, Steadman Philippon Research Institute, Vail, Colorado



A substantial number of patients have been reported to experience declining knee function and early osteoarthritis following the nonoperative treatment of isolated and combined grade-III posterior cruciate ligament (PCL)

injuries¹⁻⁵. The desire to restore knee function has driven growing interest in surgical reconstruction of the injured PCL. However, clinical studies have demonstrated that single-bundle PCL reconstructions have failed to restore normal kinematics

Disclosure: One or more of the authors received payments or services, either directly or indirectly (i.e., via his or her institution), from a third party in support of an aspect of this work. In addition, one or more of the authors, or his or her institution, has had a financial relationship, in the thirty-six months prior to submission of this work, with an entity in the biomedical arena that could be perceived to influence or have the potential to influence what is written in this work. No author has had any other relationships, or has engaged in any other activities, that could be perceived to influence or have the potential to influence what is written in this work. The complete **Disclosures of Potential Conflicts of Interest** submitted by authors are always provided with the online version of the article.

to the knee and have not prevented osteoarthritis in the long term^{6,7}. Double-bundle PCL reconstructions that restore the posteromedial bundle in addition to the biomechanically and functionally dominant anterolateral bundle have demonstrated some improvement in knee stability in vitro^{8,9}. However, clinical studies to date have not demonstrated improved subjective or objective outcomes for double-bundle compared with single-bundle reconstructions¹⁰⁻¹⁴.

There is a growing paradigm that cruciate ligament reconstruction achieves improved results with restoration of the native anatomy¹⁵⁻²⁰. While this has been better supported in the anterior cruciate ligament (ACL) literature^{21,22}, with the higher frequency of ACL injuries having facilitated an accelerated progression of research findings, similar evidence is mounting for the treatment of PCL tears. Early in vitro studies evaluating isometric PCL reconstructions demonstrated inferior performance compared with more anatomic tunnel placement because the isometric reconstructions resulted in posterior translational instability in flexion and knee overconstraint in extension^{9,17,23}. Likewise, suboptimal clinical results have been reported for non-anatomic, compared with more presumed anatomic, femoral tunnel placement¹⁹. However, an accurate and reproducible method to guide anatomic tunnel placement for PCL reconstructions has not been developed¹⁶.

The “clock-face” method is the most frequently reported method to describe PCL femoral tunnel placement¹⁶. However, anatomic and surgical studies have demonstrated wide disagreement in the reported locations of the PCL bundles with use of the clock-face method¹⁶. Furthermore, the clock-face method has been shown to have poor reproducibility between surgeons when used for ACL tunnel placement²⁴. A standardized method to guide tibial tunnel placement also has not been described.

Our motivation for this study was to provide guidelines for femoral and tibial PCL tunnel placement based specifically on a more detailed understanding of the surrounding anatomy so that recognition of key landmarks could more accurately guide arthroscopic localization of the PCL attachment centers on the femur and tibia. The purpose of the present study was to both qualitatively and quantitatively describe the locations of the anterolateral and posteromedial bundles of the PCL relative to arthroscopically relevant landmarks to assist with anatomic tunnel placement during both single and double-bundle PCL reconstruction surgery.

Materials and Methods

Specimens

Twelve femoral and twelve tibial bone specimens from the Human Anatomy Program at the University of Colorado at Boulder were qualitatively analyzed for osseous prominences related to the position of the PCL. Three fresh-frozen nonpaired knees were then dissected as pilots to verify the presence of these osseous prominences and to define the optimal dissection approach.

Anatomic Dissection

Next, dissections were performed on twenty nonpaired, fresh-frozen human cadaveric knees with no evidence of previous injury or degenerative change. The mean age of the donors at the time of death was 46.2 years (range, twenty-

one to forty-nine years). Standard anatomic nomenclature was used with the knee described in the extended position²⁵. The PCL was approached anteriorly through a medial parapatellar arthrotomy and posteriorly by means of careful dissection of the posterior capsule and the oblique popliteal ligament, with blunt instrumentation being used to avoid damaging the distal fibers of the PCL or the posterior meniscofemoral ligament. If present, the anterior meniscofemoral ligament of Humphrey and the posterior meniscofemoral ligament of Wrisberg were separated from the PCL. Because the anterolateral bundle is tightest at 90° of knee flexion and the posteromedial bundle is tightest at both full extension and flexion, the anterolateral bundle and posteromedial bundle were individually identified following observation of their tensioning patterns as the knee was repeatedly cycled through its range of motion. The initial separation between the bundles was created posteriorly with a curved fine-tipped hemostat, close to the femoral attachment, where the separation between the bundles was best visualized. Next, the bundles were divided completely with use of fine dissecting scissors along the interfascicular connective tissue between the bundles. Nonabsorbable sutures were used to isolate each fiber bundle proximally and distally, with the functional center of each individual bundle being isolated according to a previously described technique²⁵, and the knee was disarticulated.

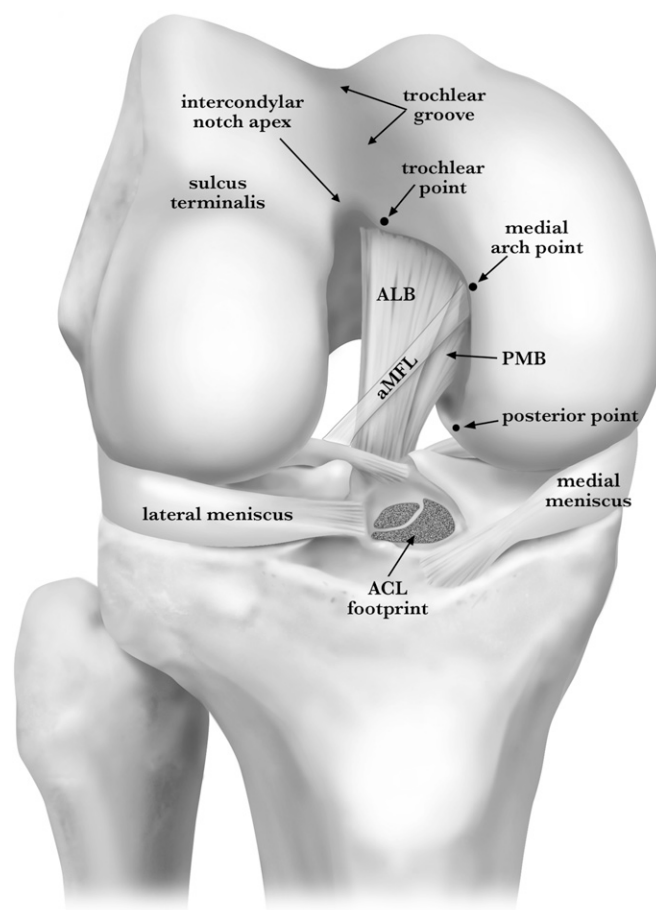


Fig. 1

Illustration of the anterior view of a right knee flexed to 90° with the PCL intact, demonstrating the characteristic morphology of the cartilage margin of the femoral intercondylar notch. The illustration also shows the trochlear, medial arch, and posterior points as well as the intercondylar notch apex and trochlear groove. ACL = anterior cruciate ligament, ALB = anterolateral bundle, aMFL = anterior meniscofemoral ligament, and PMB = posteromedial bundle.

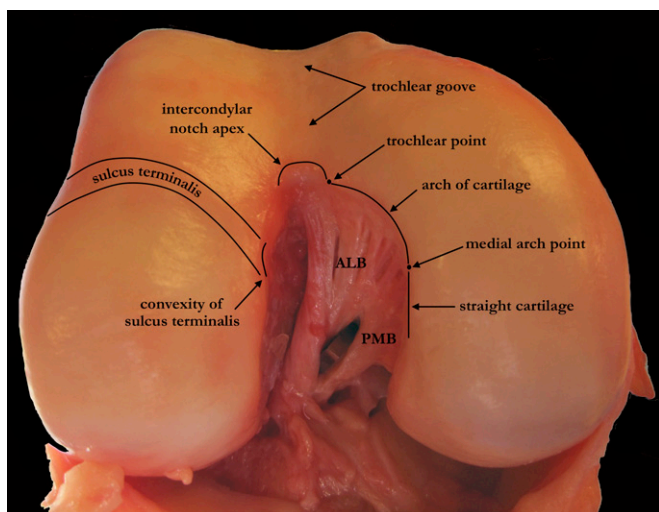


Fig. 2
Anterior photograph of a right knee flexed to 90° with a probe (from posterior) separating the anterolateral bundle (ALB) and posteromedial bundle (PMB) of the PCL and demonstrating the landmarks surrounding the trochlear and medial arch points along the cartilage margin of the femoral intercondylar notch.

Finally, the proximal end of the femur and the distal end of the tibia were potted to provide secure fixation during the measurement process.

Quantitative Anatomic Measurements

The Liberty electromagnetic tracking system (Polhemus, Colchester, Vermont) was used to perform quantitative measurements. Three-dimensional positional

data were collected with use of a calibrated stylus that sensed its position relative to an electromagnetic field produced by the transmitter. Following secure fixation of the specimen to the testing apparatus, the PCL bundles, the anterior meniscofemoral ligament, and the posterior meniscofemoral ligament were sharply dissected from their attachments. The outline of each attachment site was immediately recorded with the stylus. Then, distances were measured between the center of the fiber bundles and the anatomic landmarks. All dissections were performed with the senior author (R.F.L.) present, and all reported measurements were performed by the same individual to decrease interobserver variability.

The MotionMonitor software package (version 8, Innovative Sports Training, Chicago, Illinois) ran the Polhemus system during the data-collection process and exported the distances between landmarks and the three-dimensional coordinates of the outlines of the traced structures. Areas of traced structures were calculated from the coordinate files of the tracing and are reported as the area of the three-dimensional surface. Angular differences between structures were calculated from normal vectors of the planes representing the structures.

Validation

To assess the accuracy of the electromagnetic tracking system, a calibration device with a fixed linear distance accurate to within 0.074 mm and a circular area accurate to within 0.000028 mm² was utilized. This calibration device was precisely fabricated with a vertical endmill and lathe equipped with a highly accurate digital readout system (Sharp Industries, Torrance, California, and Mitutoyo America, Aurora, Illinois). Measurement error for the Polhemus system was calculated from twenty repeated measurements performed by two separate observers using this device. In order to establish the interobserver reproducibility of the measurements between the anatomic landmarks and the center of the fiber bundles, five of the cadaveric specimens were completely remeasured by a second observer, and average-measure interobserver interclass correlation coefficients (ICCs) were calculated (SPSS, version 18; SPSS, Chicago, Illinois) on the basis of the repeated measurements.

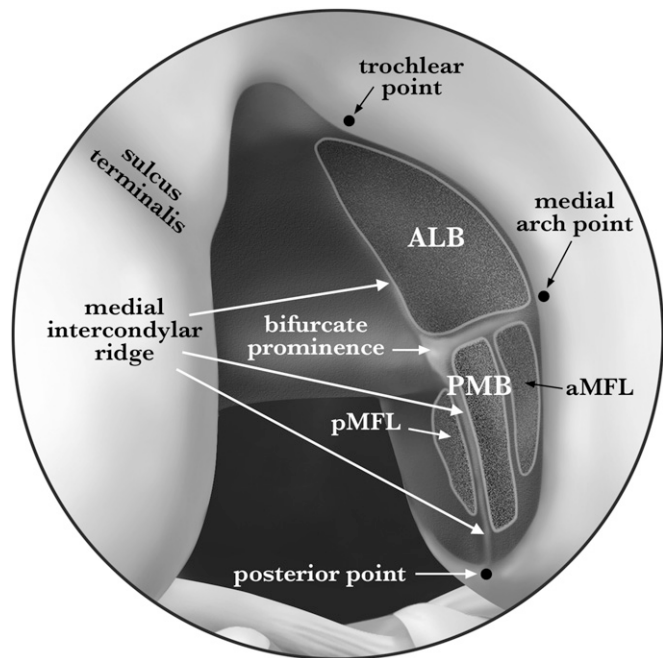


Fig. 3-A
Fig. 3-A Illustration of the arthroscopic view of the femoral attachment of the PCL in a right knee, demonstrating pertinent landmarks. ALB = anterolateral bundle, aMFL = anterior meniscofemoral ligament, PMB = posteromedial bundle, and pMFL = posterior meniscofemoral ligament.

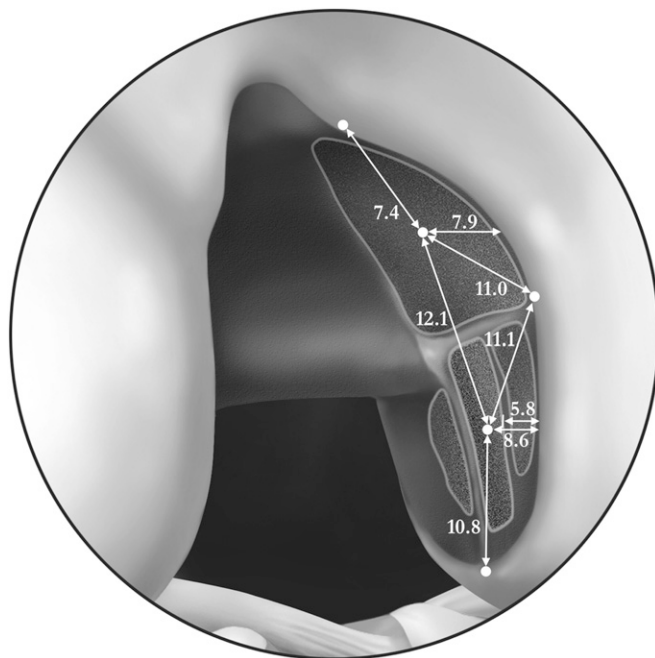


Fig. 3-B
Fig. 3-B Illustration showing the quantitative measurements for the femoral attachment of the PCL. The values are reported in millimeters.

Source of Funding

This study was funded through a postdoctoral fellowship funded by the Norwegian South-East Regional Health Authority and by the Steadman Philippon Research Institute. The funds were used for salaries, supplies, and cadaveric specimens. The Steadman Philippon Research Institute is a 501(c)(3) nonprofit institution supported financially by private donations and corporate support from the following entities: Smith & Nephew Endoscopy, Arthrex, Siemens Medical Solutions USA, OrthoRehab, ConMed Linvatec, Össur Americas, Small Bone Innovations, and Opedix. One or more of the authors are paid/unpaid consultants for Arthrex.

Results

Morphology of the Distal Articular Cartilage Margin of the Femoral Intercondylar Notch

Qualitative analysis of the femoral bone specimens revealed a consistent pattern of the shape of the distal articular cartilage margin of the intercondylar notch. In correlating these osseous landmarks on the femoral bone specimens to the fresh cadavers, three distinct points along this margin were identified where the slope of the cartilage margin immediately changed direction in a consistent and definable manner: the trochlear, medial arch, and posterior points (Figs. 1 and 2). On the lateral side of the intercondylar notch, the intersection of the sulcus terminalis with the cartilage edge created a convexity. Anterior to this convexity, the articular cartilage edge formed the apex of the intercondylar notch, which was the most anterior extent of the notch. This apex was centered on the trochlear groove, on the lateral side of the midline. On the medial side of the apex, a point was consistently found where the cartilage abruptly turned medially, which we termed the “trochlear point” (Figs. 1 and 2). The cartilage margin continued posteromedially in a smooth arch. At the end of this arch, there was a point along the medial wall of the notch where the cartilage became oriented straight posteriorly. We termed this point the “medial arch point.” Continuing along the articular cartilage edge, the most posterior extent of the cartilage margin of the medial femoral condyle was termed the “posterior point” (Fig. 3-A).

Osseous Morphology of the Roof and Walls of the Femoral Intercondylar Notch

Qualitative analysis of the femora revealed that the roof and walls of the intercondylar notch had a consistent morphology that was related to the attachments of the anterolateral and posteromedial bundles (Fig. 3-A). The previously described medial intercondylar ridge²⁶ was found in all specimens. This ridge was found to constitute the proximal borders of both the anterolateral and posteromedial bundles in every specimen. On the wall of the medial femoral condyle, where it marked the proximal border of the posteromedial bundle, this ridge was oriented directly in the anteroposterior plane as it extended anteriorly from the posterior point of the articular cartilage (Figs. 3-A and 4). The medial intercondylar ridge then continued across the roof of the intercondylar notch, where it marked the proximal border of the anterolateral bundle (Figs. 3-A and 4). The medial bifurcate ridge has been previously reported to mark the separation between the anterolateral and

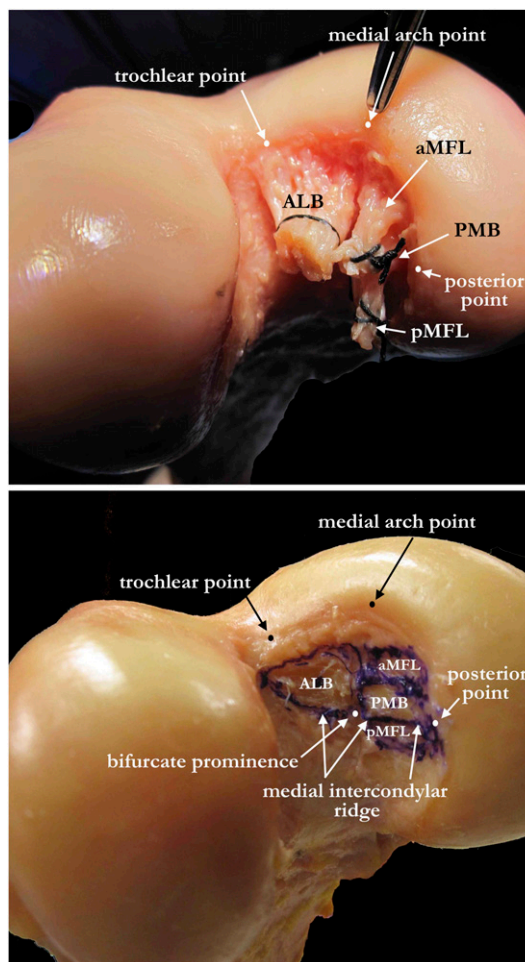


Fig. 4
Photographs showing the femoral attachment of the PCL in a right knee with the fibers intact (top) and sharply dissected (bottom). ALB = anterolateral bundle, aMFL = anterior meniscofemoral ligament, PMB = posteromedial bundle, and pMFL = posterior meniscofemoral ligament.

posteromedial bundles²⁶. We identified a medial bifurcate ridge between the anterolateral and posteromedial bundles in only three specimens. However, in every specimen, there was a palpable and visible osseous prominence, previously not described, that was positioned adjacent to the medial intercondylar ridge at the separation of the anterolateral and posteromedial bundles; we termed this structure the “medial bifurcate prominence” (Fig. 3-A).

Femoral Attachment of the PCL

Quantitative data on the femoral attachment of the anterolateral and posteromedial bundles are reported in Table I. While there was minor variability in the sizes of the footprints of the anterolateral and posteromedial bundles, the described landmarks were found to consistently reflect the borders of the footprint of each bundle in every specimen. Qualitatively, the center of the anterolateral bundle could be triangulated between the trochlear point, the medial arch point, and the

TABLE I Quantitative Data on the Femoral Attachment of the PCL

Area* (mm^2)	
PCL	192 (80 to 302)
Anterolateral bundle	112 (55 to 151)
Posteromedial bundle	60 (28 to 135)
Anterior menisiofemoral ligament	35 (14 to 66)
Posterior menisiofemoral ligament	31 (15 to 72)
Distance between landmarks† (mm)	
Anterolateral bundle center	
To posteromedial bundle	12.1 ± 1.3
To trochlear point	7.4 ± 1.2
To medial arch point	11.0 ± 2.4
To posterior point	21.3 ± 2.4
To articular cartilage distally	7.9 ± 1.5
Posteromedial bundle center	
To trochlear point	18.8 ± 2.0
To medial arch point	11.1 ± 1.9
To posterior point	10.8 ± 2.0
To articular cartilage distally	8.6 ± 1.9
Articular cartilage	
To distal edge of anterolateral bundle	1.5 ± 0.8
To distal edge of posteromedial bundle	5.8 ± 1.7
Angle between anterolateral and posteromedial bundles† (deg)	39.4 ± 13.2

*The values are given as the mean, with the range in parentheses.

†The values are given as the mean and the standard deviation.

medial bifurcate prominence (Fig. 3-A). The mean distance (and standard deviation) between the centers of the anterolateral and posteromedial bundles was 12.1 ± 1.3 mm (Fig. 3-B). The center of the anterolateral bundle was a mean of 7.4 ± 1.2 mm from the trochlear point and 11.0 ± 2.4 mm from the medial arch point. The mean distance from the center of the anterolateral bundle to the articular cartilage distally, parallel to the long axis of the femur, was 7.9 ± 1.5 mm. Along this same line, the distal edge of the anterolateral bundle fibers was 1.5 ± 0.8 mm proximal to the articular cartilage margin.

The posteromedial bundle femoral attachment was more variable in shape and size than the anterolateral bundle femoral attachment was. The posteromedial bundle was consistently bordered by the medial intercondylar ridge proximally and the anterolateral bundle anteriorly. The distal border was usually shared with the anterior menisiofemoral ligament, if present. The posteromedial bundle was a mean of 11.1 ± 1.9 mm from the medial arch point and 10.8 ± 2.0 mm from the posterior point (Fig. 3-B). The mean distance from the center of the posteromedial bundle to the articular cartilage distally, parallel to the long axis of the femur, was 8.6 ± 1.9 mm. Along this same line, the distal edge of the posteromedial bundle fibers was a mean of 5.8 ± 1.7 mm proximal to the articular cartilage margin.

Tibial Attachment of the PCL

Quantitative data on the tibial attachment of the PCL as well as the anterolateral and posteromedial bundles are reported in Table II. The tibial attachment of the PCL was located below the articular surface of the tibia in a sulcus between two osseous prominences, which were the posterior aspects of the medial and lateral tibial plateaus. This sulcus has been termed the PCL facet (Fig. 5)²⁷. Similar to how the anteromedial bundle of the ACL has been reported to envelop the posterolateral bundle at its tibial attachment²⁵, the posteromedial bundle enveloped the medial and posterior sides of the anterolateral bundle, giving the posteromedial bundle footprint the appearance of having two arms (Fig. 6). However, the thickest portion of the posteromedial bundle was located posteromedial to the anterolateral bundle, which was where the functional center of the bundle was defined (Fig. 6). The lateral posteromedial bundle fibers that were located posterior to the anterolateral bundle along the bundle ridge, analogous to the previously described “posterior-oblique” PCL fibers²⁸, were markedly thinner than the rest of the bundle.

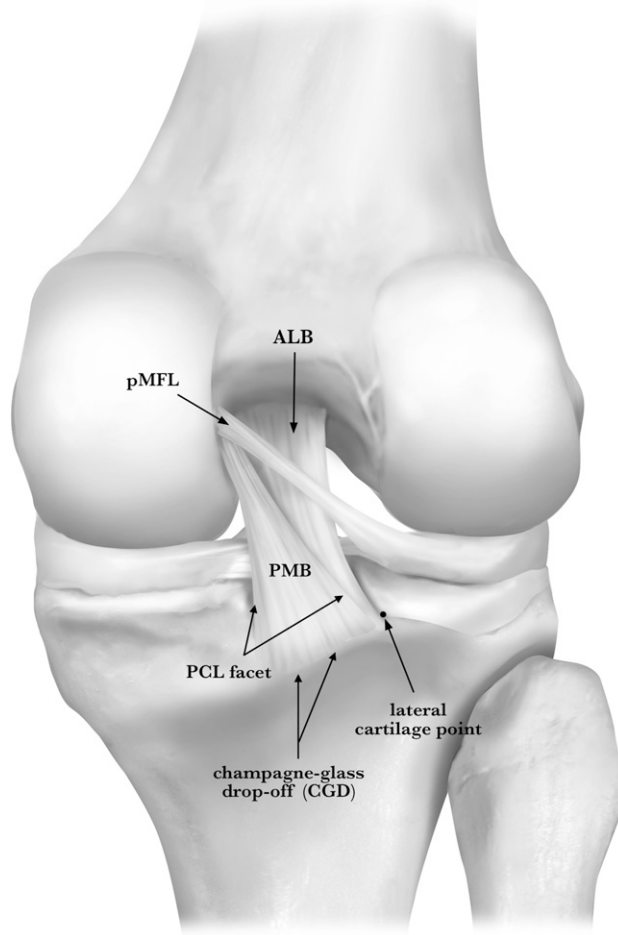


Fig. 5
Illustration of the posterior aspect of a right knee with the PCL intact, demonstrating the fiber orientation. ALB = anterolateral bundle, PMB = posteromedial bundle, and pMFL = posterior menisiofemoral ligament.

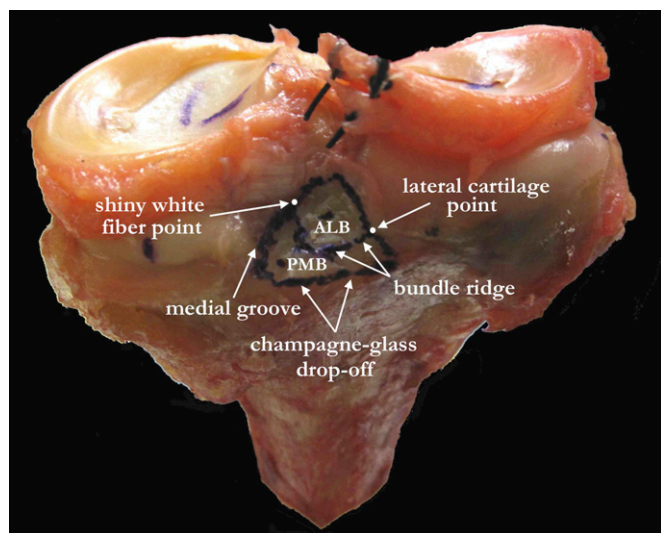


Fig. 6
Posterosuperior photograph of the tibial attachment of the PCL in a right knee. ALB = anterolateral bundle, and PMB = posteromedial bundle.

When viewed from an arthroscopic perspective, the PCL tibial footprint was divided into two planes by a horizontal ridge of bone. This ridge was termed the “bundle ridge” because it occurred along the separation between the anterolateral and posteromedial bundles (Fig. 7-A). At the lateral limit of the bundle ridge, the articular cartilage of the lateral tibial plateau exhibited an abrupt distolateral turn, termed the “lateral cartilage point” (Figs. 5 through 8). The lateral cartilage point was readily visible arthroscopically (Figs. 7-A, 7-B, and 8). The bundle ridge extended medially to the medial limit of the

posterior border of the anterolateral bundle and did not extend through the attachment of the medial fibers of the posteromedial bundle. The shiny white fibers of the posterior horn of the medial meniscus were positioned anteromedial to the anterolateral bundle (Figs. 6 and 7-A). These transversely oriented fibers, located distal to the posterior root attachment fibers of the posterior horn of the medial meniscus, were one of the most notable landmarks in the PCL facet because of their brilliant-white arthroscopic appearance (Fig. 8). The distolateral corner of these fibers was termed the “shiny white fiber point.” The medial side of the PCL was bordered by the osseous wall descending distal to the medial tibial plateau articular surface. At the distal base of this wall, the medial edge of the posteromedial bundle footprint consistently coincided with a groove oriented in the anteroposterior direction, termed the “medial groove” (Fig. 7-A). The distal border of the PCL is often described relative to the prominent ridge at the most posterior aspect of the tibial plateau²⁷. This ridge has been termed the “champagne-glass drop-off” on the basis of its lateral radiographic and anatomic appearance²⁷. This ridge coincides with the inferior attachment of the joint capsule, below which the popliteus muscle fibers can be found arthroscopically when the capsule is punctured (Fig. 8). The champagne-glass drop-off was a useful arthroscopic landmark because it consistently marked the distal border of the posteromedial bundle of the PCL.

The center of the overall PCL tibial attachment was a mean of 7.8 ± 1.4 mm from the shiny white fiber point, 9.8 ± 1.6 mm from the lateral cartilage point, 5.0 ± 0.9 mm from the medial groove, and 1.3 ± 0.5 mm proximal to the bundle ridge (Fig. 7-B). The mean distance between the centers of the anterolateral and posteromedial bundles was 8.9 ± 1.2 mm. The

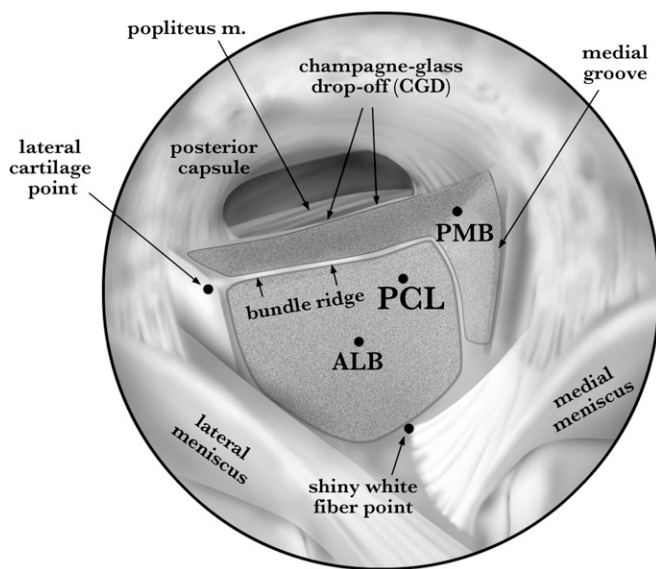


Fig. 7-A

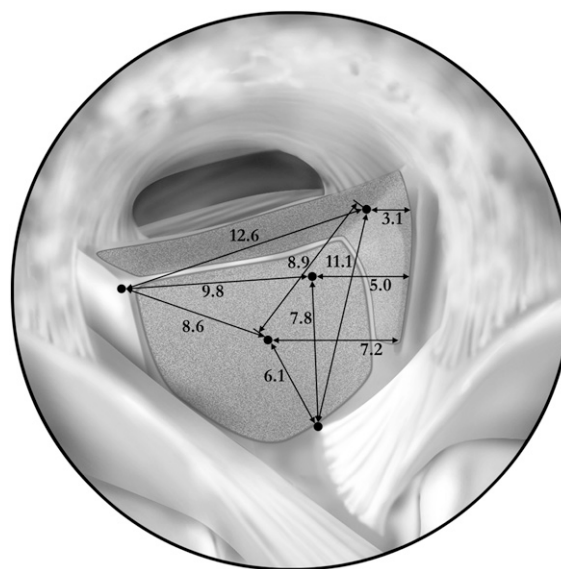


Fig. 7-B

Fig. 7-A Illustration of the arthroscopic view of the tibial attachment of the PCL of a right knee, demonstrating the pertinent landmarks. ALB = anterolateral bundle, PMB = posteromedial bundle, and m = muscle. **Fig. 7-B** Illustration showing the quantitative measurements for the tibial attachment of the PCL. The values are reported in millimeters.

TABLE II Quantitative Data on the Tibial Attachment of the PCL

Area* (mm^2)	
PCL facet	281 (159 to 398)
PCL	219 (108 to 351)
Anterolateral bundle	88 (43 to 122)
Posteromedial bundle	105 (45 to 226)
Distance between landmarks† (mm)	
PCL center	
To shiny white fiber point	7.8 ± 1.4
To lateral cartilage point	9.8 ± 1.6
Horizontally to medial groove	5.0 ± 0.9
To champagne-glass drop-off	7.4 ± 1.2
Inferiorly to bundle ridge	1.3 ± 0.5
Anterolateral bundle center	
To posteromedial bundle	8.9 ± 1.2
To shiny white fiber point	6.1 ± 1.0
To lateral cartilage point	8.6 ± 1.6
Horizontally to medial groove	7.2 ± 1.1
To champagne-glass drop-off	10.7 ± 2.0
Inferiorly to bundle ridge	4.9 ± 0.9
Posteromedial bundle center	
To shiny white fiber point	11.1 ± 1.8
To lateral cartilage point	12.6 ± 1.7
Horizontally to medial groove	3.1 ± 1.1
To champagne-glass drop-off	4.4 ± 0.8
Angle† (deg)	
Between anterolateral and posteromedial bundles	31.5 ± 11.0
Between tibial plateau and PCL facet	44.9 ± 7.0

*The values are given as the mean, with the range in parentheses.

†The values are given as the mean and the standard deviation.

center of the anterolateral bundle was a mean of 6.1 ± 1.0 mm from the shiny white fiber point, 8.6 ± 1.6 mm from the lateral cartilage point, 7.2 ± 1.1 mm from the medial groove, and 4.9 ± 0.9 mm from the bundle ridge. The center of the posteromedial bundle was a mean of 11.1 ± 1.8 mm from the shiny white fiber point, 12.6 ± 1.7 mm from the lateral cartilage point, and 3.1 ± 1.1 cm lateral to the medial groove.

Menisiofemoral Ligaments

At least one menisiofemoral ligament was present in nineteen (95%) of the twenty knees. The anterior menisiofemoral ligament was present in fifteen (75%) of the twenty knees, and the posterior menisiofemoral ligament was present in sixteen (80%) of the twenty knees. Both menisiofemoral ligaments were present in twelve (60%) of the twenty knees. The most common arrangement of the femoral footprints of the menisiofemoral ligaments, found in ten of the twelve of knees with both menisiofemoral ligaments, was with the posterior menisiofemoral ligament, posteromedial bundle, and anterior menisiofemoral ligament aligned parallel to each other, prox-

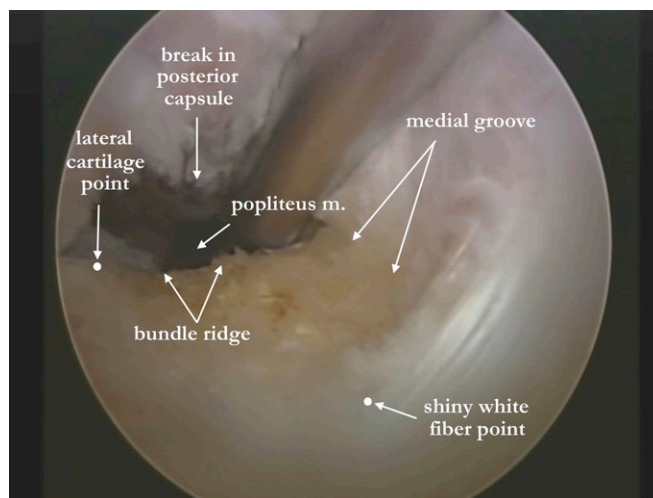


Fig. 8

Arthroscopic view of the tibial attachment of the PCL in a right knee, demonstrating the shiny white fibers, bundle ridge, lateral cartilage point, medial groove, and popliteus muscle fibers. m = muscle.

imally to distally (Figs. 3-A and 4). The posterior menisiofemoral ligaments of all specimens were located directly proximal to the medial intercondylar ridge, proximal to the posteromedial bundle. In twelve of fifteen specimens, the anterior menisiofemoral ligament was distal to the posteromedial bundle. The anterior menisiofemoral ligament was located distal to the anterolateral bundle fibers in only three of fifteen specimens. In three of the five specimens in which the anterior menisiofemoral ligament was absent, the posteromedial bundle footprint extended distally to the articular cartilage margin.

Validation Analysis

The error of the electromagnetic tracking system was calculated to be 0.64% and 0.51% for the measurement of the fixed linear distance and the known circular area, respectively. The interobserver ICC for the repeated measurements on five of the cadaveric specimens by the two separate observers was 0.995.

Discussion

We found that the locations of the PCL attachments on the femur and tibia could be accurately described relative to arthroscopically pertinent landmarks surrounding the attachment sites. The center of the femoral anterolateral bundle tunnel should be triangulated on the basis of the trochlear point, the medial arch point, and the medial bifurcate prominence, with the distal edge placed adjacent to the articular cartilage. The femoral posteromedial bundle tunnel should be placed equidistant from the posterior point and the medial arch point and placed just distal to the medial intercondylar ridge, with the center an average of 8.6 mm proximal to the articular cartilage margin. The center of a single PCL tunnel on the tibia should be placed just anterosuperior to the bundle ridge, on the medial side of the PCL facet and 9.8 mm from the lateral cartilage point and 5.0 mm from the medial groove.

Previous measurements of the femoral attachment of the PCL have often been reported on the basis of lateral views with the lateral femoral condyle removed^{26,29-32}. However, these measurements have limited arthroscopic applicability because they do not adequately illustrate the substantial attachment of the anterolateral bundle on the roof of the intercondylar notch. The anatomic descriptions in the present study are reported from an arthroscopic perspective. The positions of the anterolateral and posteromedial bundles have been previously reported with respect to an arthroscopic view of the knee³³. However, we found the center of the anterolateral bundle to be more distal, located at a mean of 7.9 mm proximal to the cartilage edge, rather than the 13 mm previously reported³³. Furthermore, our finding that the center of the anterolateral bundle was 7.9 mm proximal to the articular cartilage is consistent with other anatomic studies^{26,29,31,32}. Likewise, our finding that the center of the posteromedial bundle was 8.6 mm from the cartilage edge is also consistent with previous studies^{26,32,33}. Measurements between the distal edge of the PCL fibers and the articular cartilage have been previously reported parallel to the notch roof²⁹. We report the distance between the distal edge of the PCL fibers and the articular cartilage parallel to the long axis of the femur because it is more arthroscopically applicable. We found that the anterolateral bundle fibers were only 1.5 mm proximal to the cartilage margin. Because it has been previously reported that distal femoral tunnel placement results in improved stability against posterior translation than more proximal tunnel placement does^{17,23} and also that errors in tunnel placement in the proximal-distal direction affect knee stability greater than in other directions²³, we recommend that the distal edge of an anterolateral bundle reconstruction tunnel be placed adjacent to the cartilage as the graft fibers will be displaced away from the cartilage with graft tensioning. An oblique tunnel orientation, rather than a horizontal tunnel orientation, is necessary to avoid violating the subchondral bone, which could lead to osteonecrosis or an insufficiency fracture. Unlike the anterolateral bundle femoral attachment, which was adjacent to the articular cartilage margin, the anterior margin of the posteromedial bundle fibers was located 5.8 mm proximal to the cartilage margin. Thus, a femoral reconstruction tunnel of the posteromedial bundle should be placed more proximal from the articular cartilage margin to replicate its anatomic position.

The medial intercondylar ridge and the medial bifurcate ridge are recently reported structures related to the positions of the anterolateral and posteromedial bundles on the femur²⁶. We found that the medial intercondylar ridge was located on the medial wall of the notch, extending anteriorly from the posterior point, and that it consistently marked the proximal borders of the posteromedial and anterolateral bundles. As the medial bifurcate ridge was present in only 15% of specimens, its use as an arthroscopic landmark may be limited. However, as the medial bifurcate prominence was found in all specimens, this landmark should be sought to identify the posteroproximal end of the border between the anterolateral and posteromedial bundles.

Quantitative results are not reported in relation to an estimated center of the PCL on the femur because the attachment was so broad that center localization was not consistently practical. Furthermore, we do not believe that it would be feasible to place one reconstruction tunnel centered on the PCL attachment on the femur without excluding a substantial portion of the anterolateral bundle fibers or potentially damaging the menisofemoral ligaments positioned in close proximity to the posteromedial bundle. With an average distance of 12.1 mm between the anterolateral and posteromedial bundles, utilization of an 11-mm-diameter anterolateral bundle tunnel and a 7-mm posteromedial bundle reconstruction tunnel, as reported clinically²⁷, would still allow for a 3-mm bone bridge between the two femoral reconstruction tunnels. As single-bundle reconstructions typically aim to reconstruct the functionally dominant anterolateral bundle, our results for the femoral location of the anterolateral bundle can also be used to guide tunnel placement in single-bundle PCL reconstructions.

The tibial attachment of the PCL was substantially more compact than the femoral attachment. While the tibial attachment of the PCL is often described relative to the prominent ridge at the most posterior aspect of the tibial plateau, termed the champagne-glass drop-off²⁷, few other landmarks have been described³⁴⁻³⁷. A "shelf" positioned through the PCL facet³⁷ as well as a change in slope at the area of the bundle ridge have been previously reported³⁵. These descriptions appear to be consistent with the structure herein described as the bundle ridge. We further describe the nature of this structure in relation to the attachment of the PCL in order to augment its use as a landmark for PCL reconstruction surgery. While the shiny white fibers of the posterior horn of the medial meniscus have been previously recognized to occur anteromedial to the anterolateral bundle³⁷, we are unaware of any previous reports quantifying measurements of this structure. A previously described depression at the superomedial corner of the PCL attachment on the tibia³⁴ may correlate with the anterior aspect of the medial groove that we have described.

Others have reported difficulty in identifying the tibial attachments of the anterolateral and posteromedial bundles because of their close proximity at one insertion area³⁸. We did not find the anterolateral and posteromedial bundles to be readily separable; however, careful dissection along interfasficular connective tissue after the initial separation had been made revealed the consistent shape of the anterolateral bundle and posteromedial bundle tibial footprints as reported in the present study. We found the mean distance between the centers of the anterolateral and posteromedial bundles to be only 8.9 mm. The closer proximity of the anterolateral and posteromedial bundle attachments on the tibia would make it prudent to consider one tibial tunnel for both single and double-bundle PCL reconstructions. In addition, the two-armed shape of the posteromedial bundle could not be reproduced with one round tunnel. As the functional center of the posteromedial bundle fibers was located directly posteromedial to the anterolateral bundle, a well-placed single tibial reconstruction tunnel could encompass this fiber region. Also, as the bundle ridge was only 1.3 mm distal to the overall PCL center, it would be justified to

identify the bundle ridge with a tibial drill guide and then target the guide pin to protrude just proximal to this ridge. Likewise, a PCL inlay graft should also be centered at this site.

We recognize that the present study has some limitations. A limited number of specimens were used, which may not have demonstrated the full spectrum of anatomic variation. However, to our knowledge, this study is one of the largest anatomic studies on the PCL, and the results were consistent between specimens. In addition, we did not specifically vary the order of measurements of the individual PCL bundles, which may have introduced some order bias. Instead, we measured each individual PCL bundle immediately after it was sharply dissected from its attachment location.

The findings of the present study provide qualitative descriptions and quantitative measurements of arthroscopic landmarks for the femoral and tibial attachments of the PCL. The results presented in this study can assist with more anatomic tunnel placement in single and double-bundle PCL reconstructions. The results also suggest that two reconstruction tunnels are needed to reconstruct the broad PCL femoral attachment, whereas one reconstruction tunnel should be investigated further for the compact tibial attachment. ■

Note: The authors thank Steven Hobbs, PhD, from the Department of Integrative Physiology at the University of Colorado at Boulder, for allowing the evaluation of their bone box specimens. They also recognize Kyle Jansson for his mechanical expertise in developing the fixtures and for the high measurement accuracy in this study, and Daniel Westcott, MSc, for his technical assistance with this project.

Colin J. Anderson, MD
Connor G. Ziegler, MD
Coen A. Wijdicks, PhD
Department of BioMedical Engineering,
Steadman Philippon Research Institute,
181 West Meadow Drive, Suite 1000, Vail, Colorado 81657

Lars Engebretsen, MD, PhD
Department of Orthopaedic Surgery,
Oslo University Hospital and Faculty of Medicine,
Kirkeveien 166, 0407 Oslo, Norway

Robert F. LaPrade, MD, PhD
The Steadman Clinic, 181 West Meadow Drive,
Suite 400, Vail, Colorado 81657.
E-mail address: drlaprade@sprivail.org

References

- Fanelli GC, Beck JD, Edson CJ. Current concepts review: the posterior cruciate ligament. *J Knee Surg.* 2010 Jun;23(2):61-72.
- Boynnton MD, Tietjens BR. Long-term followup of the untreated isolated posterior cruciate ligament-deficient knee. *Am J Sports Med.* 1996 May-Jun;24(3):306-10.
- Covey CD, Sapega AA. Injuries of the posterior cruciate ligament. *J Bone Joint Surg Am.* 1993 Sep;75(9):1376-86.
- Dejour H, Walch G, Peyrot J, Eberhard P. [The natural history of rupture of the posterior cruciate ligament]. *Rev Chir Orthop Reparatrice Appar Mot.* 1988;74(1):35-43. French.
- Keller PM, Shelbourne KD, McCarroll JR, Rettig AC. Nonoperatively treated isolated posterior cruciate ligament injuries. *Am J Sports Med.* 1993 Jan-Feb;21(1):132-6.
- Kim SJ, Kim SH, Kim SG, Kung YP. Comparison of the clinical results of three posterior cruciate ligament reconstruction techniques: surgical technique. *J Bone Joint Surg Am.* 2010 Sep;92 Suppl 1 Pt 2:145-57.
- Gill TJ, Van de Velde SK, Wing DW, Oh LS, Hosseini A, Li G. Tibiofemoral and patellofemoral kinematics after reconstruction of an isolated posterior cruciate ligament injury: in vivo analysis during lunge. *Am J Sports Med.* 2009 Dec;37(12):2377-85. Epub 2009 Sep 2.
- Harner CD, Janaushek MA, Kanamori A, Yagi M, Vogrin TM, Woo SL. Biomechanical analysis of a double-bundle posterior cruciate ligament reconstruction. *Am J Sports Med.* 2000 Mar-Apr;28(2):144-51.
- Race A, Amis AA. PCL reconstruction. In vitro biomechanical comparison of 'isometric' versus single and double-bundled 'anatomic' grafts. *J Bone Joint Surg Br.* 1998 Jan;80(1):173-9.
- Wang CJ, Weng LH, Hsu CC, Chan YS. Arthroscopic single- versus double-bundle posterior cruciate ligament reconstructions using hamstring autograft. *Injury.* 2004 Dec;35(12):1293-9.
- Houe T, Jørgensen U. Arthroscopic posterior cruciate ligament reconstruction: one- vs. two-tunnel technique. *Scand J Med Sci Sports.* 2004 Apr;14(2):107-11.
- Hatayama K, Higuchi H, Kimura M, Kobayashi Y, Asagumo H, Takagishi K. A comparison of arthroscopic single- and double-bundle posterior cruciate ligament reconstruction: review of 20 cases. *Am J Orthop (Belle Mead NJ).* 2006 Dec;35(12):568-71.
- Kohen RB, Sekiya JK. Single-bundle versus double-bundle posterior cruciate ligament reconstruction. *Arthroscopy.* 2009 Dec;25(12):1470-7. Epub 2009 Jan 24.
- Kim YM, Lee CA, Matava MJ. Clinical results of arthroscopic single-bundle transtibial posterior cruciate ligament reconstruction: a systematic review. *Am J Sports Med.* 2011 Feb;39(2):425-34. Epub 2010 Aug 11.
- Greiner P, Magnussen RA, Lustig S, Demey G, Neyret P, Servien E. Computed tomography evaluation of the femoral and tibial attachments of the posterior cruciate ligament in vitro. *Knee Surg Sports Traumatol Arthrosc.* 2011 Nov;19(11):1876-83. Epub 2011 Apr 9.
- Apsingi S, Bull AM, Deehan DJ, Amis AA. Review: femoral tunnel placement for PCL reconstruction in relation to the PCL fibre bundle attachments. *Knee Surg Sports Traumatol Arthrosc.* 2009 Jun;17(6):652-9. Epub 2009 Mar 14.
- Galloway MT, Grood ES, Mehalik JN, Levy M, Saddler SC, Noyes FR. Posterior cruciate ligament reconstruction. An in vitro study of femoral and tibial graft placement. *Am J Sports Med.* 1996 Jul-Aug;24(4):437-45.
- Mannor DA, Shearn JT, Grood ES, Noyes FR, Levy MS. Two-bundle posterior cruciate ligament reconstruction. An in vitro analysis of graft placement and tension. *Am J Sports Med.* 2000 Nov-Dec;28(6):833-45.
- McGuire DA, Hendricks SD. Comparison of anatomic versus nonanatomic placement of femoral tunnels in Achilles double-bundle posterior cruciate ligament reconstruction. *Arthroscopy.* 2010 May;26(5):658-66. Epub 2010 Mar 3.
- Petersen W, Tretow H, Weimann A, Herbert M, Fu FH, Raschke M, Zantop T. Biomechanical evaluation of two techniques for double-bundle anterior cruciate ligament reconstruction: one tibial tunnel versus two tibial tunnels. *Am J Sports Med.* 2007 Feb;35(2):228-34. Epub 2006 Nov 12.
- Zantop T, Wellmann M, Fu FH, Petersen W. Tunnel positioning of anteromedial and posterolateral bundles in anatomic anterior cruciate ligament reconstruction: anatomic and radiographic findings. *Am J Sports Med.* 2008 Jan;36(1):65-72. Epub 2007 Oct 11.
- Musahl V, Ayeni OR, Citak M, Irgang JJ, Pearle AD, Wickiewicz TL. The influence of bony morphology on the magnitude of the pivot shift. *Knee Surg Sports Traumatol Arthrosc.* 2010 Sep;18(9):1232-8. Epub 2010 Apr 8.
- Burns WC 2nd, Draganich LF, Pyevich M, Reider B. The effect of femoral tunnel position and graft tensioning technique on posterior laxity of the posterior cruciate ligament-reconstructed knee. *Am J Sports Med.* 1995 Jul-Aug;23(4):424-30.
- Azzam MG, Lenarz CJ, Farrow LD, Israel HA, Kieffer DA, Kaar SG. Inter- and intraobserver reliability of the clock face representation as used to describe the femoral intercondylar notch. *Knee Surg Sports Traumatol Arthrosc.* 2011 Aug;19(8):1265-70. Epub 2011 Jan 22.
- Ziegler CG, Pietrini SD, Westerhaus BD, Anderson CJ, Wijdicks CA, Johansen S, Engebretsen L, LaPrade RF. Arthroscopically pertinent landmarks for tunnel positioning in single-bundle and double-bundle anterior cruciate ligament reconstructions. *Am J Sports Med.* 2011 Apr;39(4):743-52. Epub 2010 Dec 20.
- Lopes OV Jr, Ferretti M, Shen W, Ekdahl M, Smolinski P, Fu FH. Topography of the femoral attachment of the posterior cruciate ligament. *J Bone Joint Surg Am.* 2008 Feb;90(2):249-55.
- Spiridonov SI, Slinkard NJ, LaPrade RF. Isolated and combined grade-III posterior cruciate ligament tears treated with double-bundle reconstruction with use of

endoscopically placed femoral tunnels and grafts: operative technique and clinical outcomes. *J Bone Joint Surg Am.* 2011 Oct 5;93(19):1773-80.

28. Makris CA, Georgoulis AD, Papageorgiou CD, Moebius UG, Soucacos PN. Posterior cruciate ligament architecture: evaluation under microsurgical dissection. *Arthroscopy.* 2000 Sep;16(6):627-32.

29. Takahashi M, Matsubara T, Doi M, Suzuki D, Nagano A. Anatomical study of the femoral and tibial insertions of the anterolateral and posteromedial bundles of human posterior cruciate ligament. *Knee Surg Sports Traumatol Arthrosc.* 2006 Nov;14(11):1055-9. Epub 2006 Aug 4.

30. Saddler SC, Noyes FR, Grood ES, Knochenmuss DR, Hefzy MS. Posterior cruciate ligament anatomy and length-tension behavior of PCL surface fibers. *Am J Knee Surg.* 1996 Fall;9(4):194-9.

31. Mejia EA, Noyes FR, Grood ES. Posterior cruciate ligament femoral insertion site characteristics. Importance for reconstructive procedures. *Am J Sports Med.* 2002 Sep-Oct;30(5):643-51.

32. Edwards A, Bull AM, Amis AA. The attachments of the fiber bundles of the posterior cruciate ligament: an anatomic study. *Arthroscopy.* 2007 Mar;23(3):284-90.

33. Morgan CD, Kalman VR, Grawl DM. The anatomic origin of the posterior cruciate ligament: where is it? Reference landmarks for PCL reconstruction. *Arthroscopy.* 1997 Jun;13(3):325-31.

34. Sheps DM, Otto D, Fernhout M. The anatomic characteristics of the tibial insertion of the posterior cruciate ligament. *Arthroscopy.* 2005 Jul;21(7):820-5.

35. Tajima G, Nozaki M, Iriuchishima T, Ingham SJ, Shen W, Smolinski P, Fu FH. Morphology of the tibial insertion of the posterior cruciate ligament. *J Bone Joint Surg Am.* 2009 Apr;91(4):859-66.

36. Ramos LA, de Carvalho RT, Cohen M, Abdalla RJ. Anatomic relation between the posterior cruciate ligament and the joint capsule. *Arthroscopy.* 2008 Dec;24(12):1367-72.

37. Amis AA, Gupte CM, Bull AM, Edwards A. Anatomy of the posterior cruciate ligament and the meniscofemoral ligaments. *Knee Surg Sports Traumatol Arthrosc.* 2006 Mar;14(3):257-63. Epub 2005 Oct 14.

38. Lorenz S, Elser F, Brucker PU, Obst T, Imhoff AB. Radiological evaluation of the anterolateral and posteromedial bundle insertion sites of the posterior cruciate ligament. *Knee Surg Sports Traumatol Arthrosc.* 2009 Jun;17(6):683-90. Epub 2009 Mar 24.