

# The Anterior Intermeniscal Ligament of the Knee

## An Anatomic Study\*

Eric W. Nelson, MD, and Robert F. LaPrade,† MD

*From the Department of Orthopaedic Surgery, University of Minnesota, Minneapolis, Minnesota*

### ABSTRACT

The purpose of this study was to identify the presence of the anterior intermeniscal ligament of the knee and to study its attachment patterns and relationships to other anatomic structures within the knee. Fifty unpaired cadaveric knees were dissected. An identifiably distinct anterior intermeniscal ligament was found in 47 specimens (94%). The average length was 33 mm and the average midsubstance width was 3.3 mm. The average perpendicular distance from the anterior intermeniscal ligament to the anterior margin of the tibial insertion of the anterior cruciate ligament was 7.8 mm (range, 2.0 to 13.5). The anterior intermeniscal ligament was the primary attachment for the anterior horn of the medial meniscus in 12 knees (24%); 7 knees (14%) had no tibial insertion and 5 knees (10%) had only a fine fascial tibial connection. Successful arthroscopic evaluation, surgical repair, and meniscal allograft reconstruction can be enhanced by a precise knowledge of the anterior intermeniscal ligament anatomy, especially when identifying the various insertion patterns of the anterior horn of the medial meniscus. A correct understanding of these patterns is helpful for avoiding patient injury during surgical procedures (particularly arthroscopic ACL reconstructions) performed in close proximity to the anterior intermeniscal ligament of the knee.

The anterior intermeniscal ligament of the knee (also called the transverse geniculate ligament or anterior

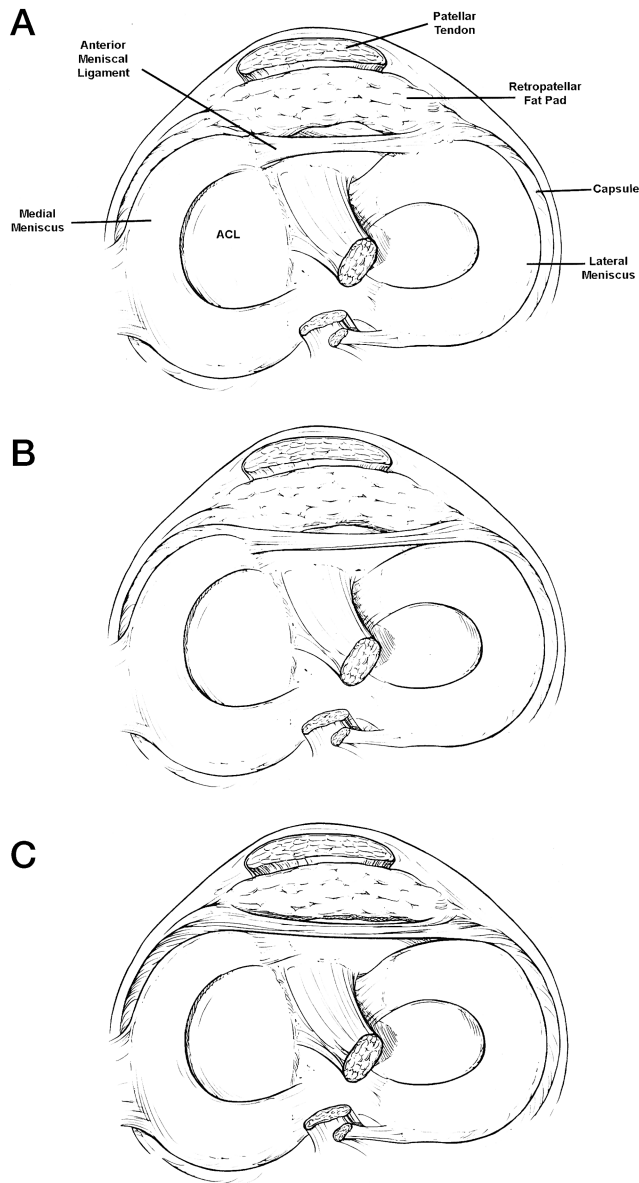
transverse ligament) is described in *Gray's Anatomy*<sup>6</sup> as "connecting the anterior convex margin of the lateral meniscus to the anterior end of the medial meniscus." Although its function is not known, recent interest in this structure has been driven by the radiographic appearance of the anterior intermeniscal ligament on both MRI scans and plain lateral knee radiographs. Watanabe et al.<sup>7</sup> reviewed 200 sagittal MRI knee scans and found that 22% (44 patients) had a high-intensity signal near the anterior horn of the lateral meniscus. This was suggestive of a lateral meniscus tear. Nine of these 44 patients underwent knee arthroscopy and none were found to have a torn meniscus. Sintzoff et al.<sup>4</sup> reported a series of four patients in whom the anterior intermeniscal ligament was visualized on plain lateral knee radiographs. Subsequent MRI scans showed the ligament to be surrounded by fat in each case. In a second study,<sup>5</sup> they examined 50 knees both with MRI and plain lateral knee radiographs and found that the anterior intermeniscal ligament could be visualized on 12% of radiographs and 58% of MRI scans. In an anatomic study by Kohn and Moreno,<sup>2</sup> 46 paired knee dissections were performed to investigate meniscal insertion patterns as a basis for meniscus transplantation. They identified the anterior intermeniscal ligament in 69% of their specimens. Berlet and Fowler,<sup>1</sup> also investigating medial meniscal insertion patterns, found the anterior intermeniscal ligament in 24 of 34 cadaveric specimens (71%). Ohkoshi et al.<sup>3</sup> reported on variations of the insertion of the anterior horn of the medial meniscus in 953 knee arthroscopies. They found that approximately 10% of patients had an unusual insertion pattern for the anterior horn of the medial meniscus, with half of these patients having a meniscal insertion directly to the anterior intermeniscal ligament.

We concluded from the research thus far that no anatomic study had specifically reflected the occurrence of this structure or defined its insertion patterns beyond

\* Presented at the 25th annual meeting of the AOSSM, Traverse City, Michigan, June 1999.

† Address correspondence and reprint requests to Robert F. LaPrade, MD, Department of Orthopaedic Surgery, University of Minnesota, Box 492 UMHC, 420 Delaware Street, SE, Minneapolis, MN 55455.

No author or related institution has received any financial benefit from research in this study.



**Figure 1.** The three types of insertion patterns of the anterior intermeniscal ligament of the knee. A, type I has attachments to the anterior horn of the medial meniscus and anterior margin of the lateral meniscus. B, type II has medial attachment to the anterior margin of the medial meniscus and lateral attachment to the joint capsule anterior to lateral meniscus. C, type III has medial and lateral capsular anterior attachments only, with no direct attachments to the anterior horn of the medial meniscus or to the lateral meniscus.

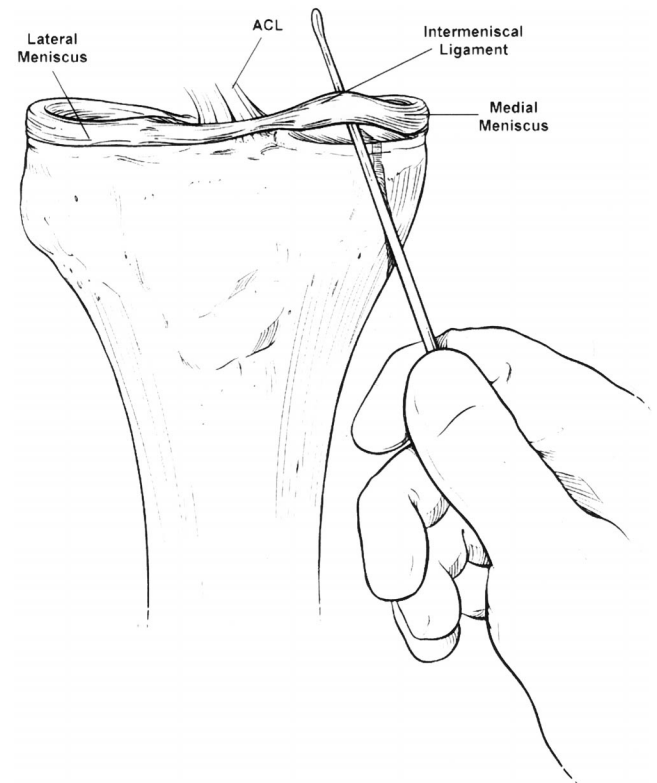
those found in *Gray's Anatomy*.<sup>6</sup> Therefore, we set out to identify the occurrence of the intermeniscal ligament and to describe its patterns of attachment and its relationships to other knee structures, such as the retropatellar fat pad and ACL. This information should serve as the basis for future biomechanical studies on the function of the anterior intermeniscal ligament.

## MATERIALS AND METHODS

Specimens consisted of 50 formalin-preserved cadaveric knees with an average age of 76 years (range, 43 to 96); 22 were from male donors and 28 from female donors. The specimens were first transected through the distal patella, exposing the distal femoral condyles. The condyles were circumferentially detached from their soft tissue attachments and removed, exposing the tibial plateau. The anterior intermeniscal ligament, if present, was then identified, either within or overhung by the retropatellar fat pad. Its attachment sites were identified and recorded. The length and width of the anterior intermeniscal ligament as well as its relationship to the medial and lateral menisci and cruciate ligaments were also recorded. All dissections were performed in a systematic fashion and data were recorded on a standardized collection sheet.

## RESULTS

In 47 specimens (94%), a distinct anterior intermeniscal ligament was identified, either within or overhung by the retropatellar fat pad. The average length of the ligament was 33.0 mm (range, 23 to 42), the average midsubstance width was 3.3 mm (range, 2 to 5), the average distance from the anterior margin of the ACL at its tibial insertion



**Figure 2.** Frontal view of type I variant with no tibial insertion for the anterior horn of the medial meniscus. The sole attachment for the anterior horn of the medial meniscus was to the anterior intermeniscal ligament.

to the anterior intermeniscal ligament was 7.8 mm (range, 2 to 13.5), and the average distance from the anterior margin of the tibial PCL insertion was 27.5 mm (range, 20 to 43).

Three different attachment patterns of the anterior intermeniscal ligament were found. The type I pattern was most common (23 specimens, 46%) and fit the classic description<sup>6</sup> of primary attachments directly to the anterior horn of the medial meniscus and the anterior margin of the lateral meniscus (Fig. 1A). Type II pattern ligaments were the next most common (13 specimens, 26%). In the type II pattern, the anterior intermeniscal ligament attached medially to the most-anterior margin of the medial meniscus and attached laterally to the joint capsule anterior to the lateral meniscus (Fig. 1B). The type III attachment pattern consisted of two types, with the main attachment points, both medially and laterally, of the anterior intermeniscal ligament to the anterior capsule. Six knees (12%) had attachments to the anterior capsule only, with no meniscal insertions (Fig. 1C) and a further 5 knees (10%) had an additional fine fascial attachment on both anterior meniscal margins.

Of particular interest were seven knees (14% of specimens) in which the anterior intermeniscal ligament served as the sole attachment for the anterior horn of the medial meniscus (Fig. 2). An additional 10% of specimens (5 knees) had a similar anterior intermeniscal ligament attachment pattern to the anterior horn of the medial meniscus, with only a very fine fascial connection from the anterior horn of the medial meniscus to the medial tibial plateau. Thus, in 24% of the specimens the anterior intermeniscal ligament served as the primary anchor for the anterior horn of the medial meniscus. All of these knees had a type I anterior intermeniscal ligament attachment.

## DISCUSSION

The number of knees with the anterior intermeniscal ligament in this study was much greater than previously reported.<sup>1,2</sup> We found the ligament in 47 of 50 knees (94%). To our knowledge, no other studies have focused specifically on the anatomy of the anterior intermeniscal ligament. The findings of our study reinforce those of Berlet and Fowler<sup>1</sup> in that the anterior intermeniscal ligament was invariably found within or overhung by the retropatellar fat pad.

In this study, the anterior intermeniscal ligament was frequently identified in a more anterior location than described in *Gray's Anatomy*.<sup>6</sup> Three different types of attachment patterns of the anterior intermeniscal ligament were identified. Although the most common attachment pattern found was that classically described<sup>6</sup> (Fig. 1A), it accounted for only approximately one-third of the specimens, leaving the majority of specimens with alternate attachment patterns.

Since we did not perform any biomechanical tests, we can only speculate that the anterior intermeniscal ligament could act as a significant stabilizer of the anterior horn of the medial meniscus, particularly in the subset of specimens where it acts as the main anchor for the anterior horn of the medial meniscus (24% in this study). However, we did observe that once the anterior intermeniscal ligament was disrupted in these specimens, the anterior horn of the medial meniscus tended to retract medially and distally over the proximal anterior tibia. This variant appears to correspond to the type IV medial meniscal insertion pattern described by Berlet and Fowler.<sup>1</sup> Whether this variant makes the medial meniscus more resistant to tearing because of increased translation with motion or implicates it in anterior knee pain, as proposed by Berlet and Fowler,<sup>1</sup> remains to be determined. However, this variant is significant for the subset of patients who have no bony attachment for the anterior horn of the meniscus. Should meniscus transplantation be considered, the problem of meniscal allograft fixation is raised. It is important to recognize this meniscal insertion pattern in patients receiving medial meniscal allografts, so that proper reattachment and stabilization of the allograft can be performed.

Finally, as reflected by its location less than 8 mm from the anterior aspect of the ACL attachment on the tibia, the anterior intermeniscal ligament may be at risk during procedures such as debridement for tibial tunnel preparation during ACL reconstruction. Although the consequences of injury to the anterior intermeniscal ligament are unknown, we recommend avoiding injury to this structure during any procedures that could place it at risk.

## ACKNOWLEDGMENTS

The authors express their appreciation to David Lee and to the Anatomy Bequest Program of the Department of Anatomy at the University of Minnesota for the specimens used in this study.

## REFERENCES

- Berlet GC, Fowler PJ: The anterior horn of the medial meniscus. An anatomic study of its insertion. *Am J Sports Med* 26: 540-543, 1998
- Kohn D, Moreno B: Meniscus insertion anatomy as a basis for meniscus replacement: A morphological cadaveric study. *Arthroscopy* 11: 96-103, 1995
- Ohkoshi Y, Takeuchi T, Inoue C, et al: Arthroscopic studies of variants of the anterior horn of the medial meniscus. *Arthroscopy* 13: 725-730, 1997
- Sintzoff SA Jr, Gevenois PA, Andrianne Y, et al: Transverse geniculate ligament of the knee: Appearance at plain radiography. *Radiology* 180: 259, 1991
- Sintzoff SA Jr, Stallenberg B, Gillard I, et al: Transverse geniculate ligament of the knee: Appearance and frequency on plain radiographs. *Br J Radiol* 65: 766-768, 1992
- Soames RW: Skeletal system, in *Gray's Anatomy*. Thirty-eighth edition. Edinburgh, Churchill Livingstone, 1995, pp 703-704
- Watanabe AT, Carter BC, Teitelbaum GP, et al: Common pitfalls in magnetic resonance imaging of the knee. *J Bone Joint Surg* 71A: 857-862, 1989