

# The Anatomy of the Deep Infrapatellar Bursa of the Knee

Robert F. LaPrade,\* MD

*Department of Orthopaedic Surgery, University of Minnesota, Minneapolis, Minnesota*

## ABSTRACT

Disorders of the deep infrapatellar bursa are important to include in the differential diagnosis of anterior knee pain. Knowledge regarding its anatomic location can aid the clinician in establishing a proper diagnosis. Fifty cadaveric knees were dissected, and the deep infrapatellar bursa had a consistent anatomic location in all specimens. The deep infrapatellar bursa was located directly posterior to the distal 38% of the patellar tendon, just proximal to its insertion on the tibial tubercle. There was no communication to the knee joint. Its average width at the most proximal margin of the tibial tubercle was slightly wider than the average distal width of the patellar tendon. It was found to be partially compartmentalized, with a fat pad apron extending down from the retropatellar fat pad to partially divide it into anterior and posterior compartments. The recommended approach to this bursa, either for aspiration, injection, or surgery, is along the lateral edge of the patellar tendon just proximal to the tibial tubercle.

Disorders of the deep infrapatellar, or retropatellar, bursa are important to include in the clinical differential diagnosis of anterior knee pain.<sup>7,9,12,15,16</sup> This bursa has been described as a location of calcification,<sup>8</sup> inflammatory bursitis,<sup>1,7</sup> septic bursitis,<sup>5,10,13,15,16</sup> gout,<sup>15</sup> and traumatic hemorrhage<sup>11</sup> and as a possible factor in the infrapatellar contracture syndrome.<sup>9</sup> However, a literature review revealed no precise details about the size, location, or characteristics of this bursa, or whether it had an intraarticular connection to the knee joint. In addition, no surgical approach to this bursa had been described. The purpose of this study was to define the anatomic dimensions of the deep infrapatellar bursa of the knee, to determine whether there was evidence of communication with the

knee joint, and to define a consistent surgical approach to the deep infrapatellar bursa.

## MATERIALS AND METHODS

Thorough dissections of the anterior aspect of the knee of 50 nonpaired cadaveric knees were performed. There were 27 male and 23 female cadaveric knees with 25 right and 25 left knees. The average age of the specimens was 71.8 years (range, 42 to 93). After the skin and subcutaneous tissues of the anterior aspect of the knee were carefully dissected away, an approach to the deep infrapatellar bursa of the knee was made through medial and lateral arthrotomy incisions along the patella, followed by transection of the quadriceps tendon from the patella. The patella and patellar tendon were then retracted distally and the retropatellar fat pad was dissected away meticulously until the edges of the deep infrapatellar bursa were identified. An incision was made to allow for a complete retraction of the patellar tendon-patella complex starting along the proximal margins of the bursa and continuing distally along its medial and lateral margins.

At this point, whether the bursa was more easily identified from the lateral or medial border or equally the same from both borders was recorded. The dimensions of the deep infrapatellar bursa were then readily identified (Table 1). After all the measurements were completed, a sagittal incision was made through the retropatellar fat pad at its midportion on the bursa to identify the most distal anterior intraarticular portion of the tibia, and the distance from the bursa to the joint was recorded. Whether the bursa had an intraarticular communication with the knee joint was also recorded. Because of the nature of the dissection approach, the exact depth in the anterior to posterior plane could not be accurately measured, so it was not recorded.

## RESULTS

A deep infrapatellar bursa was identified in all specimens. In 34 knees (68%), the deep infrapatellar bursa was more readily identified at its lateral border, and in 8 knees

\* Address correspondence and reprint requests to Robert F. LaPrade, MD, Department of Orthopaedic Surgery, University of Minnesota, 420 Delaware Street, SE, Box 492 UMHC, Minneapolis, MN 55455.

Neither the author nor the related institution has received any financial benefit from research in this study.

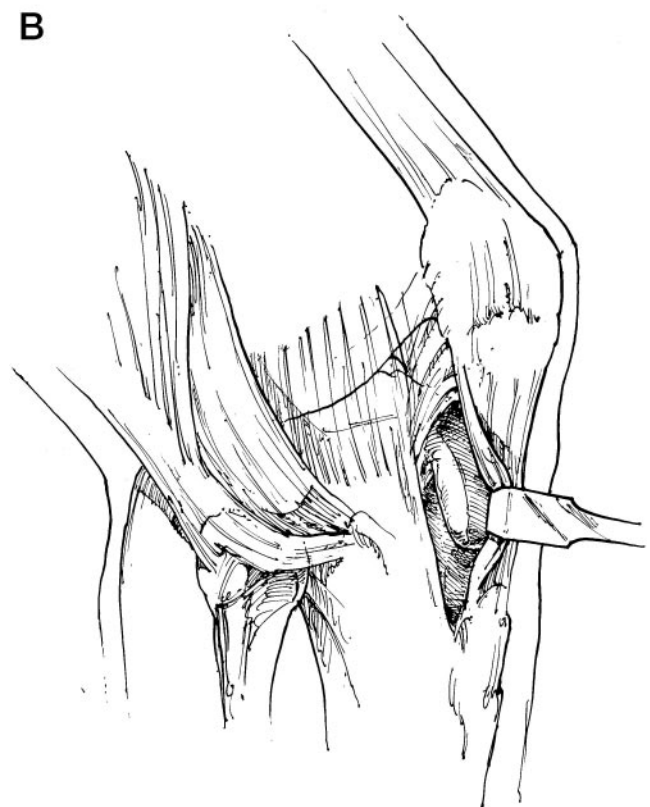
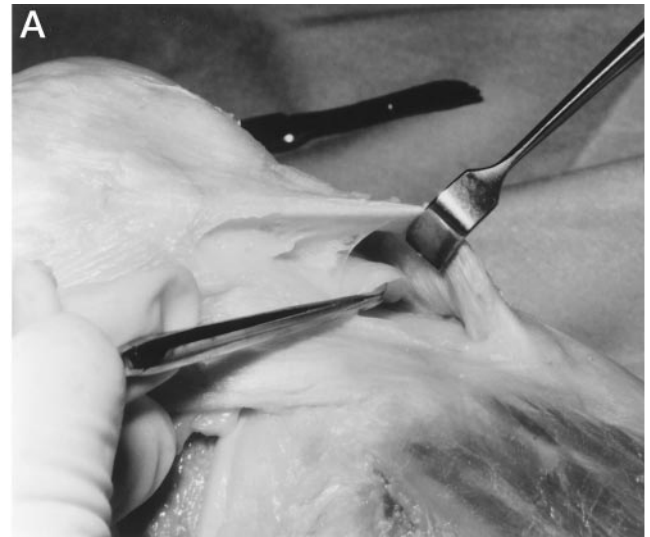
TABLE 1  
Dimensions of the Deep Infrapatellar Bursa (IPB) and Related  
Anatomic Structures of the Knee

Variable	Length (mm) $\pm$ 1 SD
Posterior compartment of deep IPB	
Medial edge	13.6 $\pm$ 3.4
Midportion	13.4 $\pm$ 3.2
Lateral edge	16.4 $\pm$ 4.0
Distance from superior aspect of posterior compartment of deep IPB to knee joint	18.4 $\pm$ 3.2
Length of fat pad apron over the posterior compartment of the deep IPB	9.7 $\pm$ 3.0
Anterior compartment of the IPB—midportion	
Patellar tendon (middle)	48.6 $\pm$ 5.2
Variable	Width (mm) $\pm$ 1 SD
Deep IPB at tibial tubercle	30.0 $\pm$ 2.4
Deep IPB 5 mm proximal to tibial tubercle	30.5 $\pm$ 2.8
Deep IPB 10 mm proximal to tibial tubercle	31.0 $\pm$ 3.0
Most proximal aspect of deep IPB—anterior compartment	29.2 $\pm$ 6.5
Patellar tendon at insertion on tibial tubercle	26.1 $\pm$ 2.8

(16%) the bursa was more readily identified from the medial border. In the remaining eight knees (16%), the deep infrapatellar bursa was equally identifiable from either the lateral or medial border during the dissection approach.

In all specimens, the deep infrapatellar bursa was located directly posterior to the patellar tendon, just proximal to its insertion on the tibial tubercle (Fig. 1). The bursa was found to be slightly wider than the width of the patellar tendon at its insertion site on the tibial tubercle (Table 1). Two portions of the bursa were found in all specimens. The deeper portion (posterior compartment) of the bursa formed a trapezoidal, almost rectangular, shape against the anterior portion of the proximal tibia and was located between the proximal margin of the tibial tubercle and the distal attachment of the retropatellar fat pad onto the proximal tibia. The wider base of the trapezoid was on the lateral side, and the narrower base was on the medial side. Anterior to this more posterior compartment of the bursa was an apron-like projection of fat from the retropatellar fat pad that covered the majority of the posterior compartment of the bursa (Fig. 2). The anterior portion of the deep infrapatellar bursa was located anterior to this fat pad apron and extended more proximal than the deeper portion of the bursa. The most proximal portion of the anterior compartment of the deep infrapatellar bursa was found to have an oval-shaped attachment to the posterior aspect of the patellar tendon.

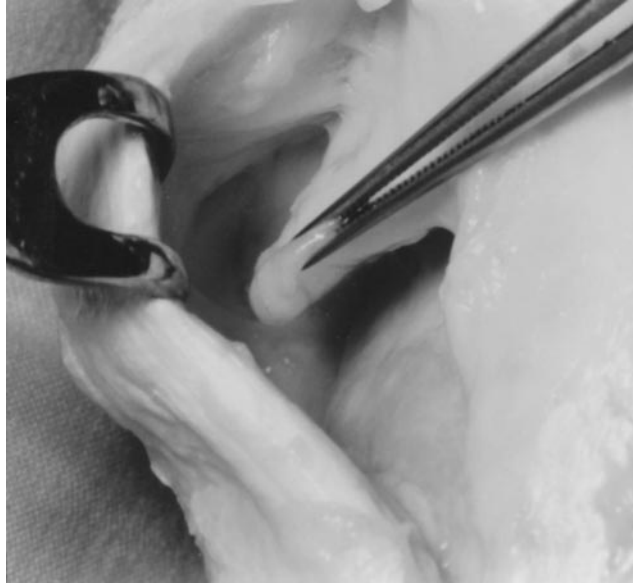The average dimensions of the deep infrapatellar bursa are included in Table 1. No communication to the knee joint was found via dissections in any of the 50 knees. The deep infrapatellar bursa was found to be posterior to the distal 38% of the patellar tendon.



**Figure 1.** Photograph (A) and illustration (B) of the deep infrapatellar bursa of the knee (patellar tendon is retracted, lateral aspect right knee).

## DISCUSSION

Although disorders of the deep infrapatellar bursa of the knee have been described as a source of anterior knee pain and other knee pathologic abnormalities, there are no precise anatomic descriptions or descriptions of surgical approaches in the English literature. Likewise, the prev-



**Figure 2.** Fat pad extension ("apron") extending from the retropatellar fat pad and partially dividing the deep infrapatellar bursa into an anterior and posterior compartment (right knee, medial view, patellar tendon retracted, fat pad "apron" in tissue forceps).

absence of this bursa and whether it communicates with the knee joint have not been documented.

In this series of dissections, the deep infrapatellar bursa of the knee was present in all specimens. It did not communicate with the knee joint in any specimen. Also, the bursa was partially compartmentalized, with a portion of the retropatellar fat pad extending down like an apron and dividing it into anterior and posterior compartments. This compartmentalization has not been described previously.

Understanding the anatomic location of the deep infrapatellar bursa should aid the clinician in the differential diagnosis of anterior knee pain. The location of the deep infrapatellar bursa can be consistently found by palpation of the distal 1 to 2 cm of the patellar tendon, just proximal to its insertion on the tibial tubercle. This is best accomplished with the knee in full extension and with the quadriceps mechanism relaxed. It is more readily identified in most knees on the lateral side of the patellar tendon, just proximal to the tibial tubercle. Thus, this location is recommended for aspiration, injection, or surgical approach for an inflammatory bursitis, septic bursitis, or other pathologic changes known to be associated with bursas.<sup>2, 4, 8, 9, 11, 15</sup>

Based on the observations reported here, the recommended surgical approach to the deep infrapatellar bursa, if necessary, is through an approximately 2.5-cm sagittal incision along the lateral edge of the patellar tendon, just proximal to its insertion on the tibial tubercle. Through this incision, one can retract the patellar tendon to gain access to the entire portion of the deep infrapatellar bursa.

The clinical significance of disorders of the deep infrapatellar bursa as a source of anterior knee pain has been documented.<sup>5, 7-17</sup> Routine palpation of the deep infrapatellar bursa should be included during the clinical examination of the knee. The author has found this bursa to be an occasional source of inflammatory bursitis in patients with anterior knee pain. Diagnostic lidocaine injections of this bursa can be used to confirm isolated inflammation; however, in my experience, it has rarely been found to be the sole anatomic source for a patient's chief complaint.

Fulkerson and Hungerford<sup>3</sup> have reported that inflammatory bursitis of this structure can provoke symptoms similar to patellofemoral arthralgia. Inflammation and pain associated with the deep infrapatellar bursa have also been identified in patients with Osgood-Schlatter disease.<sup>12, 14</sup> In one study of patients with Osgood-Schlatter disease, a distended deep infrapatellar bursa was seen on magnetic resonance imaging in 71% (12 of 17) of cases.<sup>14</sup> Injection of this bursa with lidocaine or a combination of lidocaine and corticosteroids has been reported to result in clinical relief of symptoms in the majority of patients.<sup>12, 14</sup> These studies did not mention the technique used to inject the deep infrapatellar bursa in these patients.

This deep infrapatellar bursa has also been implicated as a source of anterior knee pain in patients after patellectomy.<sup>6</sup> Scarring of the deep infrapatellar bursa has also been implicated in the infrapatellar contraction syndrome.<sup>9</sup> Knowledge of the dimensions of this bursa should aid the surgeon in planning a surgical release when clinically indicated.

The deep infrapatellar bursa was present in all knees in this series. Knowing the anatomic location of the deep infrapatellar bursa will allow the clinician to differentiate pain localized to this bursa from other sources of anterior knee pain.

## ACKNOWLEDGMENTS

The author acknowledges the assistance of Fred Wentorf, MS, and Jeff Heinemann, MD, for assistance in dissections and data collection.

## REFERENCES

1. Albert J, Lagier R: Enthesopathic erosive lesions of patella and tibial tuberosity in juvenile ankylosing spondylitis. Anatomico-radiological study of a case with tibial bursitis. *ROFO Fortschr Geb Rontgenstr Nuklearmed* 139: 544-548, 1983
2. Buck RM, McDonald JR, Ghormley RK: Adventitious bursas. *Arch Surg* 47: 344-351, 1942
3. Fulkerson RP, Hungerford DS: Evaluation and rehabilitation of nonarthritic anterior knee pain, in *Disorders of the Patellofemoral Joint*. Baltimore, Williams & Wilkins, 1990, pp 94-95
4. Fullerton A: The surgical anatomy of the synovial membrane of the knee joint. *Br J Surg* 4: 191-200, 1916
5. Ho G, Su EY: Antibiotic therapy of septic bursitis. Its implication in the treatment of septic arthritis. *Arth Rheum* 24: 905-911, 1981
6. Insall JN, Radin EL: Does chondromalacia patella exist?, in Pickett JC, Radin EL (eds): *Chondromalacia of the Patella*. Baltimore, Williams & Wilkins, 1983, pp 76-77
7. Lagier R, Albert J: Bilateral deep infrapatellar bursitis associated with tibial tuberosity enthesopathy in a case of juvenile ankylosing spondylitis. *Rheumatol Int* 5: 187-190, 1985

8. Norley T, Bickel WH: Calcification of the bursae of the knee. *J Bone Joint Surg* 31A: 417–420, 1949
9. Paulos LE, Wnorowski DC, Greenwald AE: Infrapatellar contraction syndrome. Diagnosis, treatment, and long-term followup. *Am J Sports Med* 22: 440–449, 1994
10. Raddatz DA, Hoffman GS, Franck WA: Septic bursitis: Presentation, treatment, and prognosis. *J Rheumatol* 14: 1160–1163, 1987
11. Reicher MA, Hartzman S, Bassett LW, et al: MR imaging of the knee. Part I. Traumatic disorders. *Radiology* 162: 547–551, 1987
12. Reichmister J: Injection of the deep infrapatellar bursa for Osgood-Schlatter's disease. *Clin Proc Child Hosp DC* 25: 21–24, 1969
13. Roschmann RA, Bell CL: Septic bursitis in immunocompromised patients. *Am J Med* 83: 661–665, 1987
14. Rosenberg ZS, Kawelblum M, Cheung YY, et al: Osgood-Schlatter lesion: Fracture or tendinitis? Scintigraphic, CT, and MR imaging features. *Radiology* 185: 853–858, 1992
15. Taylor PW: Inflammation of the deep infrapatellar bursa of the knee. *Arthritis Rheum* 32: 1312–1314, 1989
16. Waters P, Kasser J: Infection of the infrapatellar bursa: A report of two cases. *J Bone Joint Surg* 72A: 1095–1096, 1990
17. Weston WJ: The deep infrapatellar bursa. *Australas Radiol* 17: 212–213, 1973