

An Analysis of an Anatomical Posterolateral Knee Reconstruction

An In Vitro Biomechanical Study and Development of a Surgical Technique

Robert F. LaPrade,^{*†} MD, PhD, Steinar Johansen,[‡] MD, Fred A. Wentorf,[†] MS, Lars Engebretsen,[‡] MD, PhD, Justin L. Esterberg,[†] MD, and Andy Tso,[†] MS
From the [†]Department of Orthopaedic Surgery, University of Minnesota, Minneapolis, Minnesota, and the [‡]Department of Orthopaedic Surgery, Ullevaal Hospital, University of Oslo, Oslo, Norway

Background: To date, no surgical technique to treat posterolateral knee instability anatomically reconstructs the 3 major static stabilizing structures of the posterolateral knee: the fibular collateral ligament, the popliteus tendon, and the popliteofibular ligament.

Hypothesis: Static varus and external rotatory stability would be restored to the reconstructed knee with a posterolateral knee injury.

Methods: The anatomical locations of the original fibular collateral ligament, popliteus tendon, and popliteofibular ligament were reconstructed using a 2-graft technique. Ten cadaveric specimens were tested in 3 states: intact knee, knee with the 3 structures cut to simulate a grade III injury, and the reconstructed knee.

Results: For the varus loading tests, joint stability was significantly improved by the posterolateral reconstruction compared to the cut state at 0°, 30°, 60°, and 90° of flexion. There were no significant differences between the intact and reconstructed knees at 0°, 60°, and 90° for varus translation. For the external rotation torque tests, external rotation was significantly higher for the cut state than for the intact or reconstructed posterolateral knee. There was no significant difference in external rotation between the intact and reconstructed posterolateral knees at any flexion angle.

Conclusions: This 2-graft technique to reconstruct the primary static stabilizers of the posterolateral knee restored static stability, as measured by joint translation in response to varus loading and external rotation torque, to knees with grade III posterolateral injuries.

Keywords: posterolateral knee; knee reconstructions; fibular collateral ligament; popliteus complex

The complex anatomy of the posterolateral aspect of the knee has become better understood in recent years.^{25,27,39,40,42}

Injuries to the posterolateral structures can result in posterolateral rotary instability of the knee.^{3,10,17} In addition to torn soft tissue structures, the convex opposing articu-

lar surfaces of the lateral compartment of the knee accentuate this instability pattern, such that there is also a lack of inherent bony stability compared to the medial side of the knee.^{20,29} These injuries are not commonly found isolated and are usually found in the setting of other injuries such as ACL or PCL tears.⁸ Although awareness of the instability pattern found with these injuries has increased, it has also been noted that acute injuries are often overlooked in the initial examination.^{23,26,46} In the presence of other injuries, a posterolateral knee injury may be undiagnosed or misdiagnosed because of the difficulty of the physical examination in the acute setting and the often difficult examination in the chronic setting.^{1,3,17,24,30,46} Several physical examination techniques

*Address correspondence to Robert F. LaPrade, MD, PhD, Department of Orthopaedic Surgery, University of Minnesota, 2450 Riverside Avenue, R200, Minneapolis, MN 55454 (e-mail: lapra001@umn.edu).

Presented at the 27th Annual Meeting of the AOSSM, Keystone, Colorado, 2001.

No author or related institution has received financial benefit from research in this study. See Acknowledgement for funding information.

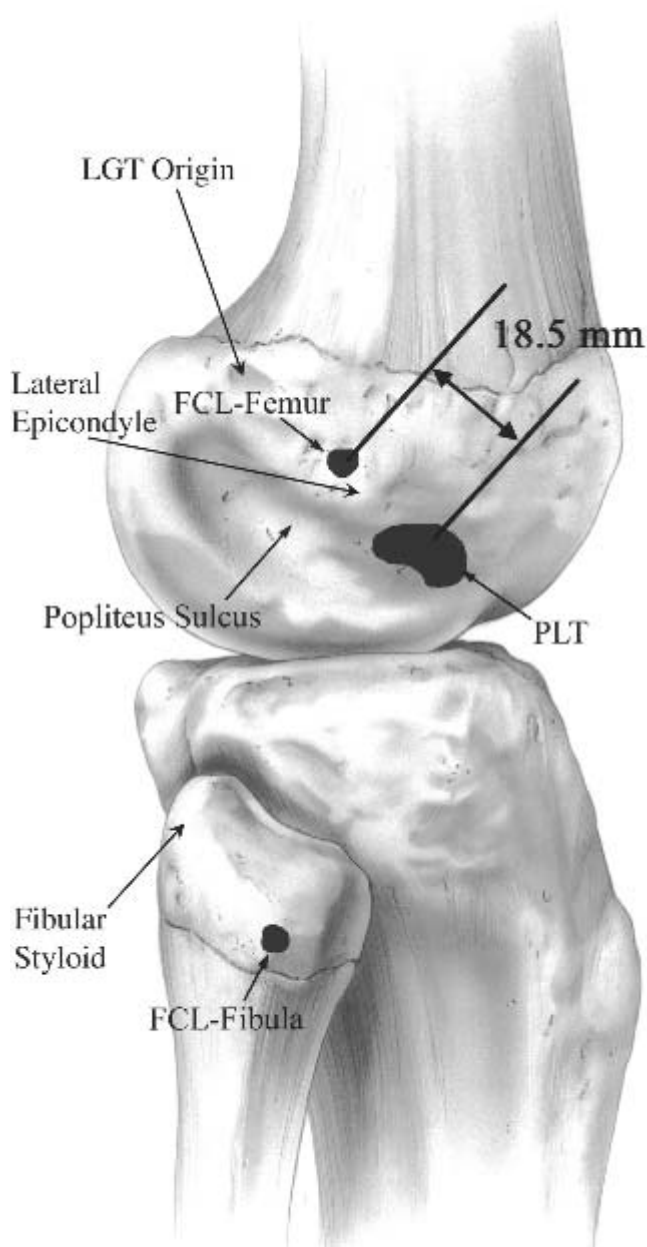


Figure 1. The attachment sites of the fibular collateral ligament (FCL) on the femur and fibula, and the popliteus tendon (PLT) in the popliteus sulcus of the femur (lateral view, right knee). In addition, the average distance between the femoral attachment sites is noted. LGT, lateral gastrocnemius tendon. Reprinted from LaPrade et al.²⁷

can be used to elicit increases in posterolateral rotation, varus laxity, and external rotation instability, which are often found with posterolateral knee injuries (varus laxity at 0 and 30°, posterolateral drawer test at 80°, reverse pivot shift test, external rotation recurvatum test, dial test at 30 and 90°, and a varus thrust gait pattern).^{7,17,19,20,30} In addition, arthroscopic evaluation of the lateral compartment and magnetic resonance imaging have been proven to be accurate to assist in diagnosing acute and

chronic posterolateral injuries.^{22,24} It is important to diagnose grade III posterolateral injuries because, if left untreated, they may result in significant impairment, including pain, meniscal tears, osteoarthritis, and instability.^{17,21,30,36} Recent in vitro studies have also demonstrated significantly increased force on ACL and PCL grafts in knees in the presence of grade III posterolateral injuries.^{14,28,29} In addition, untreated posterolateral injuries have been implicated in ACL and PCL reconstruction graft failures, placing even more importance on the treatment of these injuries in the face of combined ligament injuries.^{26,28,29,36,38}

Surgical treatment of grade III posterolateral injuries ranges from primary repair of all injured structures in the acute setting^{2,3,26} to various reconstructions, tenodesis, osteotomies, and advancement procedures for chronic injuries.¹¹ These include fibular collateral ligament reconstruction,^{32,46} femoral bone block advancements,^{10,18,36,43} biceps femoris tenodesis,^{5,6,9,47} valgus high tibial osteotomies,²⁶ popliteus tendon and popliteofibular ligament reconstruction using split patellar tendon grafts,⁴⁶ popliteus recess procedures,²⁰ and central slip iliotibial band or biceps femoris grafts.^{1,4,46} The purpose of these operative techniques is to attempt to restore varus and external rotary static stability to knees with significant and symptomatic posterolateral rotatory instability of the knee.

Although these surgical techniques may provide varying degrees of stability to knees with these injuries, we believe that there are no reported techniques that anatomically reconstruct the 3 primary contributors to static stability of the posterolateral knee: the fibular collateral ligament, the popliteus tendon, and the popliteofibular ligament.^{11,12,26,27,30,34,44,45} The attachment anatomy of these structures has been recently studied and quantified (Figure 1).^{27,40,42} Furthermore, there has been a paucity of in vitro biomechanical studies for most currently described posterolateral reconstructions.⁴⁷

In this study, we describe an anatomical reconstruction of the fibular collateral ligament, popliteus tendon, and popliteofibular ligament. The biomechanics and kinematics of knees with this reconstruction technique were tested in vitro. Our hypothesis was that this reconstruction would restore static stability for varus and external rotation to knees with a grade III injury of the fibular collateral ligament, popliteus tendon, and popliteofibular ligament. In addition, a surgical approach for this technique was tested in 10 whole fresh cadavers to test its clinical feasibility.

MATERIALS AND METHODS

Specimen Preparation

Fourteen nonpaired fresh-frozen cadaveric lower extremities that had no evidence of injuries or instability by clinical examination and dissection were used in this study.

¹¹References 1, 5, 10, 18, 26, 32, 36, 43, 47.

The average age of the specimens was 64 years (range, 62-74 years). The first 4 lower extremities were pilot specimens; the remaining 10 were experimental specimens. Before testing the knees, each specimen was prepared so that it would be suitable for testing in the in vitro knee joint testing system.^{28,29} The skin and subcutaneous fat were removed from the knees, leaving the investing fascia intact. The Achilles tendon and a bone block from the calcaneus were harvested from each specimen to serve as reconstruction autografts for the procedure. The muscle and fascia were removed, and the femur, tibia, and fibula were cut to within 15 cm of the joint line. The specimens were then potted in polymethylmethacrylate (Dentsply International, York, Pa) to facilitate knee testing. Each specimen was then dissected to expose and isolate the native fibular collateral ligament, popliteus tendon, and popliteofibular ligament and their attachment sites.

Pilot Studies

The first 4 knees were used as pilot specimens to determine the limits of testing and loading for the specimens. Biomechanical testing was applied to these pilot knees in multiple flexion angles (0°, 30°, 60°, and 90°) and loads (anterior drawer, 60 N; posterior drawer, 60 N; external rotation, 5 N·m; internal rotation, 5 N·m; varus, 12 N·m; valgus, 12 N·m) to determine when abnormal motion occurred in the intact versus the cut and reconstructed knees and the limits of the testing system. In addition, buckle transducers^{29,33} were placed on the native and reconstructed fibular collateral ligament, popliteus tendon, and popliteofibular ligament to measure the amount of force seen in these structures (not reported in the study; part of a separate study). No appreciable changes in force were seen on the native or reconstructed fibular collateral ligament, popliteus tendon, and popliteofibular ligament for an anterior or posterior applied load or a valgus or internal rotation moment in the pilot analysis. In addition, no significant increase in motion was seen when these native structures were cut for the same loads. Therefore, these biomechanical loads were not tested in this study.

The weak point of the specimens in the pilot testing was found to be the tunnel drilled through the fibular head and styloid during varus testing in the reconstructed knees. The superolateral aspect of the fibular head and styloid reconstruction tunnels were found to comminute with repetition of the applied 12 N·m varus loads, and the result was that the fibular collateral ligament graft had a slight but noticeable increase in motion at the lateral aspect of the fibular tunnel over time. This appeared to occur because of the osteopenic bone at this location in these elderly specimens. Therefore, we adjusted the applied loads to have a 5 N·m varus applied moment, which minimized fibular tunnel loosening for the specimens in this study.

Biomechanical Testing

The specimens were placed into the in vitro knee joint testing system.^{28,29} The femur was secured to the femoral jig, in which the only degree of freedom was in the sagittal

plane to change knee flexion angles. The tibia/fibula was secured to its respective jig, which was free to move with the rotational moments that were applied to the knee. A counterbalance weight assembly connected to the tibia/fibula jig was adjusted, and the specimen was rotated within the clamp housings until the knee flexed in the horizontal plane.

A computer-controlled video motion capture system (Qualysis Inc, Glastonbury, Conn) was used to analyze the motion of the knee under the applied moments.²⁷ One set of 3 infrared-emitting spheres was fixed to each of the femoral and tibia/fibula jigs to serve as reference points for knee motion. A fine-point marker with predetermined x , y , and z coordinates and an accuracy previously calculated to 0.1 mm²⁷ was used to identify the reference points for each specimen. The same person identified these anatomical reference points throughout the study. For purposes of this study, we report varus translation as millimeters of lateral compartment separation at the far lateral aspects of the articular cartilage margins of the lateral femoral condyle and lateral tibial plateau, whereas external rotation is reported in degrees, according to previous joint coordinate system descriptions.^{12,13,28,29}

The knees were then tested under 3 conditions: (1) intact fibular collateral ligament, popliteus tendon, and popliteofibular ligament; (2) cut fibular collateral ligament, popliteus tendon, and popliteofibular ligament (to simulate a grade III posterolateral injury^{28,29}); and (3) reconstructed knee. All 3 conditions involved applying a 5 N·m varus moment to the knee at 0°, 30°, 60°, and 90°. A 5-N·m external rotation torque was also applied after the varus torque.

Posterolateral Reconstruction Technique

A description of this anatomical posterolateral knee surgical technique follows, as it would be performed clinically. Ten whole fresh human cadavers were used to develop and refine the surgical technique. The surgical exposure to the posterolateral aspect of the knee has been described previously.^{23,26,42} After a standard lateral skin incision was performed and a subfascial posteriorly based flap following the superficial layer of the iliotibial band and the fascial layer covering the short and long heads of the biceps femoris was developed, an incision was made posterior and parallel to the long head of the biceps muscle. The common peroneal nerve was identified, and a neurolysis was performed from approximately 6 cm proximal to the fibula to just past the peroneus longus fascial sheath distally. The nerve was retracted during the reconstructive procedure. The interval between the common peroneal nerve and the long head of the biceps was developed by blunt dissection, anterior to the lateral gastrocnemius tendon and posterior to the soleus and popliteus muscle bellies, and allowed access to the posteromedial aspect of the fibular styloid and the posterolateral aspect of the tibia. The posterior tibial popliteal sulcus was identified through this interval by palpation of the posterolateral lateral tibial plateau.^{16,31} This bony landmark is located at the musculotendinous junction of the popliteus. The normal popliteofibular liga-

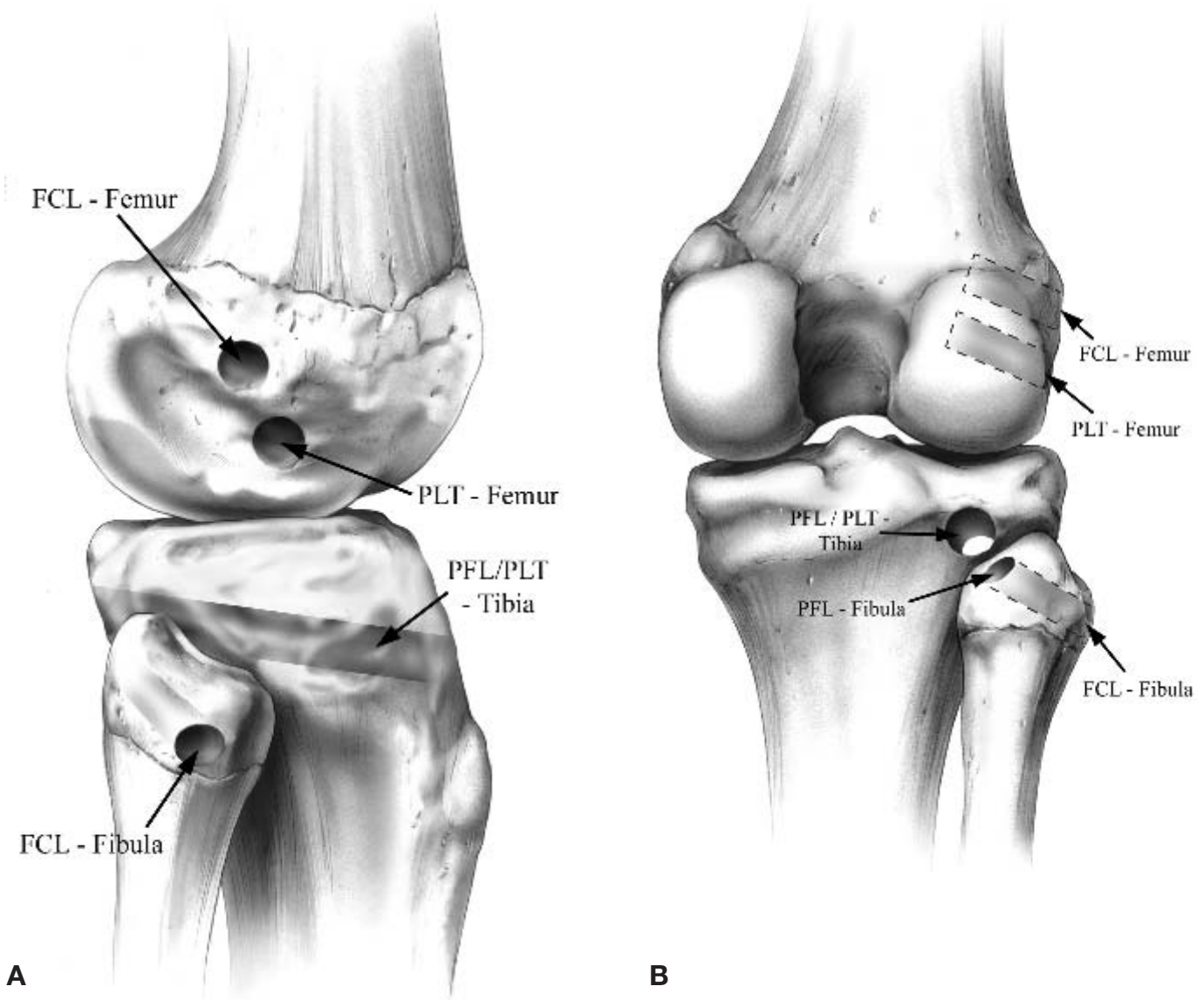


Figure 2. The femoral, tibial, and fibular posterolateral knee reconstruction tunnel placement in a right knee. A, lateral view; B, posterior view. FCL, fibular collateral ligament; PLT, popliteus tendon; PFL, popliteofibular ligament.

ment's attachment site on the posteromedial aspect of the downslope of the fibular styloid²⁷ was also identified.

A small horizontal incision (1.5-2.0 cm long) was made through the anterior arm of the long head of the biceps femoris, 1 cm proximal to the lateral aspect of the fibular head, which opened the fibular collateral ligament–biceps bursa.²⁵ The attachment site of the fibular collateral ligament on the lateral aspect of the fibular head was then identified through this bursa.

The tibial and fibular bony tunnels for the reconstruction were then drilled through the midpoints of the attachment sites (Figure 2). A cannulated PCL femoral tunnel-aiming device was adapted for this portion of the reconstruction (Arthrex Inc, Naples, Fla). For the fibular tunnel, a K-wire was drilled through the fibular head from the attachment site of the fibular collateral ligament on the

lateral aspect of the fibular head to the attachment site of the popliteofibular ligament on the posteromedial fibular styloid using the same guide. A 7-mm tunnel was reamed over this guide pin. For the tibial tunnel, the guide was placed on the posterior popliteal tibial sulcus^{16,31} at the level of the popliteus musculotendinous junction (approximately 10 mm distal to the margin of the articular cartilage). A second K-wire was then drilled in an anteroposterior direction through the guide from a point just distal and medial to Gerdy's tubercle to exit at the posterior tibial popliteal sulcus. A large Chandler retractor (V Mueller, Deerfield, Ill) was used to protect the neurovascular bundle posteriorly as this guide pin was drilled. A 9-mm tunnel was then prepared by reaming over the K-wire. The entry and exit sites of both tunnels were smoothed off with the use of a rasp.

A third incision, approximately 10 cm long, was then made horizontally through the superficial layer of the iliotibial band, in line with its fibers.^{26,42} This incision originated distally from just proximal to Gerdy's tubercle and extended proximally to the distal termination of the lateral intermuscular septum. The interval between the split superficial layer of the iliotibial band was then exposed with anterior and posterior retraction to allow for identification of the fibular collateral ligament and popliteus tendon femoral attachments. A vertical arthrotomy was then made through the meniscomfemoral portion of the mid-third lateral capsular ligament,^{26,42} approximately 1 cm anterior to the normal course of the fibular collateral ligament, to expose the attachment site of the popliteus tendon on the proximal fifth of the popliteal sulcus.^{27,40,42} The femoral attachment site of the fibular collateral ligament was then identified, which was slightly proximal and posterior to the lateral epicondyle.^{27,42} Two eyelet-tipped guide pins were drilled parallel into the popliteus tendon and fibular collateral ligament attachment sites on the femur, aiming them anteromedially, with the use of the same cannulated PCL femoral-aiming device, through the distal femur. They exited the distal femur proximomedial to the medial epicondyle and adductor tubercle. When the eyelet pins are aimed to this position, they do not encounter either an ACL or PCL graft tunnel. A 9-mm femoral tunnel was then reamed over each guide pin to a depth of 20 mm. The bone bridge between the 2 tunnels was approximately 8 to 9 mm in width.

Two tendon grafts were then prepared by lengthwise splitting of the calcaneus and attached Achilles tendon lengthwise in 2 for the reconstruction. We found an Achilles tendon length of ≥ 22 cm was necessary for the grafts to ultimately exit the anterolateral tibial tunnel sufficiently to allow for distal staple fixation. Each bone plug was sized to fit the 9×20 -mm femoral tunnels, and 2 No. 2 passing sutures were placed through drill holes placed in each bone plug. The tendons were then tubularized using a No. 5 suture and sized to pass through a 7-mm tunnel. The bone block passing sutures were then placed into the eyelet-tipped guide pins. The bone plugs for the 2 grafts were pulled into their respective femoral tunnels by the passing sutures as the guide pins and sutures were pulled through to exit the medial aspect of the femur and thigh. The 2 bone blocks for the grafts were then fixed in the femoral tunnels using 7×20 -mm cannulated interference screws.

The first graft, with its bone plug secured at the proximal half and anterior fifth of the popliteal sulcus,²⁷ was used to reconstruct the popliteus tendon. The popliteus tendon graft was passed distally along the normal path of the popliteus tendon through the popliteal hiatus to reach the posterolateral aspect of the lateral tibial plateau at the location of the normal site of the musculotendinous junction of the popliteus. The graft was then pulled through the tibial tunnel from posterior to anterior. It emerged just medial and distal to Gerdy's tubercle.

The second graft was used to reconstruct both the fibular collateral ligament and the popliteofibular ligament. From its fixation site on the femur at the anatomical

attachment of the fibular collateral ligament, the graft was then passed medial (deep to) to the superficial layer of the iliotibial band and the anterior arm of the long head of the biceps femoris, following the normal distal course of the fibular collateral ligament. This interval was developed bluntly with the use of a curved hemostat to allow for passage of the graft. The graft was then passed through the fibular head and styloid tunnel from lateral to posteromedial and then pulled through the tibial tunnel from posterior to anterior. The knee was cycled for 1 minute through a full range of motion while placing distal traction to ensure that there was no slack present in the grafts. This graft was then tightened. The graft was then fixed in its fibular tunnel with a 7-mm cannulated bioabsorbable interference screw (Arthrex Inc) with the knee at 30° of flexion and neutral rotation and a slight valgus stress applied to reduce any potential varus opening of the lateral compartment of the knee. This portion of the graft, which now coursed between its fixation sites at the femoral tunnel and fibular head, composed the fibular collateral ligament reconstruction; the remaining portion of the graft composed the popliteofibular ligament reconstruction graft. This remaining graft followed the normal course of the popliteofibular ligament as it passed proximomedially from the posteromedial aspect of the fibular styloid to the posterolateral tibial tunnel, which was located at the popliteus musculotendinous junction.²⁷ This graft was also pulled through the tibial tunnel from posterior to anterior.

Both grafts were then tightened simultaneously on the tibia by applying an anterior traction load to the grafts at 60° of flexion and 5° of internal rotation of the leg. The grafts were fixed with an anteriorly placed 9-mm cannulated bioabsorbable interference screw (Arthrex Inc) in the tibia (Figures 3 and 4). Although not done in this study, we then clinically supplement this fixation with a small bone staple over the 2 grafts, just distal and medial to Gerdy's tubercle on the flat part of the tibia, to provide backup graft fixation. Although not actually sutured together, this fixation system allows the popliteofibular ligament and popliteus tendon grafts to function statically as a single unit.

Data Analysis

Statistical analysis using the Student *t* test was performed to compare motion analysis data between the intact controls; the cut fibular collateral ligament, popliteus tendon, and popliteofibular ligament state; and the posterolateral corner reconstructed knee at each knee flexion state for the varus and external rotation moments applied testing conditions. The statistical significance was assumed for $P < .05$.

RESULTS

Varus Motion Data

In comparing both the intact and reconstructed knee conditions to the injured posterolateral structures condition,

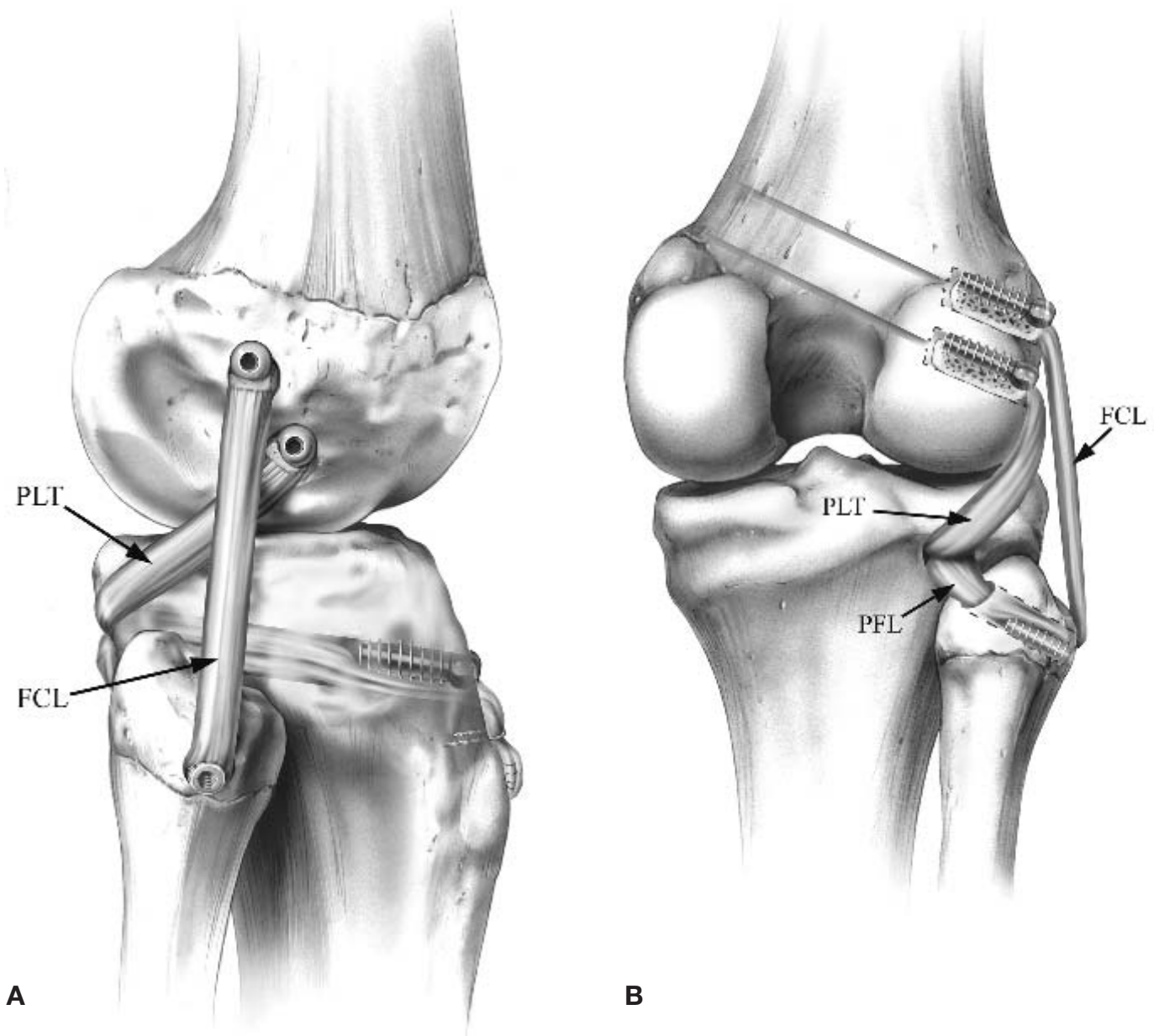


Figure 3. The posterolateral knee reconstruction procedure. A, lateral view, right knee; B, posterior view, right knee. PLT, popliteus tendon; FCL, fibular collateral ligament; PFL, popliteofibular ligament.

we found statistically significant differences between the varus translations at all tested knee flexion angles ($P < .01$) (Figure 5). When comparing the intact and reconstructed knee conditions, we found a significant difference in varus displacements between the 2 states at 30° ($P < .05$) but not at 0°, 60°, or 90° of flexion.

In the reconstructed knees, we qualitatively observed some loosening of the fixation of the fibular collateral ligament graft in the fibular head in progressing through the 3 varus force application trials at each flexion angle. This was because of mild comminution of the osteopenic bone of the bone tunnel through the lateral aspect of the fibular head in spite of our adjustments made in our testing pro-

cedure after our pilot study. However, although a measurable increase in varus translation of 1 to 2 mm was found between trials 1 and 3 for the reconstructed knee condition at each flexion angle, it was not statistically significant (Table 1).

External Rotation Data

In comparing both the intact knee and the reconstructed knee to the injured condition, a statistically significant difference was seen in the amount of external rotation (degrees) at all flexion angles ($P < .05$) (Figure 6). There was no significant difference between the intact and recon-

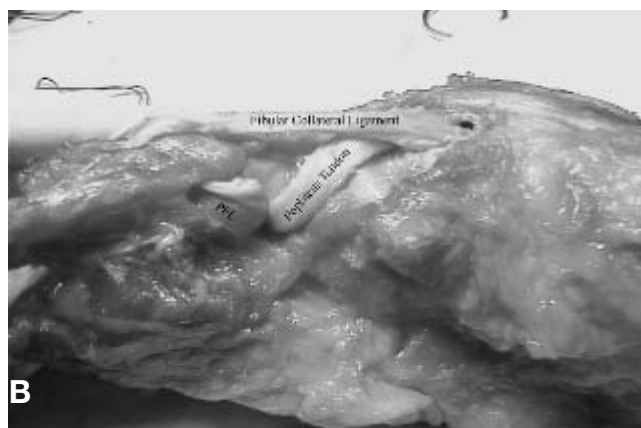
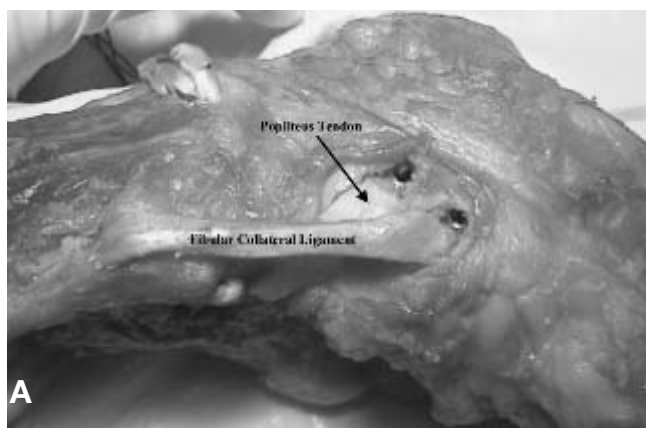


Figure 4. The posterolateral reconstruction procedure. A, lateral view, left knee; B, posterior view, left knee. PFL, popliteofibular ligament.

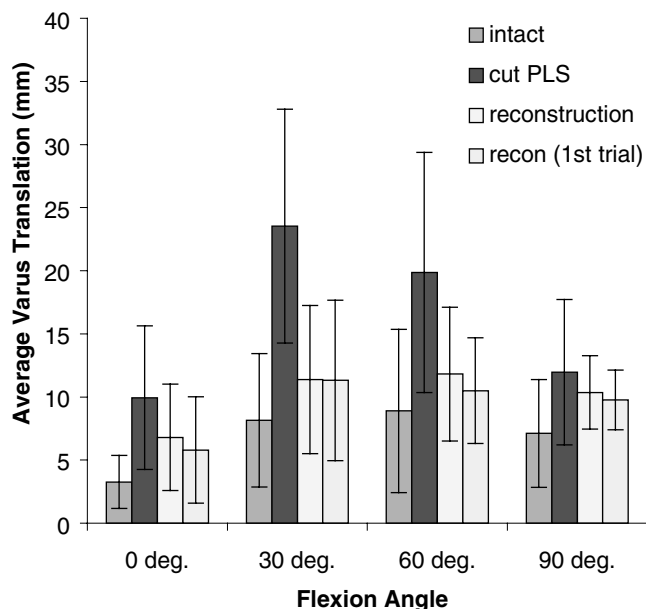


Figure 5. The average varus translation (mm) at each tested flexion angle for each tested knee state. PLS, posterolateral structures (fibular collateral ligament, popliteus tendon, popliteofibular ligament); recon, posterolateral reconstruction.

structed posterolateral knee structure states in external rotation at any tested knee flexion angle (Table 2).

DISCUSSION

There are several reported surgical techniques for treating chronic posterolateral knee instability.[¶] To our knowledge, there are no in vitro biomechanical studies of posterolateral knee reconstructions other than the biceps femoris tenodesis.⁴⁷ Most of the studies on posterolateral knee

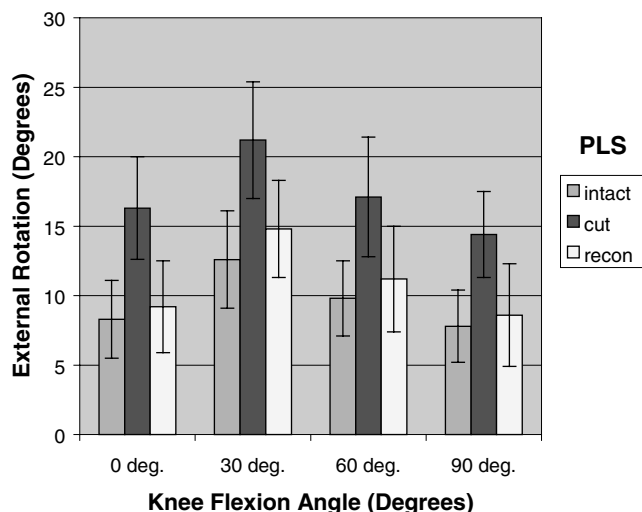


Figure 6. The average external rotation translation for each tested flexion angle for each tested knee state (intact, cut, and reconstructed posterolateral structures). PLS, posterolateral structures (fibular collateral ligament, popliteus tendon, popliteofibular ligament); recon, reconstructed.

reconstructions are clinical studies or descriptions of surgical techniques in book chapters.[#] It took many years before it became evident that quantitative anatomical and biomechanical studies of the native ACL and PCL were crucial in choosing appropriate graft locations and in developing proper cruciate ligament reconstruction techniques.^{8,9,14,15} It is now believed that grafts that reconstruct the normal anatomy of the cruciate ligaments are essential to restore the knee to best function; it has been demonstrated that with both ACL and PCL reconstructions, an anatomical reconstruction results in the best results in reducing abnormal joint motion and in improving patient function.^{8,9,14,15} We believe that an anatomical reconstruction of the posterolateral knee would also ulti-

[¶]References 1, 4-6, 10, 18, 32, 35, 36, 46, 47.

[#]References 1, 4, 5, 6, 10, 18, 20, 26, 32, 35, 36, 43, 46.

TABLE 1
Varus Translations Between Testing States for an Applied 5 N·m Varus Load

Average Varus Translation, mm	0	30	60	90
Intact knee	3.2 ± 2.1	8.2 ± 5.3	8.9 ± 6.5	7.1 ± 4.3
Knee with cut posterolateral structures	9.9 ± 5.7	24 ± 9.3	20 ± 9.5	12 ± 5.8
Reconstructed knee	6.8 ± 4.2	11 ± 5.9	12 ± 5.3	10 ± 2.9
Reconstructed knee (first trial only)	5.7 ± 4.2	11 ± 6.4	10 ± 4.2	9.8 ± 2.4

TABLE 2
External Rotation Between Testing States for an Applied 5 N·m External Rotation Load

Average External Rotation, degrees	0	30	60	90
Intact knee	8.3 ± 2.8	12.6 ± 3.5	9.8 ± 2.7	7.8 ± 2.6
Knee with cut posterolateral structures	16.3 ± 3.7	21.2 ± 4.2	17.1 ± 4.3	14.4 ± 3.1
Reconstructed knee	9.2 ± 3.3	14.8 ± 3.5	11.2 ± 3.8	8.6 ± 3.7

mately result in improved objective motion stability and patient function. Our study was performed to develop an anatomical posterolateral reconstruction in attempts to ultimately improve patients' function and outcomes, similar to the previous studies on anatomical reconstructions of the cruciate ligaments.^{8,9,14,15}

To our knowledge, there are no reported posterolateral knee reconstructions that attempt to anatomically restore the anatomy along the course and quantitative attachment sites of the 3 major static stabilizers: the fibular collateral ligament, popliteus tendon, and popliteofibular ligament.^{11,12,26,27,30,34,44,45} We designed this anatomical surgical technique based on our previous quantitative anatomical study of the attachment sites of the fibular collateral ligament, popliteus tendon, and popliteofibular ligament.²⁷ Recognizing that the goal of a surgical reconstruction in the clinical setting is to restore the patient's subjective and objective knee performance, the hypothesis for the development of this technique was that by accurately restoring the anatomy, we could restore the static stability of knees with grade III posterolateral injuries. In addition, we aimed to describe a surgically feasible reconstruction technique.

The quantitative attachment anatomy of the fibular collateral ligament, popliteus tendon, and popliteofibular ligament has been recently reported (Figure 1).^{27,40,42} The proximal fibular collateral ligament attachment has been noted to be close to, but not attached to, the lateral epicondyle.²⁷ The average proximal fibular collateral ligament femoral attachment was 1.4 mm proximal and 3.1 mm posterior to the lateral epicondyle.²⁷ Distally, the fibular collateral ligament inserts onto the anterolateral aspect of the fibular head at an average of 38% along the total width of the fibular head from anterior to posterior.^{27,41,42} The popliteus tendon attaches on the proximal portion of the anterior fifth of the popliteal sulcus of the femur, and it attaches anteriorly and distally to the fibular

collateral ligament femoral attachment with an average distance of 18.5 mm between their femoral attachment sites.²⁷ It is our belief that one reconstructive graft and tunnel cannot accurately reconstruct the fibular collateral ligament and popliteus tendon attachments on the femur because of the almost 2-cm distance between these attachment sites. In addition, the popliteofibular ligament was noted to originate at the musculotendinous junction of the popliteus muscle and attach to the posteromedial aspect of the fibular head.^{27,40,42} Our tunnel locations for this reconstruction technique were based at these attachment locations (Figure 2).

The results of this current study indicate that this anatomical posterolateral knee reconstruction, using 2 separate grafts to reconstruct the fibular collateral ligament, popliteus tendon, and popliteofibular ligament, restored static varus and external rotation stability in cadaveric knees with simulated grade III injury of the fibular collateral ligament, popliteus tendon, and popliteofibular ligament for the majority of knee flexion angles and conditions. Only at 30° of knee flexion was there a statistical difference between the intact and reconstructed knees in varus, with a total average difference in varus translation of 2.8 mm between the 2 states. We believe this occurred because of the limitations of the static testing conditions in our knee-testing machine (see next paragraph). For all angles of knee flexion, we observed significant decreases of varus displacement for the reconstruction compared to the injured state, which correlated with our hypothesis. In addition, there was no biomechanical evidence of this reconstruction technique overconstraining the knees, which was found to occur with the biceps tenodesis procedure.⁴⁷ It allows for early unrestricted knee motion with no cases of arthrofibrosis in any clinical patients to date.

As we applied varus stress to the reconstructed knees at each knee flexion angle, we occasionally observed loosen-

ing of the fibular collateral ligament graft fibular head fixation, which appeared to be due to partial failure of the osteopenic bone of the fibular tunnel in the geriatric cadavers used in this study. The fibular collateral ligament graft had a slight visible increase in motion around the interference screw as testing went on over time. Depending on the strength of the bone stock in the cadaveric knees, there was occasional breakage of the superior cortical rim of the anterior fibular head bone tunnel entrance. Because of the occasional slipping of the fibular collateral ligament graft, we also compared trial 1 with trial 3 at each flexion angle tested. For all reconstructed knees, we observed a measurable, but nonsignificant, increase in varus translation with application of a varus torque from trial 1 to trial 3 (Table 1). This highlights 2 of the limitations in this study: (1) there was osteopenic bone stock in many of the knees used, and (2) we applied significant loads to the reconstructed knee immediately after the operation, which would not be recommended clinically. In our practice, we keep patients nonweightbearing for 6 weeks after posterolateral knee reconstruction. In more than 80 patients in our ongoing prospective study to date, there have been no patients with fibular tunnel fractures or apparent graft laxity. In addition, patients are not restricted in their range of motion exercises. Although we have used a 7-mm tunnel in our ongoing prospective study, there may be circumstances in some patients with a small body build or osteopenic bone in which a 6-mm fibular tunnel may be necessary.

We found that this reconstruction eliminated the external rotation laxity produced by an induced grade III posterolateral corner injury. The average displacements were not statistically different between the reconstructed state compared to the intact state, and both conditions were significantly less than the injured state.

In the simulated grade III posterolateral injury condition, we observed increased varus translation and external rotation relative to the intact posterolateral knee structures condition after cutting the fibular collateral ligament, popliteus tendon, and popliteofibular ligament. These observations correlate with previous selective-cutting studies and current understanding of the stabilizing function of these structures in the static environment of the knee.^{11,12,28,29,44}

We conclude that the anatomical posterolateral knee reconstruction technique reported in this study for the fibular collateral ligament, popliteus tendon, and popliteofibular ligament restores varus and external rotary stability in knees with grade III posterolateral knee injuries. It does not rely on the use of local dynamic or static stabilizing structures that could result in morbidity in those posterolateral reconstructive techniques that use them.^{1,5,6,46} Although this study shows encouraging results for an anatomical reconstruction for chronic grade III posterolateral instability, it is recognized that our study does have the limitations of an in vitro study, and it assumes a static environment in the knee. Therefore, we propose this biomechanical study serve as a lead point for further clinical prospective studies to determine patient outcomes with this reconstructive technique.

ACKNOWLEDGMENT

This study was supported by the University of Minnesota Sports Medicine Research Fund of the Minnesota Medical Foundation and an Arts and Sciences Grant, Office of the Vice President for Research, University of Minnesota. The authors thank the faculty of the Pathology Lab at Ullevaal Hospital, University of Oslo, Oslo, Norway, for their assistance in providing specimens for the surgical approach portion of this study.

REFERENCES

- Albright JP, Brown AW. Management of chronic posterolateral rotatory instability of the knee: surgical technique for the posterolateral corner sling procedure. *Instr Course Lect.* 1998;47:369-378.
- Baker CL, Norwood LA, Hughston JC. Acute combined posterior cruciate and posterolateral instability of the knee. *Am J Sports Med.* 1984;12:204-208.
- Baker CL Jr, Norwood LA, Hughston JC. Acute posterolateral rotatory instability of the knee. *J Bone Joint Surg Am.* 1983;65:614-618.
- Bousquet G, Charmion L, Passot JP, et al. Stabilisation du condyle externe du genou dans les laxites anterieures chroniques. *Rev Chir Orthop Reparatrice Appar Mot.* 1986;72:427-434.
- Clancy WG. Repair and reconstruction of the posterior cruciate ligament. In: Chapman M, ed. *Operative Orthopaedics.* Philadelphia, Pa: JB Lippincott; 1988:1651-1655.
- Clancy WG, Sutherland TB. Combined posterior cruciate ligament injuries. *Clin Sports Med.* 1994;13:629-647.
- Cooper DE. Tests for posterolateral instability of the knee in normal subjects: results of examination under anesthesia. *J Bone Joint Surg Am.* 1991;73:30-36.
- Dye SF, Cannon WD. Anatomy and biomechanics of the anterior cruciate ligament. *Clin Sports Med.* 1988;17:715-725.
- Fanelli GC, Giannotti BF, Edson CJ. Arthroscopically assisted combined posterior cruciate ligament/posterior lateral complex reconstruction. *Arthroscopy.* 1996;12:521-530.
- Fleming RE, Blatz DJ, McCarroll JR. Posterior problems in the knee: posterior cruciate insufficiency and the posterolateral rotatory insufficiency. *Am J Sports Med.* 1981;9:107-113.
- Gollehon DL, Torzilli PA, Warren RF. The role of the posterolateral and cruciate ligaments in the stability of the human knee: a biomechanical study. *J Bone Joint Surg Am.* 1987;69:233-242.
- Grood ES, Stowers SF, Noyes FR. Limits of movement in the human knee: effects of sectioning the posterior cruciate ligament and posterolateral structures. *J Bone Joint Surg Am.* 1988;70:88-97.
- Grood ES, Suntay WJ. A joint coordinate system for the clinical description of three dimensional motions: application to the knee. *J Biomech Eng.* 1983;105:136-144.
- Harner CD, Vogrin TM, Höher J, et al. Biomechanical analysis of a posterior cruciate ligament reconstruction: deficiency of the posterolateral structures as a cause of graft failure. *Am J Sports Med.* 2000;28:32-39.
- Harner CD, Xerogeanes JW, Livesay GA, et al. The human posterior cruciate ligament complex: an interdisciplinary study. *Am J Sports Med.* 1995;23:736-745.
- Higgins H. The popliteus muscle. *J Anat.* 1894;29:569-573.
- Hughston JC, Andrews JR, Cross MJ, et al. Classification of knee ligament instabilities, part 2: the lateral compartment. *J Bone Joint Surg Am.* 1976;58:173-179.
- Hughston JC, Jacobson KE. Chronic posterolateral instability of the knee. *J Bone Joint Surg Am.* 1985;67:351-359.
- Hughston JC, Norwood LA Jr. The posterolateral drawer test and external rotation recurvatum test for posterolateral rotational instability of the knee. *Clin Orthop.* 1980;147:82-87.
- Jakob RP, Warner JP. Lateral and posterolateral rotatory instability of the knee. In: Jakob RP, Stäubli HU, ed. *The Knee and the Cruciate*

- Ligaments: Anatomy, Biomechanics, Clinical Aspects, Reconstruction, Complications, Rehabilitation.* New York, NY: Springer-Verlag; 1992:463-494.
21. Kannus P. Nonoperative treatment of grade II and III sprains of the lateral ligament compartment of the knee. *Am J Sports Med.* 1989;17:85-88.
 22. LaPrade RF. Arthroscopic evaluation of the lateral compartment of knees with grade 3 posterolateral knee complex injuries. *Am J Sports Med.* 1997;25:596-602.
 23. LaPrade RF. The medial collateral ligament complex and the posterolateral aspect of the knee. In: Arendt EA, ed. *OKU: Sports Medicine 2.* Rosemont, IL: American Academy of Orthopaedic Surgeons; 1999:327-340.
 24. LaPrade RF, Gilbert TJ, Bollom TS, et al. The magnetic resonance imaging appearance of individual structures of the posterolateral knee. *Am J Sports Med.* 2000;28:191-199.
 25. LaPrade RF, Hamilton CD. The fibular collateral ligament-biceps femoris bursa: an anatomic study. *Am J Sports Med.* 1997;25:439-443.
 26. LaPrade RF, Hamilton CD, Engebretsen L. Treatment of acute and chronic combined anterior cruciate ligament and posterolateral knee ligament injuries. *Sports Med Arthrosc Rev.* 1997;5:91-99.
 27. LaPrade RF, Ly TV, Wentorf FA, Engebretsen L. The posterolateral attachments of the knee: a qualitative and quantitative morphologic analysis of the fibular collateral ligament, popliteus tendon, popliteofibular ligament, and lateral gastrocnemius tendon. *Am J Sports Med.* 2003;31:854-860.
 28. LaPrade RF, Muench C, Wentorf FA, et al. The effect of injury to the posterolateral structures of the knee on force in a posterior cruciate ligament graft: a biomechanical study. *Am J Sports Med.* 2002;30:233-238.
 29. LaPrade RF, Resig S, Wentorf FA, Lewis JL. The effects of grade III posterolateral knee complex injuries on anterior cruciate ligament graft force. *Am J Sports Med.* 1999;27:469-475.
 30. LaPrade RF, Terry GC. Injuries to the posterolateral aspect of the knee: association of anatomic injury patterns with clinical instability. *Am J Sports Med.* 1997;25:433-438.
 31. Last RJ. Some anatomical details of the knee joint. *J Bone Joint Surg Br.* 1948;30:683-688.
 32. Latimer HA, Tibone JE, El Attrache NS, McMahon PJ. Reconstruction of the lateral collateral ligament of the knee with a patellar tendon allograft. *Am J Sports Med.* 1998;26:656-662.
 33. Lewis JL, Lew WD, Schmidt J. A note on application and evaluation of the buckle transducer for knee ligament force measurement. *J Biomech Eng.* 1982;104:125-128.
 34. Maynard MJ, Deng X, Wickiewicz TL, et al. The popliteofibular ligament: rediscovery of a key element in posterolateral stability. *Am J Sports Med.* 1996;24:311-316.
 35. Noyes FR, Barber-Westin SD. Surgical reconstruction of severe chronic posterolateral complex injuries of the knee using allograft tissues. *Am J Sports Med.* 1995;23:2-12.
 36. Noyes FR, Barber-Westin SD. Surgical restoration to treat chronic deficiency of the posterolateral complex and cruciate ligaments of the knee joint. *Am J Sports Med.* 1996;24:415-426.
 37. Noyes FR, Barber-Westin SD, Hewitt TE. High tibial osteotomy and ligament reconstruction for varus angulated anterior cruciate ligament deficient knees. *Am J Sports Med.* 2000;28:282-296.
 38. O'Brien SJ, Warren RF, Pavlov H, et al. Reconstruction of the chronically insufficient anterior cruciate ligament with the central third of the patellar ligament. *J Bone Joint Surg Am.* 1991;73:278-286.
 39. Seebacher JR, Inglis AE, Marshall JL, et al. The structure of the posterolateral aspect of the knee. *J Bone Joint Surg Am.* 1987;64:536-541.
 40. Stäubli HU, Birrer S. The popliteus tendon and its fascicles at the popliteus hiatus: gross anatomy and functional arthroscopic evaluation with and without anterior cruciate ligament deficiency. *Arthroscopy.* 1990;6:209-220.
 41. Sutton JB. On the nature of certain ligaments. *J Anat Physiol.* 1884;18:225-238.
 42. Terry GC, LaPrade RF. The posterolateral aspect of the knee: anatomy and surgical approach. *Am J Sports Med.* 1996;24:732-739.
 43. Trillat A. Posterolateral instability. In: Schulitz KP, Krahl H, Stein WH, ed. *Late Reconstruction of Injured Ligaments of the Knee.* Springer, Berlin; 1978:99-105.
 44. Veltri DM, Deng XH, Torzilli PA, et al. The role of the popliteofibular ligament in stability of the human knee: a biomechanical study. *Am J Sports Med.* 1994;24:460-472.
 45. Veltri DM, Warren RF. Anatomy, biomechanics, and physical findings in posterolateral knee instability. *Clin Sports Med.* 1994;13:599-613.
 46. Veltri DM, Warren RF. Operative treatment of posterolateral instability of the knee. *Clin Sports Med.* 1994;13:615-627.
 47. Wascher DC, Grauer JD, Markolf KL. Biceps tendon tenodesis for posterolateral instability of the knee. *Am J Sports Med.* 1993;21:400-406.