

Anatomic Suture Anchor Versus the Broström Technique for Anterior Talofibular Ligament Repair

A Biomechanical Comparison

Norman E. Waldrop III,^{*†} MD, Coen A. Wijdicks,^{*} PhD, Kyle S. Jansson,^{*} BS, Robert F. LaPrade,[†] MD, PhD, and Thomas O. Clanton,^{†‡} MD

Investigation performed at the Department of BioMedical Engineering of the Steadman Philippon Research Institute, Vail, Colorado

Background: Despite the popularity of the Broström procedure for secondary repair of chronic lateral ankle instability, there have been no biomechanical studies reporting on the strength of this secondary repair method, whether using suture fixation or suture anchors.

Hypothesis: The purpose of our study was to perform a biomechanical comparison of the ultimate load to failure and stiffness of the traditional Broström technique using only a suture repair compared with a suture anchor repair of the anterior talofibular ligament (ATFL) at time zero. We believed that fixation strength of the suture anchor repair would be closer to the strength of the native ligament and allow more aggressive rehabilitation.

Study Design: Controlled laboratory study.

Methods: Twenty-four fresh-frozen cadaveric ankles were randomly divided into 4 groups of 6 specimens. One group was an intact control group, and the other groups consisted of the traditional Broström and 2 suture anchor modifications (suture anchors in talus or fibula) of the Broström procedure. The specimens were loaded to failure to determine the strength and stiffness of each construct.

Results: In load-to-failure testing, ultimate failure loads of the Broström (68.2 ± 27.8 N; $P = .013$), suture anchor fibula (79.2 ± 34.3 N; $P = .037$), and suture anchor talus (75.3 ± 45.6 N; $P = .027$) repairs were significantly lower than that of the intact (160.9 ± 72.2 N) ATFL group. Stiffness of the Broström (6.0 ± 2.5 N/mm; $P = .02$), suture anchor fibula (6.8 N/mm ± 2.7 ; $P = .05$), and suture anchor talus (6.6 N/mm ± 4.0 ; $P = .04$) repairs were significantly lower than that of the intact (12.4 N/mm ± 4.1 N/mm) ATFL group. The 3 repair groups were not significantly different from each other, but all 3 were substantially lower in strength and stiffness when compared to the intact ATFL.

Conclusion: The use of suture anchors to repair the ATFL produces a repair that can withstand loads to failure similar to the suture-only Broström repair. However, all 3 repair groups were much weaker than the intact, uninjured ATFL.

Clinical Relevance: Biomechanically, the results show that both suture anchor and direct suture repair of the ATFL provide similar strength and stiffness. Unfortunately, these methods provide less than half the strength and stiffness of the native ATFL at time zero. As a result, regardless of the repair method, it is necessary to sufficiently protect the repair to avoid premature failure.

Keywords: Broström repair; lateral ankle instability; suture anchor repair; anterior talofibular ligament

[‡]Address correspondence to Thomas O. Clanton, MD, The Steadman Clinic, 181 W Meadow Dr, Suite 400, Vail, CO 81657 (email: tclanton@thesteadmanclinic.com).

^{*}Department of BioMedical Engineering, Steadman Philippon Research Institute, Vail, Colorado.

[†]The Steadman Clinic, Vail, Colorado.

One or more of the authors has declared the following potential conflict of interest or source of funding: cadaveric specimens, suture, and suture anchors were provided by Arthrex. Drs Clanton and LaPrade are consultants for Arthrex.

Lateral ankle instability is a common problem in the athletic population.^{4,11,19,30,31} Patients report a feeling of instability because of chronic laxity of the lateral ankle ligament complex, including the anterior talofibular ligament (ATFL) and the calcaneofibular ligament (CFL). Often treated successfully with nonoperative therapy, lateral ankle ligament complex injuries can be treated with nonsteroidal anti-inflammatory drugs, ice, elevation, and physical therapy, including a regimen of proprioceptive and muscle-strengthening exercises. However, it has been reported that in a large subset of these patients, nonoperative treatment does not succeed.²² Twenty to 25% of

patients fail to respond to nonoperative treatment and have continuing symptoms of functional or mechanical instability.^{13,21} The latter frequently requires surgical intervention to repair or reconstruct the lateral ankle ligaments and stabilize the ankle mortise.²²

In 1966, Broström described his secondary anatomic repair of the lateral ankle ligaments, specifically, the ATFL.^{7,8} Since then, there have been many adaptations to the originally described procedure, both anatomic and nonanatomic, which have had varying degrees of clinical success reported in the literature.^{6,12,14,15,21,22,24} Studies on nonanatomic reconstructions have reported excellent maintenance of stability with long-term follow-up, but these procedures have also resulted in long-term complications.^{3,5,9,10,25,28} The Broström procedure, along with the commonly included modification using an inferior extensor retinaculum reinforcement as described by Gould in 1980,¹⁵ is a standard for treating chronic lateral ankle instability because of its excellent clinical results with few complications.^{6,15,18}

Suture anchor repair of the lateral ankle ligamentous complex is a technique modification of the original Broström procedure that has gained popularity over the past several years. The technique is simple in design and well described, with excellent short- to midterm patient outcomes reported in the majority of cases.^{26,27} Despite its popularity as a method for ankle ligament repair, there have been no biomechanical data reported on the use of suture anchors for ATFL repairs at the ankle, nor is there biomechanical information for suture repair. The purpose of our study was to perform a biomechanical comparison of the ultimate load to failure and stiffness of the traditional Broström technique using a suture-only repair compared with a suture anchor repair of the ATFL. The data were then compared with the intact state to determine the mechanical properties of these repairs and how they would withstand the stresses of an aggressive rehabilitation program or rapid return to activities of daily living or sport participation. Our hypothesis was that the suture anchor repair of the anterior talofibular ligament would produce improved results compared with the standard Broström technique with respect to both load to failure and stiffness.

MATERIALS AND METHODS

Specimens

Twenty-four fresh-frozen human cadaveric ankle specimens were used. The average age of the cadavers was 58.4 years (range, 29-69 years). Cadavers were included if they had no prior ankle ligament tears or surgery. The criteria for exclusion in our specimens was age younger than 20 or older than 70 years, or any evidence of prior ankle injury by direct inspection. The cadavers were stored at -20°C and thawed at room temperature for 24 hours before use. The 24 cadaveric specimens were randomly assigned to each group for biomechanical comparison. Age distribution was similar among the 4 groups. Six served as the ATFL intact group, 6 served as the traditional Broström, 6 served as the suture anchor procedure with the anchor placed on the fibular side,

and 6 served as the suture anchor group with the anchor placed on the talar side. All repairs and dissections were performed by a single surgeon.

Surgical Procedure

A standard curvilinear incision was made anterior to the fibula starting 3 cm proximal to the ATFL insertion and extending along the distal anterior fibula. Dissection proceeded through skin and subcutaneous tissues, taking care to identify the inferior extensor retinaculum. Once identified, this structure was retracted, exposing the underlying ATFL. The capsular interval between the anterior inferior tibiofibular ligament and the ATFL was identified and opened, exposing the lateral shoulder of the talus. A curved hemostat was placed within the lateral ankle joint and passed under the lateral capsule and the ATFL, exiting just anterior to the peroneal tendon sheath. With use of a scalpel, the capsuloligamentous tissue from the interval between the anterior inferior tibiofibular ligament insertion and the peroneal tendon sheath near the distal tip of the fibula was divided to section the ATFL. The ATFL was divided in midsubstance for the traditional Broström technique, near the fibular insertion for the suture anchor fibula group, and near the talar neck insertion for the suture anchor talus group. (This division of the anterolateral capsule and ATFL is performed in a similar fashion by the surgeon at the time of a Broström repair and can be modified to duplicate any of the aforementioned locations. This method would prove useful if any of the 3 locations with subsequent fixation proved to be stronger once repaired.) The specimen was then tested clinically with the anterior drawer test to verify that anterior instability was created.

Broström Technique

The technique performed in the 6 suture-only specimens was similar to the anatomic repair technique originally described by Broström in 1966.⁸ The capsuloligamentous ends were identified after they were sectioned and inspected for tissue quality. Two No. 0 nonabsorbable, continuous braided polyethylene/polyester multifilament sutures (FiberWire, Arthrex Inc, Naples, Florida) were used to suture the ATFL ligament in a pants-over-vest fashion in an imbricated position (Figure 1). The foot was held in a slightly plantar flexed and everted position with a bump placed under the tibia, allowing the foot to reduce under the ankle mortise. The anterior drawer test was applied to each specimen to verify adequate repair and stability of the ankle mortise.

Suture Anchor Technique

The suture anchor repair technique was carried out in a manner similar to that described above. In 6 of the specimens, the ATFL was identified and divided adjacent to the fibular origin. Once the 2 cut ends were identified, the proximal end was dissected with a subperiosteal sleeve about 1 cm proximal to its insertion, exposing the distal fibula. The bony edge was roughened and one 3.0 mm \times 14.5 mm biocomposite (beta-tricalcium phosphate/poly[L-lactide-co-D,

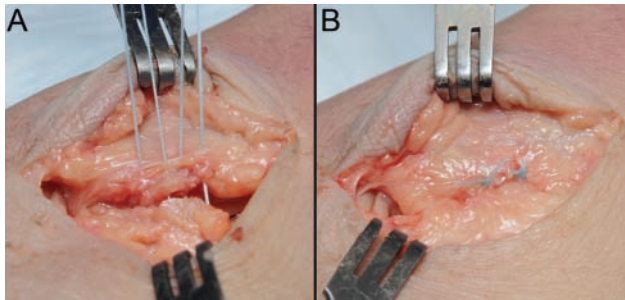


Figure 1. Broström repair (right ankle). (A) Two No. 0, nonabsorbable sutures were used to create a 4-stranded horizontal mattress repair of the ATFL near its origin on the distal fibula. (B) The final repair demonstrating the imbrication of the cut ATFL near its origin on the distal fibula.

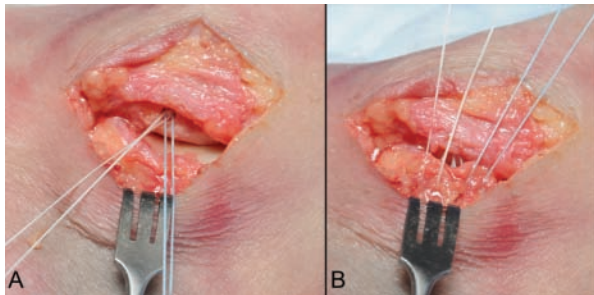


Figure 2. Suture anchor repair technique (right ankle). (A) Suture anchor placement at center of ATFL origin on the distal fibula, an average of 11 mm proximal to the distal tip of the fibula. Four No. 0, nonabsorbable sutures were used with each suture anchor. (B) Four strands of nonabsorbable suture placed through the cut ATFL.

L-lactide]) suture anchor (Bio-Suture Tak, Arthrex, Inc) was seated at the origin of the ligament. The suture anchors were placed an average of 11 mm proximal to the distal tip of the fibula (Figure 2). The suture anchor was loaded with 2 No. 0 nonabsorbable, continuous braided polyethylene/polyester multifilament sutures that were passed through the ligament and tied over the top in a purse string manner (Figure 2).

In the final 6 specimens, the ATFL was identified in a similar manner and cut near the talar neck insertion. The remnant of the ATFL insertion on the talus was identified and elevated, exposing the lateral portion of the talar neck. A single biocomposite (beta-tricalcium phosphate/poly[L-lactide-co-D, L-lactide]) 3.0 mm × 14.5 mm suture anchor (Bio-Suture Tak, Arthrex, Inc) was placed at the cartilaginous edge of the lateral talar shoulder (Figure 3). The 2 No. 0 nonabsorbable, continuous braided polyethylene/polyester multifilament sutures were passed through the ligament and tied over the top in a manner similar to that used above (Figure 3). The ankles were once again tested with an anterior drawer test to confirm adequate repair and stability of the ankle. Anchor placement is demonstrated in Figure 4.

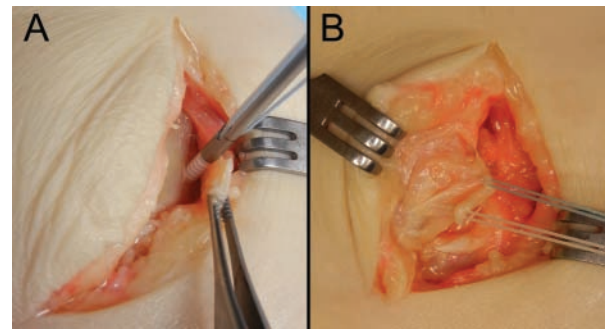


Figure 3. (A) Suture anchor repair technique originating from the lateral shoulder of the talus (right ankle). (B) Four strands of nonabsorbable suture placed through the cut ATFL.

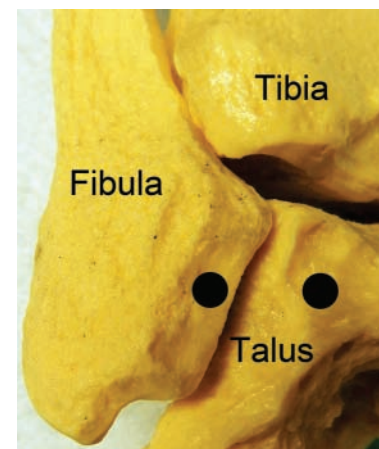


Figure 4. Synthetic bone model demonstrates the anchor placement for both suture anchor groups.

Isolation of the ATFL

In all specimens, the ATFL was isolated with a standard technique. The soft tissues were completely stripped from the tibia and fibula, except for the ATFL attachment from the distal fibula to the lateral talar neck. The muscle attachments of the tibia and fibula were completely removed. The foot was left completely intact with the skin present. An elliptical incision was made across the midfoot, extending around posteriorly to the Achilles tendon insertion. Once the soft tissues were removed, the deltoid ligament, the anterior capsule, and the posterior capsule were incised, leaving only the lateral ligaments intact. The syndesmosis ligaments, posterior talofibular ligament, and the CFL were then cut and the tibia was removed, leaving only the fibula and the ATFL isolated in all 24 specimens.

Specimen Preparation

After the repairs were performed and the ATFL was isolated, a 5-mm Steinmann pin was placed medial to lateral through the proximal fibula to ensure that the ATFL would




Figure 5. (A) Example of left synthetic bone model in testing device. (B) Left ankle specimen secured to the Instron E10000 machine before testing. The foot was placed in 20° of inversion and 10° of plantar flexion to replicate the position of cephalad tension of the ATFL.

be pulled in line with the load actuator applied by a dynamic tensile testing machine (Instron E10000 ElectroPuls Dynamic Testing System, Instron Systems, Norwood, Massachusetts). A screw was inserted across the subtalar joint to rigidly secure it in place and eliminate any rotational forces through the foot. A custom jig was designed to place the foot in 20° of inversion and 10° of plantar flexion, to replicate the position of tension of the ATFL and provide a worst-case scenario of biomechanical testing. The foot was rigidly secured in place with a metal foot strap across the dorsum of the foot. Inferior, medial, and posterior rigid supports were used to constrain the foot and prevent motion. Care was taken to ensure the fibula was vertically in line with the actuator axis, and the construct was mounted to the Instron base (Figure 5).

Biomechanical Testing

The Instron E10000 dynamic tensile testing machine, which has previously been calibrated to a load accuracy of $\pm 0.25\%$ of the applied load, was used for the biomechanical testing. A tensile load was gradually applied with a preload of 15 N for 10 seconds. Then the load was held at 15 N for 5 seconds to remove potential creep. The ligament was then loaded to failure, with the actuator pulling the fibula at a rate of 20 mm/min (Figure 6). The ultimate load was defined as the maximum endured load during testing. Stiffness was calculated as the slope of the linear region of the load-elongation curve corresponding to the steepest straight-line tangent to the curve. The tendon and repair sites were moistened throughout the experiment. Studies have shown that as specimens dry out, the biomechanical characteristics of the tissues may change in a negative way.¹⁷ The data were recorded by Instron WaveMatrix software (Instron Systems). These measurements were analyzed and plotted with Microsoft

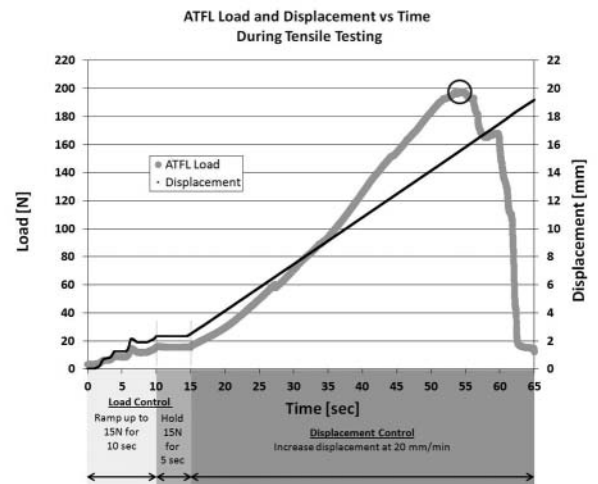


Figure 6. Anterior talofibular ligament load and displacement versus time during tensile testing. The anterior talofibular ligament load was for an intact specimen (No. 6; 197.7 N ultimate load). The circle represents the ultimate failure point.

Excel software to calculate stiffness and to find the ultimate load at failure (Microsoft Inc, Seattle, Washington).

Statistical Analysis

Statistical analysis was performed with the use of Predictive Analytics Software (PASW; Statistics Version 18, IBM Corporation, Armonk, New York). The study compared data for each group using a 1-way analysis of variance (ANOVA). For ANOVAs that demonstrated a statistically significant difference, a post hoc Tukey Honestly Significant Difference test was conducted to assess the location of the means that were statistically significant between the groups. Significant difference was determined to be present for $P < .05$.

RESULTS

In load-to-failure testing, the ultimate failure loads of the Broström (68.2 ± 27.8 N; $P = .013$), suture anchor fibula (79.2 ± 34.3 N; $P = .037$), and suture anchor talus (75.3 ± 45.6 N; $P = .027$) repairs, were significantly lower than that of the intact (160.9 ± 72.2 N) ATFL group (Figure 7 and Table 1). The 3 repair groups were not significantly different.

Stiffness of the Broström (6.0 ± 2.5 N/mm; $P = .02$), suture anchor fibula (6.8 ± 2.7 N/mm; $P = .05$), and suture anchor talus (6.6 ± 4.0 N/mm; $P = .04$) repairs was significantly lower than that of the intact (12.4 ± 4.1 N/mm) ATFL group (Table 1). The 3 repair groups were not significantly different.

The mechanism of failure was at the ligament-suture interface for all specimens in all 3 repair groups (Table 1). The mechanism of failure for the intact state was predominantly

TABLE 1
Ultimate Failure Load, Stiffness, and Mechanism of Failure for Each Specimen

Group	Ultimate Failure Load, N	Stiffness, N/mm	Mechanism of Failure
Intact No. 1	80.2	9.5	Distal avulsion
Intact No. 2	183.1	11.9	Distal avulsion
Intact No. 3	124.1	8.6	Midsubstance tear
Intact No. 4	104.8	9.3	Distal avulsion
Intact No. 5	275.7	17.4	Midsubstance tear
Intact No. 6	197.7	17.5	Distal avulsion
Broström No. 1	64.1	5.8	Ligament-suture interface
Broström No. 2	107.8	5.4	Ligament-suture interface
Broström No. 3	46.3	5.5	Ligament-suture interface
Broström No. 4	51.2	3.6	Ligament-suture interface
Broström No. 5	42.6	4.7	Ligament-suture interface
Broström No. 6	97.3	10.8	Ligament-suture interface
Suture anchor (fibula) No. 1	45.8	2.4	Ligament-suture interface
Suture anchor (fibula) No. 2	53.3	5.7	Ligament-suture interface
Suture anchor (fibula) No. 3	143.0	10.7	Ligament-suture interface
Suture anchor (fibula) No. 4	73.9	7.1	Ligament-suture interface
Suture anchor (fibula) No. 5	79.8	8.1	Ligament-suture interface
Suture anchor (fibula) No. 6	79.2	6.9	Ligament-suture interface
Suture anchor (talus) No. 1	44.5	3.3	Ligament-suture interface
Suture anchor (talus) No. 2	60.6	5.3	Ligament-suture interface
Suture anchor (talus) No. 3	158.8	11.0	Ligament-suture interface
Suture anchor (talus) No. 4	31.4	2.2	Ligament-suture interface
Suture anchor (talus) No. 5	90.9	11.7	Ligament-suture interface
Suture anchor (talus) No. 6	65.5	6.2	Ligament-suture interface

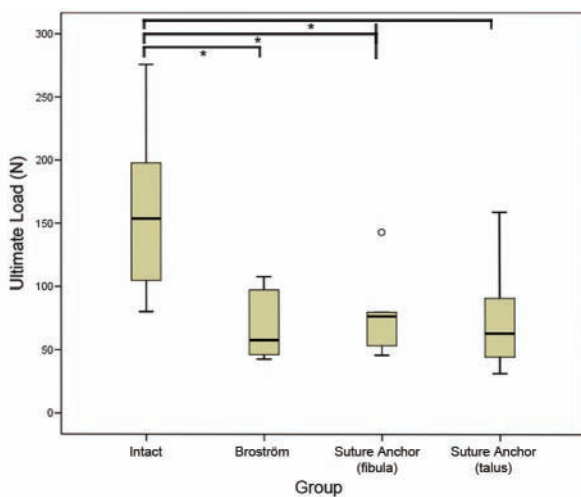


Figure 7. Box plot representing the ultimate load to failure, in Newtons, per group. The horizontal line indicates the median, the box extends from the 25th to the 75th percentile, and the bars indicate the largest and smallest observed value. Asterisk represents significant difference. $P \leq .05$.

at the distal attachment site (4 of 6 specimens), whereas the remaining 2 failed midsubstance (Table 1).

DISCUSSION

We found that suture anchor repair of the ATFL, regardless of fibular or talar location, was just as effective as

the Broström technique for restoring the strength of the ATFL. From our literature review, there has been no biomechanical analysis of the ultimate load to failure or stiffness of either the Broström procedure or the suture anchor modifications. We demonstrate that the 3 methods are equal with respect to ultimate failure and stiffness; however, they are significantly weaker than the intact state. When comparing our results with the only biomechanical study that examined mechanical properties of the intact ATFL, our intact state (160.9 N) was similar to that of the previously published study (138.9 N).¹ Since our results indicate a strength of repair ranging from 42% to 49% of the intact ligament, it illustrates the importance of protection from excessive stress for these repairs during the early postoperative rehabilitation phase.

The Broström procedure is a proven surgical technique for the repair of the lateral ankle ligament complex. The procedure, originally described in 1966, is based on an anatomic repair of a torn or attenuated ATFL ligament.⁸ Clinical outcome studies suggest 90% to 95% good to excellent outcomes over the long term.⁶ Each of the series reporting these results recommends postoperative immobilization in a short leg walking cast for 4 to 6 weeks.^{14-16,18,20-22,32} Although the procedure has proven to be successful at restoring stability and function, there have been many widely accepted modifications to the procedure, including the extensively used Gould modification of reinforcing the repair with the overlying inferior extensor retinaculum.¹⁵ This modification has been reported to add strength to the Broström repair.² Other modifications include the use of suture anchors placed at the origin of the ATFL on the distal fibula to repair the ligament back to its bony

insertion.²⁷ As suture anchor technology has improved, this technique has become more popular.

Good clinical outcomes have been reported with the use of suture anchors to repair the lateral ligaments of the ankle.²⁷ Our results demonstrate that suture anchor fixation is an effective, simple modification of the technique with reliable results that are equivalent to the standard suture method for the Broström. It has also been reported that there are few complications associated with the use of suture anchors and the patient can expect a return to pre-injury functional levels.^{26,27,29} Despite these good clinical results, there has been a paucity of literature on the biomechanics of suture anchor usage in the ankle, including whether they are as effective as suture alone in their strength of repair.

This biomechanical study represents a worst-case scenario in presenting the strength of the repair at time zero. Because we have demonstrated that the initial repair, whether by suture or suture anchor, is significantly weaker than the intact state, any motion that overstresses the repair should be minimized or avoided in the early postoperative period. Although we do not know how strong a repair needs to be to withstand aggressive early rehabilitation, we would submit that less than 50% is probably not the answer and probably does not meet the criteria of releasing a patient to unprotected activity, aggressive range-of-motion, weight training, proprioceptive exercises, or agility drills before some adequate period of healing has taken place. As Kirk et al reported in their biomechanical study,²³ unprotected motion of the ankle after the Broström procedure results in elongation of ATFL after repair. The typical postoperative protocol with 4 to 6 weeks in a short leg walking cast has proven to be successful in prior studies.^{14-16,18,20-22,32} Without healing to restore strength, the repair could be compromised, but modern rehabilitation methods promote protected motion and early weight-bearing. To allow this rehabilitation, reconstructive procedures at other joints have focused on improving the strength of the initial repair. Such methods have been advocated for the ankle as well,^{21,22,32} but to adequately assess their validity, it is requisite that there be a means of comparing strength against the intact state and against the standard repair method. This study provides that foundational information from which to compare other methods for strengthening the traditional Broström procedure.

This study does have limitations. The average age of the cadavers was 58.4 years and extended up to age 69, which is old in terms of patients who typically sustain lateral ankle sprains and require surgical stabilization. The tissue quality in these individuals may not be as good as one would expect in patients presenting with lateral ankle instability. The study is a "worst-case" scenario since it looks only at strength of the repair at time zero. It is likely that there will be improved strength as the ligament repair heals and goes through the typical tissue maturation process, but this possibility would require an entirely different study design to evaluate strength of repair at various time intervals. The sample size for each group may be seen as small at 6, however, our statistical analysis defined

a reasonable confidence interval. We tested only 1 type of suture anchor with 1 type of suture. It is conceivable that a different anchor with a different suture might have produced a different outcome.

CONCLUSION

The use of suture anchors to repair the ATFL produces a repair that can withstand loads to failure similar to that of the suture-only Broström repair. However, all 3 repair groups in our study were over 50% weaker than the intact, uninjured ATFL. This finding certainly leaves room for improvement in surgical reinforcement of the repair, because it is evident that repairs rely heavily on the healing of the tissues to regain strength. Likewise, it is likely that aggressive rehabilitation would be unwise. Biomechanically, the results validate using suture anchors as an alternative method to repair the ATFL in patients with lateral ankle instability when the surgical situation dictates such usage. The surgeon can use the suture anchor technique with confidence knowing that the repair is as strong as that achieved by the traditional Broström procedure. Either method requires a period of immobilization and protected rehabilitation to avoid failure of the repair.

ACKNOWLEDGMENT

The authors thank Kelly Adair for his surgical skills and Sharon Wood for her assistance.

REFERENCES

- Attarian DE, McCrackin HJ, Devit DP, McElhaney JH, Garrett WE Jr. A biomechanical study of human lateral ankle ligaments and autogenous reconstructive grafts. *Am J Sports Med.* 1985;13:377-381.
- Aydogan U, Glisson RR, Nunley JA. Extensor retinaculum augmentation reinforces anterior talofibular ligament repair. *Clin Orthop Relat Res.* 2006;442: 210-215.
- Bahr R, Pena F, Shine J, Lew WD, Tyrdal S, Engebretsen L. Biomechanics of ankle ligament reconstruction: An in vitro comparison of the Broström repair, Watson-Jones Reconstruction, and a new anatomic reconstruction technique. *Am J Sports Med.* 1997;25:424-432.
- Barker HB, Beynon BD, Renstrom PA. Ankle injury risk factors in sports. *Sports Med.* 1997;23:69-74.
- Becker HP, Ebner S, Ebner D, et al. 12-year outcome after modified Watson-Jones tenodesis for ankle instability. *Clin Orthop Relat Res.* 1999;358:194-204.
- Bell SJ, Mologne TS, Sittler DF, Cox JS. Twenty-six-year results after Broström procedure for chronic lateral ankle instability. *Am J Sports Med.* 2006;34:975-978.
- Broström L. Sprained ankles. V. Treatment and prognosis in recent ligament ruptures. *Acta Chir Scand.* 1966;132:537-550.
- Broström L. Sprained ankles. VI. Surgical treatment of "chronic" ligament ruptures. *Acta Chir Scand.* 1966;132:551-565.
- Colville MR, Marder RA, Zarins B. Reconstruction of the lateral ankle ligaments: a biomechanical analysis. *Am J Sports Med.* 1992;20:594-600.
- Evans D. Recurrent instability of the ankle: A method of surgical treatment. *Proc R Soc Med.* 1953;46:343-344.
- Ferran NA, Maffulli N. Epidemiology of sprains of the lateral ankle ligament complex. *Foot Ankle Clin.* 2006;11:659-662.

12. Fujii T, Kitaoka HB, Watanabe K, Luo ZP, An KN. Comparison of modified Broström and Evans procedures in simulated lateral ankle injury. *Med Sci Sports Exerc.* 2006;38:1025-1031.
13. Gerber JP, Williams GN, Scoville CR, Arciero RA, Taylor DC. Persistent disability associated with ankle sprains: a prospective examination of an athletic population. *Foot Ankle Int.* 1998;19:653-660.
14. Girard P, Anderson RB, Davis WH, Isear JA, Kiebzak GM. Clinical evaluation of the modified Broström Evans procedure to restore ankle stability. *Foot Ankle Int.* 1999;20:246-252.
15. Gould N, Seligson D, Gassman J. Early and late repair of the lateral ligament of the ankle. *Foot Ankle.* 1980;1:84-89.
16. Hamilton WG, Thompson FM, Snow SW. The modified Brostrom procedure for lateral ankle instability. *Foot Ankle Int.* 1993;14:1-7.
17. Haut RC, Powlison AC. The effects of test environment and cyclic stretching on the failure properties of human patellar tendons. *J Orthop Res.* 1990;8:532-540.
18. Hennrikus WL, Mapes RC, Lyons PM, Lapoint JM. Outcomes of the Chrisman-Snook and modified Broström procedure for chronic lateral ankle instability. A prospective, randomized comparison. *Am J Sports Med.* 1996;24:400-404.
19. Holmer P, Sondergaard L, Konradsen L, Nielsen PT, Jorgensen LN. Epidemiology of sprains in the lateral ankle and foot. *Foot Ankle Int.* 1994;15:72-74.
20. Javors JR, Violet JT. Correction of chronic lateral ligament instability of the ankle by the use of the Brostrom procedure. A report of 15 cases. *Clin Orthop Relat Res.* 1985;198:201-207.
21. Karlsson J, Bergsten T, Lansinger O, Peterson L. Reconstruction of the lateral ligaments of the ankle for chronic instability. *J Bone Joint Surg.* 1988;70:581-588.
22. Karlsson J, Eriksson BI, Bergsten T, Rudholm O, Sward L. Comparison of two anatomic reconstructions for chronic lateral instability of the ankle joint. *Am J Sports Med.* 1997;25:48-53.
23. Kirk KL, Campbell JT, Guyton GP, Parks BG, Schon LC. ATFL elongation after Broström procedure: a biomechanical investigation. *Foot Ankle Int.* 2008; 29:1126-1130.
24. Konradsen L, Bech L, Ehrenbjerg M, Nickelsen T. Seven years follow-up after ankle inversion trauma. *Scand J Med Sci Sports.* 2002;12:129-135.
25. Korkala O, Tanskanen P, Makijarvi J, Sorvali T, Ylikoski M, Haapala J. Long-term results of the Evans procedure for lateral instability of the ankle. *J Bone Joint Surg Br.* 1991;73:96-99.
26. Li X, Killie H, Guerrero P, Busconi BD. Anatomical reconstruction for chronic lateral ankle instability in the high-demand athlete: Functional outcomes after the modified Broström repair using suture anchors. *Am J Sports Med.* 2009;37:488-494.
27. Messer TM, Cummins CA, Ahn J, Kelikian AS. Outcome of the modified Broström procedure for chronic lateral ankle instability using suture anchors. *Foot Ankle Int.* 2000;21:996-1003.
28. Rosenbaum D, Becker HP, Wilke HJ, Claes LE. Tenodeses destroy the kinematic coupling of the ankle joint complex: a three dimensional in-vitro analysis of joint movement. *J Bone Joint Surg Br.* 1998;80:162-168.
29. Shahrolazua A, Ariff Sukimin MS, Tengku Muzaffar TMS, Yusof MI. Early functional outcome of a modified Broström-Gould surgery using bioabsorbable suture anchor for chronic lateral ankle instability. *Singapore Med J.* 2010;51:235-241.
30. Waterman BR, Belmont PJ Jr, Cameron KL, DeBerardino TM, Owens BD. Epidemiology of ankle sprain at the United States Military Academy. *Am J Sports Med.* 2010;38:797-803.
31. Waterman BR, Owens BD, Davey S, Zacchilli MA, Belmont PJ Jr. The epidemiology of ankle sprains in the United States. *J Bone Joint Surg Am.* 2010;92:2279-2284.
32. Zwipp H. Treatment of chronic, two-plane instability of the ankle joint: syndesmoplasty versus periosteal flap versus tenodesis. *J Foot Surg.* 1990;29:3-12.

For reprints and permission queries, please visit SAGE's Web site at <http://www.sagepub.com/journalsPermissions.nav>