ROBERT F. LAPRADE, MD, PhD[1] • COEN A. WIJDICKS, PhD[2]

The Management of Injuries to the Medial Side of the Knee

The injury incidence of the superficial medial collateral ligament (MCL) and other medial knee stabilizers (the deep MCL and the posterior oblique ligament) has been reported to be 0.24 per 1000 people in the United States in any given year[19] and to be twice as high in males (0.36) compared to females (0.18).[19] The majority of medial knee ligament tears are isolated injuries, affecting only the medial stabilizers of the knee. These injuries occur predominantly in young individuals participating in sport activities. The mechanism of injury typically involves valgus knee loading, tibial external rotation, or a combined force vector of valgus loading and external rotation that occurs in such sports as skiing, ice hockey, and soccer, which require knee flexion.[17,20,25] The vast majority of grade III (complete tear) medial knee injuries do heal; however, some do not, which can lead to chronic instability and functional limitations.

Much of the information about the anatomy, diagnosis, and treatment of medial knee injuries is historical. More recently, it has been recognized that there is more to the medial knee structures than just the medial collateral ligament. There are several important individual structures that provide medial knee stability, which, when injured, can result in functional limitations. Recent anatomic studies defining the attachment sites of these structures have led to further advancements in the understanding of clinically relevant biomechanics and diagnostic techniques.[4,7,8,14,27] Furthermore, these studies have helped to develop new anatomic reconstruction techniques.[4] Overall, increased knowledge of these areas has led to a more functional rehabilitation program, resulting in improved patient outcomes. The following clinical commentary reviews recent updates regarding medial knee anatomy, clinically relevant biomechanics, improved diagnostic techniques, treatment of medial knee injuries, and nonsurgical and surgical rehabilitation principles for medial knee injuries.

SYNOPSIS: Injuries to the medial side of the knee are the most common knee ligament injuries. The majority of injuries occur in young athletes during sporting events, with the usual mechanism involving a valgus contact, tibial external rotation, or a combined valgus and external rotation force delivered to the knee. Although most complete grade III medial knee injuries heal, some do not, which can lead to continued instability. For these patients, a thorough understanding of the presenting history and a physical examination are important because these injuries can often be confused with posterolateral corner injuries. The main anatomic structures of the medial side of the knee are the superficial medial collateral ligament, deep medial collateral ligament, and posterior oblique ligament. In addition, accurately locating 3 bony prominences over the medial aspect of the knee—the adductor tubercle, gastrocnemius tubercle, and medial epicondyle—is important to conduct a proper physical examination and for surgical repairs and reconstructions. Clinical diagnosis of medial knee injuries is primarily performed via the application of a valgus stress in full extension and at 30° of knee flexion. In addition, an examination of the amount of anteromedial tibial rotation is performed at 90° of flexion, while the dial test, performed at 30° and 90° of flexion, is important because it evaluates for rotational abnormalities. Valgus stress radiographs are useful to objectively determine the amount of medial compartment gapping and to discern whether there is medial or lateral compartment gapping when a medial or posterolateral corner knee injury cannot be differentiated, especially with a chronic injury. The majority of acute grade III medial knee injuries will heal after a nonoperative rehabilitation program. In most instances when there is a knee dislocation or multiligament injury, a primary repair with sutures may be indicated. In severe midsubstance injuries or chronic medial knee injuries, an anatomic medial knee reconstruction with grafts may be indicated. Rehabilitation principles for acute medial knee injuries involve controlling edema, regaining range of motion, and avoiding any significant stress on the healing ligaments. A well-guided rehabilitation program can result in excellent functional outcomes in the majority of patients.
J Orthop Sports Phys Ther 2012;42(3):221-233. doi:10.2519/jospt.2012.3624

KEY WORDS: *MCL, medial collateral ligament, posterior oblique ligament, rehabilitation, surgery, valgus injury*

[1]Chief Medical Research Officer, Steadman Philippon Research Institute, Vail, CO; Complex Knee Surgeon, The Steadman Clinic, Vail, CO. [2]Director and Senior Staff Scientist, Biomechanics Research Department, Steadman Philippon Research Institute, Vail, CO. This work was supported by the Research Council of Norway (grant 175047/D15) and Health East Norway (grant 10703604). Address correspondence to Dr Robert F. LaPrade, Chief Medical Research Officer, Steadman Philippon Research Institute, 181 West Meadow Drive, Suite 400, Vail, CO 81657. E-mail: drlaprade@sprivail.org

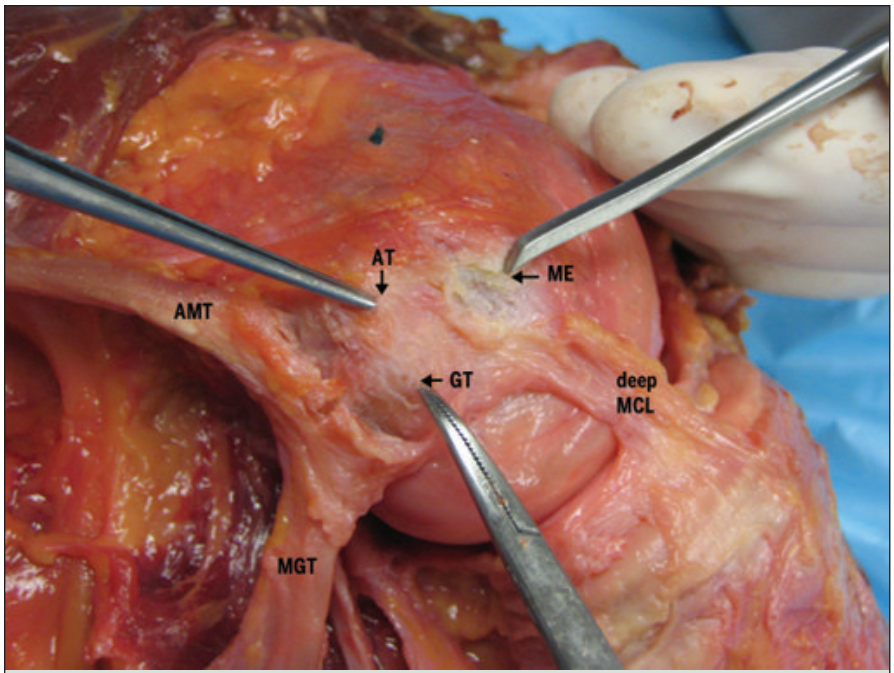

FIGURE 1. Photograph of a left knee, demonstrating the ME, AT, and GT. The attachments of the AMT and the MGT have been peeled back, while the superficial medial collateral ligament has been removed to demonstrate the deep MCL. Abbreviations: AMT, adductor magnus tendon; AT, adductor tubercle; GT, gastrocnemius tubercle; MCL, medial collateral ligament; ME, medial epicondyle; MGT, medial gastrocnemius tendon.

ANATOMY OF THE MEDIAL ASPECT OF THE KNEE

Bony Landmarks

There are 3 separate bony prominences over the medial aspect of the knee. It is important to recognize the locations of these structures to define the region of anatomic injury and surgically repair the knee (**FIGURE 1**). The medial epicondyle is the most distal and anterior of these 3 bony landmarks. The superficial MCL attaches slightly proximal and posterior to this bony prominence. The adductor tubercle is the most proximal of the 3 bony landmarks. It is located just distal to the attachment of the adductor mangus tendon and parallel to the medial epicondyle along the femoral diaphysis. The gastrocnemius tubercle is the furthest posterior of the 3 bony landmarks and can be the most prominent. The medial gastrocnemius tendon is located slightly proximal to the gastrocnemius tubercle, while the posterior oblique ligament is located slightly distal and posterior to the tubercle.

Superficial MCL

The superficial MCL is the largest and most important structure on the medial aspect of the knee. It has 1 attachment on the femur and 2 attachments on the tibia.[14] The 2 tibial attachments divide the superficial MCL into 2 functionally different sections.[7,8] It is important to recognize these attachment sites because injuries to different sections of the superficial MCL can result in valgus, external rotation, or anteromedial rotatory instability (**FIGURE 2**).

The femoral attachment site of the superficial MCL is slightly proximal and posterior to the medial epicondyle. It is important to recognize that it does not attach directly to the medial epicondyle. The superficial MCL then courses distally to its proximal tibial attachment, located just over 1 cm distal to the joint line, and is primarily connected to soft tissues. The more distal tibial attachment, which is located approximately 6 cm distal to the joint line, is attached directly to bone and is the stronger attachment site of the two. Most of the distal attachment of the superficial MCL is within the confines of the pes anserine bursa.

Deep MCL

The deep MCL is not a distinct structure but rather a thickening of the joint capsule deep to the superficial MCL.[14] Its attachment site on the femur is just over 1 cm distal to that of the superficial MCL. The deep MCL courses distally to attach to the medial meniscus and then continues to its tibial attachment site, approximately 3 to 4 mm distal to the joint line. Due to its stout meniscal attachment, it has 2 distinct functional units, the meniscofemoral and meniscotibial divisions (**FIGURE 3**).

Posterior Oblique Ligament

The posterior oblique ligament is one of the most misunderstood structures of the medial aspect of the knee. In the older literature, it was often called the oblique portion of the superficial MCL. It has been noted to have several components, the most important of which is the central arm,[8,14] which is the largest and thickest portion of the posterior oblique ligament. The central arm is a fibrous extension off the distal aspect of the semimembranosus tendon that blends with and reinforces the posteromedial joint capsule (**FIGURE 4**). Thus, the posterior oblique ligament is not a separate structure but rather a thickening of the posteromedial joint capsule, which extends from the semimembranosus tendon to its femoral attachment, located slightly distal and anterior to the gastrocnemius tubercle on the posteromedial aspect of the femur.

Adductor Magnus Tendon

The adductor magnus tendon attachment site on the femur is an important surgical landmark because the tendon is not frequently injured, and its attachment site can serve as a reference for identifying the femoral attachment sites of the posterior oblique ligament and superficial MCL. The adductor magnus tendon does not attach directly to the adductor tubercle but rather to a small bony depression

approximately 3 mm posterior and 2.7 mm proximal to the adductor tubercle.[14]

Medial Gastrocnemius Tendon

The femoral attachment site of the medial gastrocnemius tendon is another important landmark to identify on the medial aspect of the knee. The tendon forms at the medial edge of the medial gastrocnemius muscle belly,[14] and then attaches slightly proximal and posterior to a bony depression adjacent to the gastrocnemius tubercle. Thus, the attachment site of the medial gastrocnemius tendon is useful to identify the gastrocnemius tubercle as well as the attachment of the posterior oblique ligament, especially when there is a chronic injury or previous surgery, which can obliterate the normal anatomic landmarks in this area.

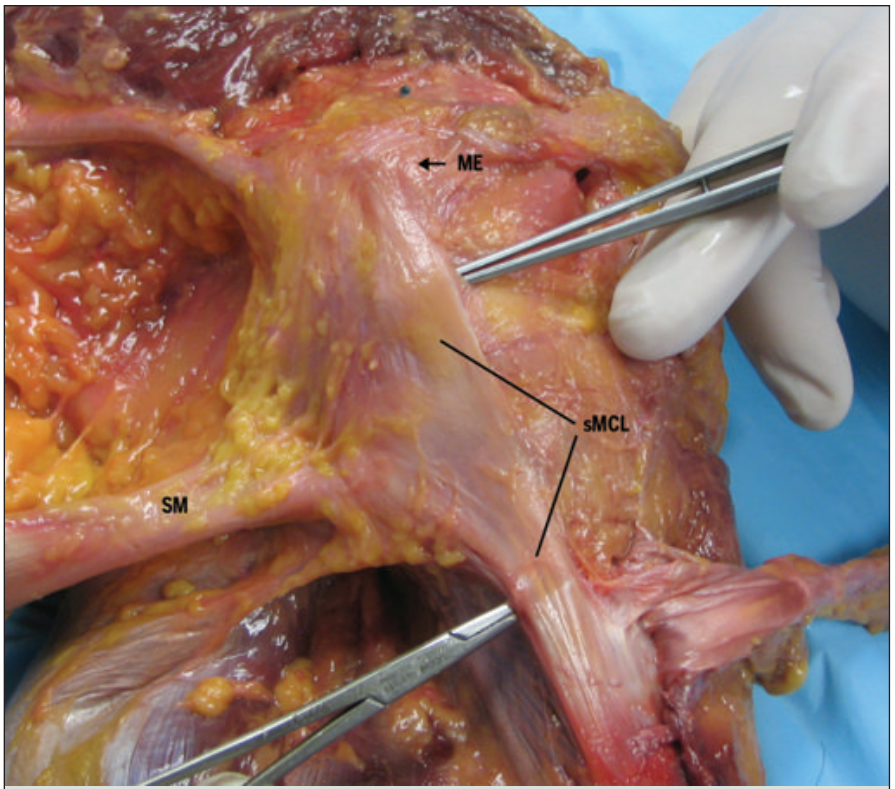

FIGURE 2. Photograph of a left knee demonstrating the course of the superficial medial collateral ligament. Abbreviations: ME, medial epicondyle; SM, semimembranosus tendon; sMCL, superficial medial collateral ligament.

CLINICALLY RELEVANT BIOMECHANICS OF MEDIAL KNEE INJURIES

It is important to understand medial knee biomechanics to correctly interpret the motion instabilities associated with medial knee injuries. In addition, understanding abnormal motion during knee examination will help to identify injured structures.

Static cutting studies of the individual components of the primary medial knee structures have revealed an important and intricate relationship between the medial knee structures and applied loads.[27] In addition, it has been demonstrated that the superficial MCL has 2 important functional components.[8] The more proximal division, coursing from the femur to the proximal tibial attachment site, is important for valgus stability, while the more distal division, with attachment sites over the tibia, is more important for external rotational stability.[7,24,27] While the superficial MCL serves as the primary static stabilizer, there are other important structures that provide secondary valgus stability when the superficial MCL is injured (eg, the meniscofemoral and meniscotibial divisions of the deep MCL).[7,24]

Static-cutting studies have also demonstrated that the medial knee structures are important to provide external rotational stability to the knee.[27] This is clinically important because it is commonly believed that patients with increased external rotation have posterolateral corner injuries; however, these studies have revealed that there can be just as much external rotational instability in a medial knee structure injury as there can be in a posterolateral corner injury.[27] The primary medial knee stabilizer during external rotation at 30° of knee flexion is the distal division of the superficial MCL. Secondary external rotation stabilizers, which are activated when the distal division of the superficial MCL is injured, comprise the proximal portion of the superficial MCL, the meniscofemoral division of the deep MCL, and the posterior oblique ligament.[7,24,27]

The medial knee structures also provide internal rotational stability to the knee. The posterior oblique ligament is important at all knee flexion angles, but especially in full knee extension.[8] The meniscofemoral division of the deep MCL and the distal division of the superficial MCL are also important internal rotation stabilizers.[8] The proximal division of the superficial MCL and the meniscotibial division of the deep MCL also are secondary internal rotation stabilizers.

In addition to the important static stabilizing function of the medial knee structures, a study that applied buckle transducers to these structures revealed an important load-sharing distribution between the superficial MCL and posterior oblique ligament (**FIGURE 5**).[8] This study demonstrated that the superficial MCL has the largest load response to applied valgus and external rotation torques, while the posterior oblique ligament experiences the greatest load when an internal rotation torque is applied

near full knee extension.

The results of these quantitative, anatomic, and clinically relevant biomechanical studies were used to develop an anatomic medial knee reconstruction technique that reconstructs the 2 divisions of the superficial MCL and the posterior oblique ligament.[4] Data from sectioning studies with buckle transducers attached to the reconstruction grafts indicate that anatomic reconstruction restores native stability to the medial knee and does not result in overconstraint, which could lead to overloading of the grafts and their eventual failure. The data also demonstrate that the normal load-sharing relationships among the medial knee structures were restored with this reconstruction technique (**FIGURE 6**).[4]

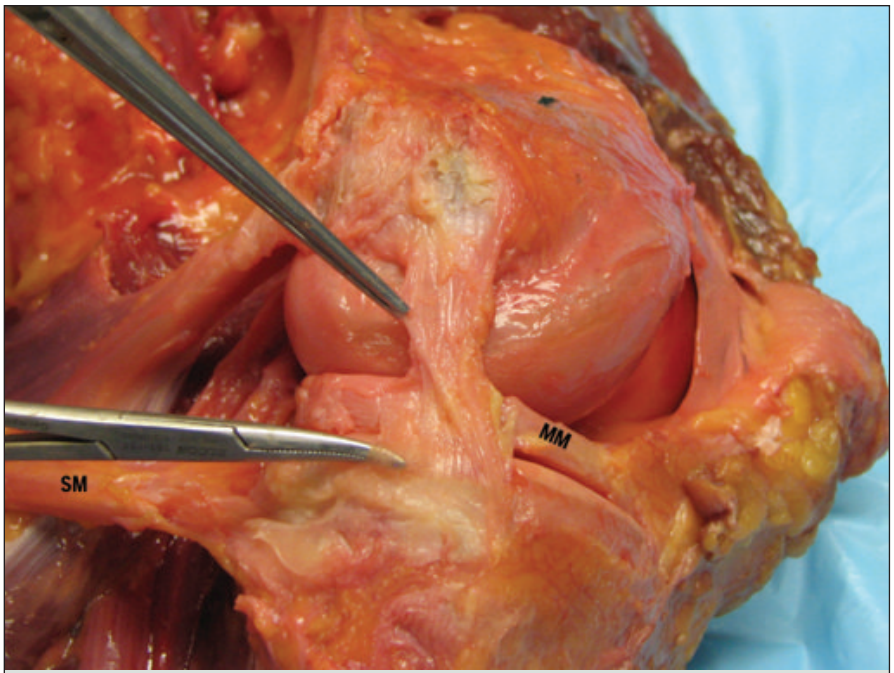

FIGURE 3. Photograph of the deep medial collateral ligament of a left knee. The superficial medial collateral ligament and the joint capsule anterior and posterior to the deep medial collateral ligament have been removed. The hemostat (bottom) is deep to the meniscofemoral portion of the deep medial collateral ligament, while the forceps (top) is holding the meniscotibial portion of the deep medial collateral ligament. Abbreviations: MM, medial meniscus; SM, semimembranosus tendon (anterior arm).

DIAGNOSIS OF MEDIAL KNEE INJURIES

History

Almost all patients with medial knee injuries present with a history of having sustained a contact or noncontact valgus stress to the knee. Localized pain and swelling along the meniscofemoral or meniscotibial division of the medial knee structures are sometimes reported. For athletes with grade III medial knee injuries, subjective complaints of side-to-side instability can often be ascertained from their medical histories.

Classification

The classification of medial knee injuries is primarily based on the amount of medial compartment gapping present with an applied valgus stress during the clinical examination or a valgus stress radiograph, performed or taken at 20° of knee flexion. The American Medical Association's grading scale is most commonly utilized to classify the severity of injuries.[3] It is important to recognize that this is a subjective grading scale based on the perceived amount of gapping that occurs when a clinician performs a valgus stress maneuver on the patient.

In general, a grade I tear presents with localized pain along the medial knee structures and no significant medial compartment gapping. An isolated grade II medial knee injury also presents with localized pain along the medial knee structures, but also demonstrates significant gapping with a definite end point present. A grade III, or complete, medial knee injury is present when there is no defined end point after application of a valgus stress at 20° of knee flexion. Historically, the gap sizes corresponding with grade I, II, and III injuries have been reported to be 0 to 5 mm, 6 to 10 mm, and greater than 10 mm, respectively, compared to the uninjured contralateral knee.[1,10,15,21,22] However, it is important to recognize that studies published after the American Medical Association guidelines were initially proposed have demonstrated that the actual amounts of medial compartment gaps corresponding to grade I, II, and III injuries, when measured objectively against the contralateral knee, are much smaller than the historically accepted values quoted above (**TABLE**).

Clinical Examination

Physical examination of acute medial knee injuries can be very accurate at identifying the location and grade of instability. Conversely, the examination of chronic medial knee injuries can often be clinically challenging and requires more objective means of measuring instability, such as stress radiographs. As part of the initial examination, inspection of the knee for any signs of abrasions, lacerations, contusions, or localized edema should be performed.[14] In addition, palpation of the meniscofemoral and meniscotibial divisions of the medial knee structures along their entire lengths can also be very useful to identify the injury location. This is important because differences in healing potential between meniscofemoral and meniscotibial medial knee injuries have been reported.[6]

Valgus stress loads applied to the knee at full extension or at 20° of knee flexion can help estimate the amount of medial compartment gapping (**FIGURE 7**). For an isolated grade III medial knee injury, a

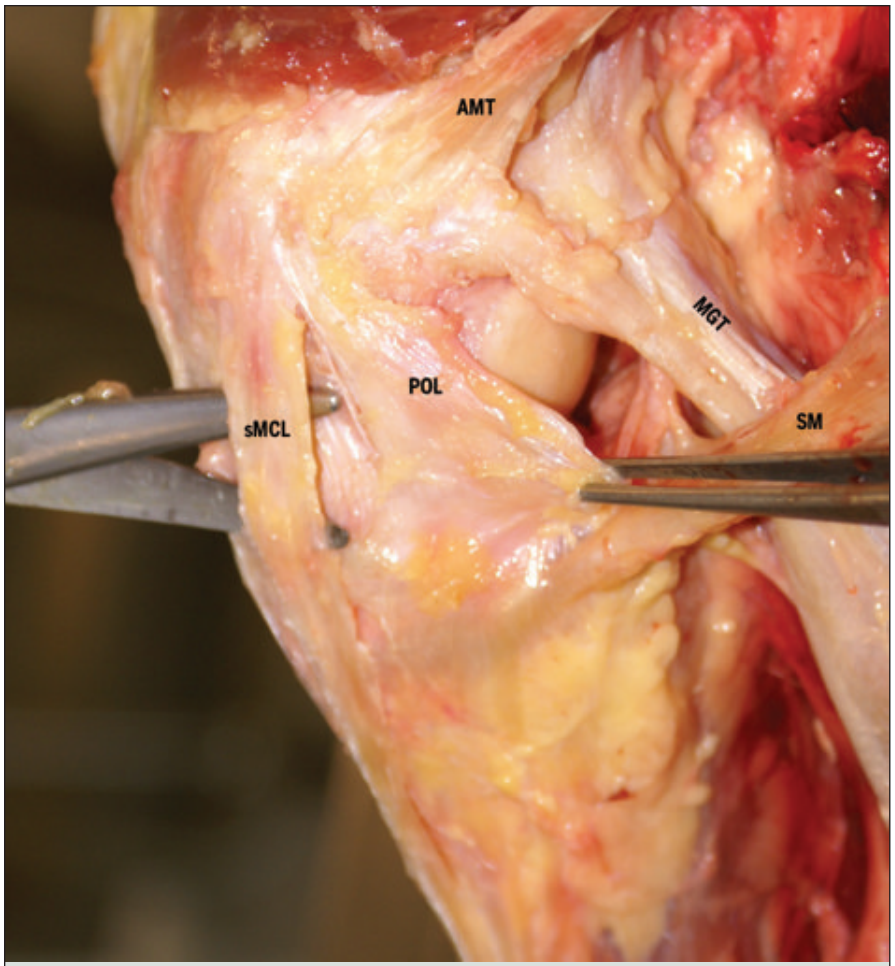

FIGURE 4. Photograph of a right knee demonstrating the central arm of the posterior oblique ligament. Abbreviations: AMT, adductor magnus tendon; MGT, medial gastrocnemius tendon; POL, posterior oblique ligament; SM, semimembranosus tendon; sMCL, superficial medial collateral ligament.

valgus stress test performed with the knee at full extension should demonstrate only 1 to 2 mm of increased medial compartment gapping compared to the contralateral side; more gapping would indicate a combined cruciate ligament injury.[7] Increased valgus gapping in extension is usually an indication of a more severe combined medial knee and cruciate ligament injury. Assessment of the amount of medial compartment gapping at 20° of knee flexion predominantly isolates the superficial MCL, with the roles of the cruciate ligaments, deep MCL, and posterior oblique ligament being less important. Feeling for an end point during this test is important to differentiate between a partial and complete medial knee injury.[7]

Assessment of the amount of anteromedial rotation in a medial knee injury is also important to determine whether the injury primarily affects the superficial MCL or the posterior oblique ligament and deep MCL. The anteromedial drawer test is performed with the knee flexed approximately 80° to 90° and the foot externally rotated 10° to 15°. A coupled anterior and external rotatory force is applied to the knee, and the amount of anteromedial tibial rotation is assessed. It is important to visually assess the amount of anteromedial tibial rotation, rather than posterolateral tibial rotation, because the amount of external tibial rotation that occurs is very similar to that demonstrated during a positive posterolateral drawer test.

The dial test should be performed at both 30° and 90° of knee flexion to evaluate suspected medial knee injuries (**FIGURE 8**).[7,9] In the past, a positive dial test was reported to be pathognomonic of a posterolateral corner injury, but biomechanical testing has demonstrated that a positive dial test can also be present at both 30° and 90° of knee flexion in an isolated medial knee injury.[7] Thus it is important to examine these patients both in the supine and prone positions when performing the dial test to determine whether the amount of external rotation is due to anteromedial or posterolateral tibial rotation. When the dial test is performed in the prone position, it can more accurately allow for objective visualization of the amount of increased side-to-side external rotation; however, palpation and visualization of actual tibial subluxation must be performed in the supine position.

Radiographic Diagnosis

Valgus stress radiographs are very useful to objectively identify a medial knee injury. These radiographs are usually performed at 20° of knee flexion with a foam bolster under the knee, and a comparison is made between the amounts of medial compartment gapping in the injured and uninjured contralateral knee (**FIGURE 9**). It has been reported that a grade III injury to the superficial MCL results in 3.2 mm of increased medial compartment gapping at 20° of knee flexion.[13] Complete sectioning of the superficial MCL, posterior oblique ligament, and deep MCL resulted in 9.8 mm of increased medial compartment gapping at 20° of knee flexion.[13] Thus, valgus stress radiographs can be a valuable adjunct to the clinical examination by quantifying the amount of medial compartment gapping in a medial knee injury and, when the diagnosis is in doubt, determining whether the side-to-side gapping present in a chronic knee injury is due to either a medial or posterolateral injury.

Magnetic resonance imaging (MRI) is also useful to diagnose injuries to the medial knee structures and demonstrate the location of damaged structures. Coro-

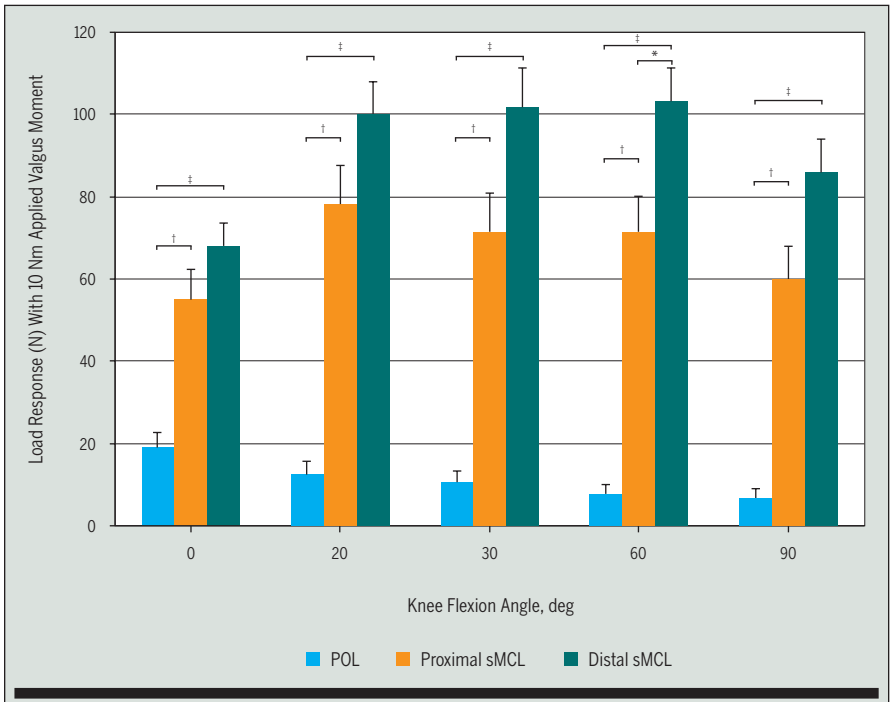

FIGURE 5. Forces measured for the posterior oblique ligament (POL) and the proximal and distal superficial medial collateral ligament (sMCL) divisions during application of a 10-Nm valgus load. Statistically significant differences between structures are indicated. *$P<.05$, †$P<.001$, ‡$P<.0001$. Error bars indicate the standard error of the mean. Reprinted with permission from Griffith et al.[8]

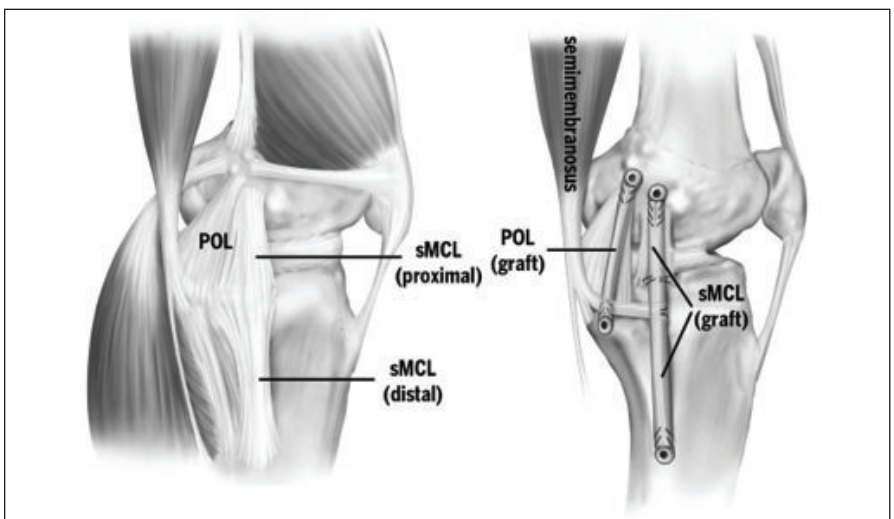

FIGURE 6. Illustration of a medial knee reconstruction procedure demonstrating the reconstructed superficial medial collateral ligament (sMCL) and posterior oblique ligament (POL) using 2 separate grafts with 4 reconstruction tunnels. Note that the proximal tibial attachment point of the sMCL, which is primarily attached to soft tissues and located just distal to the joint line, was re-created by suturing the sMCL graft to the anterior arm of the semimembranosus muscle (medial view, left knee). Reprinted with permission from Coobs et al.[4]

nal MRI sequences are especially useful in assessing acute medial knee injuries (**FIGURE 10**). The diagnosis of medial knee injuries via MRI scans has been reported to have an accuracy of 87%.[28] In addition, it has been reported that lateral compartment bone bruises, due to either the impact or the stress placed on the lateral compartment when the medial ligamentous structures tear, were present in 45% of isolated medial knee injuries.[18]

Diagnostic Challenges of Medial Knee Injuries

Although acute medial knee injuries do not pose a significant diagnostic challenge due to the localized pain that occurs, it is not uncommon for chronic medial knee injuries to masquerade as posterolateral corner injuries. It can be difficult, on clinical examination, to differentiate between an increase in medial or lateral compartment gapping when one assesses the toggle, which can be seen in a chronic medial knee injury when performing valgus and varus stress tests at 20° of knee flexion. Comparing the side-to-side differences between the injured knee and uninjured contralateral knee on valgus and varus stress tests can help determine whether the difference in gapping is in the medial or lateral compartment. When the results of the physical examination are in doubt, which is not uncommon with chronic medial knee injuries, bilateral valgus and varus stress radiographs can be obtained to objectively determine whether a chronic medial or posterolateral corner injury exists. This is an important concept to understand. Because of the general belief that most medial knee injuries heal over time, clinicians may fail to consider the possibility of a chronic medial knee injury and misinterpret abnormal motion to be due to a chronic posterolateral knee injury. Because medial knee injuries comprise the largest number of total knee ligament injuries, the number of injuries that do not heal can still result in a significant number of patients with chronic instability and ongoing functional limitations.

In addition to the difficulty in discerning whether a side-to-side toggle observed during valgus and varus stress tests is due to a medial or lateral knee injury, chronic medial knee injuries also present with increased external rotation, which is often interpreted as evidence of a posterolateral corner injury. It is not

TABLE Grading Scales for Medial Knee Injuries

Classification	Definition
Grade I	Tenderness, no instability
Grade II	Broad tenderness, partially torn medial knee structures
Grade III	Complete medial knee disruption, no end point to an applied valgus stress at 20° of knee flexion
Radiographic stress classification	
Isolated complete sMCL tear	>1.7 mm of gapping at 0° of knee flexion; >3.2 mm of gapping at 20° of knee flexion
Complete tear of medial knee structures (sMCL, POL, dMCL)	>6.5 mm of gapping at 0° of knee flexion; >9.8 mm of gapping at 20° of knee flexion

Abbreviations: dMCL, deep medial collateral ligament; POL, posterior oblique ligament; sMCL, superficial medial collateral ligament

uncommon in the senior author's (R.F.L.) practice to treat patients who have a chronic medial knee injury and were referred because of suspicion of a chronic posterolateral corner injury. Thus, it is important to assess differences between anteromedial and posterolateral rotation on anteromedial and posterolateral drawer tests. In addition, the dial test at both 30° and 90° of knee flexion must be correctly interpreted to distinguish between a posterolateral corner injury and a chronic medial knee injury.

TREATMENT OF GRADE III MEDIAL KNEE INJURIES

Nonoperative Treatment

The decision regarding how to treat acute grade III medial knee injuries depends on whether the injury is isolated or combined with other knee ligament injuries. When there is a combined medial knee injury and anterior cruciate ligament (ACL) injury, there is a different treatment algorithm than that for medial knee injuries combined with posterior cruciate ligament or other knee ligament injuries.

For isolated, acute grade III medial knee injuries, nonoperative treatments are typically recommended. Rehabilitation programs focus on restoring quadriceps function, improving knee range of motion, and controlling knee edema.[26] Although several different knee rehabilitation protocols have been proposed to treat isolated, acute medial knee injuries, all of them generally have the same satisfactory outcome.[2,11,12,16,23] A rehabilitation program focusing on the above goals via the use of a stationary bike and other exercises that do not involve side-to-side activities results in healing of grade III medial injuries in the majority of circumstances. In general, most athletes can return to full competition, following a well-guided rehabilitation program, 5 to 7 weeks after injury on average.[26]

When a grade III medial knee injury is combined with an ACL tear, the general protocol is to rehabilitate the medial knee injury first, allowing it to heal according to the guidelines for isolated medial knee injuries, and then to reconstruct the ACL 5 to 7 weeks after injury, once there is good clinical and/or objective evidence of healing of the medial knee injury.[26]

There is currently no consensus regarding whether a hinged knee brace is necessary to treat grade III medial knee injuries. In general, it is believed that meniscofemoral medial knee injuries diagnosed clinically and/or from MRI scans have a high likelihood of healing,[5,6] and not all sports medicine centers treat these injuries with a hinged knee brace. However, meniscotibial lesions do have a higher reported incidence of healing,[6] and the majority of centers will treat patients with a grade III meniscotibial medial knee injury with a hinged knee brace. Typically, the protocol involves using the brace during the early phases of rehabilitation, then either continuing to use the

FIGURE 7. Photograph of a valgus stress being applied to the right knee at 20° of knee flexion. The tester's fingers are placed directly over the joint line to measure the amount of medial compartment gapping, while a coupled valgus force is applied to the knee at the foot and ankle.

FIGURE 8. Patient with an isolated, chronic grade III medial knee injury to the right knee. A positive dial test at 90° of knee flexion is seen for the right knee.

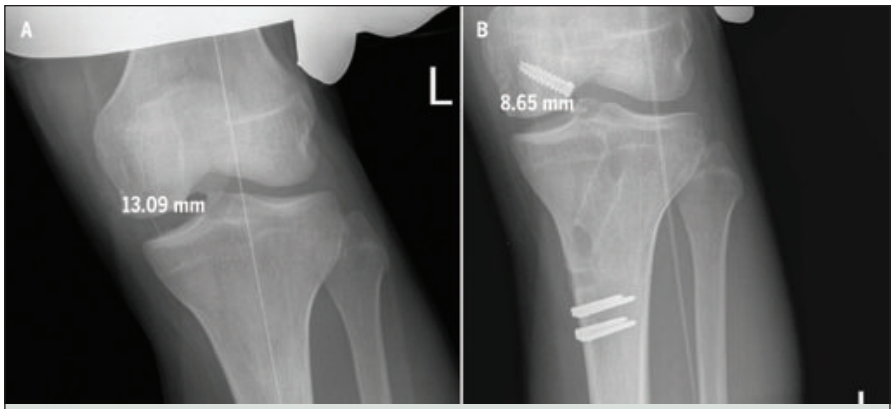

FIGURE 9. Preoperative (A) and postoperative (B) valgus stress radiographs (left knee).

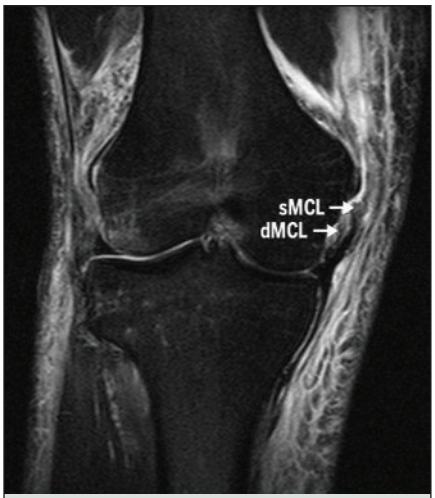

FIGURE 10. Proton-density-weighted magnetic resonance imaging coronal view demonstrating an avulsion fracture of the femoral attachment of the superficial medial collateral ligament (sMCL) and meniscofemoral portion of the deep medial collateral ligament (dMCL, right knee).

brace through the ongoing competitive season or discontinuing use 8 to 12 weeks after injury.

Operative Treatment

The indications for operative treatment are different for acute and chronic grade III medial knee injuries. In an acute injury, surgery is often indicated with multiligament injuries or knee dislocations involving the MCL. In such circumstances, direct repair of the injured structures with sutures, augmentation of the repair with a hamstring graft, or acute reconstruction with an autograft or allograft replacement of the superficial MCL and posterior oblique ligament may be indicated. In these surgical circumstances, there is a greater risk of patients developing arthrofibrosis or heterotopic bone formation, known as Pellegrini-Stieda disease. Consequently, postoperative rehabilitation principles should be followed within the guidelines of the "safe zone," the range of motion that is intraoperatively measured by the surgeon and during which knee motion can be achieved with no significant tension on the repaired structures. This safe zone of postoperative knee motion will vary between patients, and it is important for this information to be communicated to all members of the healthcare team.

In patients who present with chronic grade III medial knee injuries, surgery is indicated for patients who have complaints of rotatory instability and/or concurrent side-to-side instability. It is also important for patients with chronic medial knee injuries to assess their weight-bearing frontal plane knee alignment. For patients who have a valgus alignment, a first-stage osteotomy with a concurrent distal femoral osteotomy is indicated to shift the weight-bearing axis to the center of the knee (**FIGURE 11**), because it is believed that any soft tissue graft would have a greater risk of stretching out if the alignment was not corrected first. For those who undergo a distal femoral osteotomy first (usually cases with chronic multiligament injuries), it is important to rehabilitate patients for several months after the osteotomy heals to verify whether they are still having functional limitations. In patients whose osteotomy has healed and who still have functional limitations after rehabilitation, or in patients who have a genu varus or neutral alignment, surgical reconstruction is indicated. Direct suture repairs of chronic medial knee injuries are generally not recommended because of a higher risk of having these repairs stretch out over time. The goals of a postoperative rehabilitation program in chronic cases are similar to those for acute cases, in that an early range-of-motion protocol to prevent postsurgical arthrofibrosis is indicated.

Our preferred technique for the treatment of severe acute or chronic medial knee injuries is a reconstruction of both divisions of the superficial MCL and the posterior oblique ligament. Two separate grafts with 4 separate graft tunnels are utilized in this technique, which has been biomechanically validated and found to restore the native distribution of forces to applied loads on the reconstructed ligaments.[4] In this technique, the superficial MCL reconstruction graft is fixed into a femoral-based tunnel at the anatomic attachment site of the superficial MCL, and is then fixed distally in a closed-socket tibial tunnel approximately 6 cm distal to the tibial joint line. This is the location of the native attachment site of the superficial MCL on the distal tibia. In addition, a suture anchor is placed at the proximal tibial attachment site of the superficial MCL to replicate the anatomy and strength of the normal soft tissue proximal tibial attachment of the superficial MCL. The posterior oblique ligament is reconstructed using a graft that is fixed into femoral and tibial tunnels made at the anatomic attachment sites of the original structure. Because the posterior oblique ligament is tightest in extension, the graft is tightened with the knee extended and in neutral rotation. The superficial MCL graft is tightened at 20° of knee flexion and with the knee in neutral rotation. An early range-of-motion and quadriceps reactivation program is recommended with this reconstruction technique.

FIGURE 11. Anteroposterior radiograph of the left knee 4 months after concurrent distal femoral osteotomy, medial knee reconstruction, double-bundle posterior cruciate ligament reconstruction, and endoscopic anterior cruciate ligament reconstruction.

REHABILITATION OF ACUTE GRADE III MEDIAL KNEE INJURIES

Nonoperative Rehabilitation Principles

As mentioned previously, the majority of nonoperatively treated grade III medial knee injuries are either isolated injuries combined solely with an ACL tear. The overall rehabilitation principles are to control edema and initiate quadriceps reactivation in the initial hours to days after injury, and then to work to restore knee range of motion. Early weight bearing is encouraged, with patients increasing their weight bearing as tolerated and progressively reducing their dependence on crutches until they can ambulate without a limp. As soon as patients can tolerate it, they are encouraged to ride a stationary bike to improve range of motion. It is believed that the range-of-motion exercise a patient achieves on a stationary bike is similar to the healing stimulus that has been found in animals with the use of a constant passive motion device, resulting in accelerated healing of grade III MCL injuries. Athletes are required to work on a range-of-motion program on a stationary bike as soon as they can tolerate it. The amount of time and effort on the stationary bike is increased as tolerated. In general, one should avoid applying any significant stresses to the healing structures during the clinical examination and side-to-side activities until 3 to 4 weeks after injury to ensure that the grade III medial knee injury can heal properly.[26] Once the clinical examination demonstrates healing, balance and proprioceptive activities can commence. The general goal is to have an athlete return to full activities or have healed the medial knee injury sufficiently to proceed with an ACL reconstruction within 5 to 7 weeks after injury.[26] Obviously, every patient is different, and the application of these principles should be guided by the goals of restoring full range of motion, ensuring quadriceps reactivation, and demonstrating clinical and/or objective evidence of healing of the grade III MCL injury when applying a valgus stress at 20° of knee flexion (**APPENDIX A**).

Postoperative Rehabilitation

It is important to stress that a safe zone for range of motion, determined intraoperatively by the surgeon, is communicated to the rehabilitation specialist to ensure that the appropriate knee range of motion can be safely achieved immediately after a medial knee repair or reconstruction. Ideally, we strive for a passive or passive-assisted range of motion from 0° to 90° of knee flexion immediately after surgery to minimize the risk of arthrofibrosis. In addition, an aggressive patellofemoral mobilization program, quadriceps reactivation, and the frequent performance of ankle pumps are encouraged. The initial postoperative protocol encourages edema control via compression and cryotherapy, as well as reactivation of the quadriceps. Patients are non–weight bearing to touch-down weight bearing for the first 6 weeks after surgery. For the first 2 weeks after the reconstruction, gentle, passive range-of-motion exercises are performed within the limits of what the patient can tolerate. Ideally, the goal is to achieve 90° of knee flexion 2 weeks after surgery to minimize the development of adhesions. Quadriceps setting exercises, straight leg raises in a knee brace, and hip extension and abduction exercises are encouraged immediately after surgery (**APPENDIX B**).

Two weeks after surgery, range of motion is increased as tolerated. The goal is to have the patient achieve at least 130° of knee flexion 6 weeks after surgery. After 6 weeks of protected weight bearing, closed-kinetic-chain exercises are permitted for functional rehabilitation. The use of a stationary bike with light resistance is encouraged, and resistance is increased over time as tolerated. Double-leg presses to a maximum of 70° of knee flexion are also performed, with flexion past 70° discouraged to minimize excessive joint motion.

Once the patient is bearing full weight, restoration of normal gait mechanics is emphasized. It is important for the patient to ambulate without a limp and ensure that effusions do not develop with increasing activities. A persistent effusion can contribute to decreased knee flexion, quadriceps muscle shutdown, and increased joint pain.

Provided that lower extremity strength, motion, and balance have been appropriately regained, basic plyometric and agility exercises may be initiated 16 weeks after surgery. In addition, the patient should be able to tolerate 2 to 3 km of brisk ambulation without limping prior to initiating an interval jogging program. Once the patient has progressed without significant functional limitations, an assessment can be made regarding a return to full activities via sport-specific functional tests and evaluations of objective

knee stability on clinical examination and from stress radiographs.

It is important to recognize that the presence of concurrent cruciate ligament primary or revision reconstructions or osteotomies may require altering the progression of this rehabilitation program to allow for further healing of biologic tissues related to an osteotomy or concurrent cruciate ligament reconstruction. Thus, it is recommended that the rehabilitation specialists work closely with the treating surgeon to verify that the patient progresses appropriately in the postoperative rehabilitation program.

CONCLUSIONS

The superficial MCL, deep MCL, and posterior oblique ligament must be clinically and objectively evaluated for instability in any patient with a medial knee injury. Although most acute medial knee injuries that occur in isolation or with an ACL tear heal without surgery, those that occur with a concurrent grade III posterior cruciate ligament tear or other multiligament knee injury often do not heal, and early surgical treatment may be indicated for those cases. In addition, it is important to recognize that not all isolated grade III medial knee injuries heal properly, and therefore some patients will still have functional limitations after these injuries. For chronic injuries, it is important to assess frontal knee alignment and verify that patients do not have a grade III posterolateral knee injury. If operative treatment is indicated for these chronic injuries, an anatomic reconstruction is recommended. ◉

REFERENCES

1. Bahk MS, Cosgarea AJ. Physical examination and imaging of the lateral collateral ligament and posterolateral corner of the knee. *Sports Med Arthrosc*. 2006;14:12-19.
2. Ballmer PM, Jakob RP. The non-operative treatment of isolated complete tears of the medial collateral ligament of the knee. A prospective study. *Arch Orthop Trauma Surg*. 1988;107:273-276.
3. Committee on the Medical Aspects of Sports. *Standard Nomenclature of Athletic Injuries*. Chicago, IL: American Medical Association; 1966.
4. Coobs BR, Wijdicks CA, Armitage BM, et al. An in vitro analysis of an anatomical medial knee reconstruction. *Am J Sports Med*. 2010;38:339-347. http://dx.doi.org/10.1177/0363546509347996
5. DeLee JC, Drez D, Jr., Miller MD. *DeLee & Drez's Orthopaedic Sports Medicine: Principles and Practice*. Philadelphia, PA: Saunders; 2003.
6. Frank CB, Loitz BJ, Shrive NG. Injury location affects ligament healing. A morphologic and mechanical study of the healing rabbit medial collateral ligament. *Acta Orthop Scand*. 1995;66:455-462.
7. Griffith CJ, LaPrade RF, Johansen S, Armitage B, Wijdicks C, Engebretsen L. Medial knee injury: part 1, static function of the individual components of the main medial knee structures. *Am J Sports Med*. 2009;37:1762-1770. http://dx.doi.org/10.1177/0363546509333852
8. Griffith CJ, Wijdicks CA, LaPrade RF, Armitage BM, Johansen S, Engebretsen L. Force measurements on the posterior oblique ligament and superficial medial collateral ligament proximal and distal divisions to applied loads. *Am J Sports Med*. 2009;37:140-148. http://dx.doi.org/10.1177/0363546508322890
9. Grood ES, Stowers SF, Noyes FR. Limits of movement in the human knee. Effect of sectioning the posterior cruciate ligament and posterolateral structures. *J Bone Joint Surg Am*. 1988;70:88-97.
10. Hughston JC. Acute knee injuries in athletes. *Clin Orthop*. 1962;23:114-133.
11. Hughston JC. The importance of the posterior oblique ligament in repairs of acute tears of the medial ligaments in knees with and without an associated rupture of the anterior cruciate ligament. Results of long-term follow-up. *J Bone Joint Surg Am*. 1994;76:1328-1344.
12. Hughston JC, Eilers AF. The role of the posterior oblique ligament in repairs of acute medial (collateral) ligament tears of the knee. *J Bone Joint Surg Am*. 1973;55:923-940.
13. LaPrade RF, Bernhardson AS, Griffith CJ, Macalena JA, Wijdicks CA. Correlation of valgus stress radiographs with medial knee ligament injuries: an in vitro biomechanical study. *Am J Sports Med*. 2010;38:330-338. http://dx.doi.org/10.1177/0363546509349347
14. LaPrade RF, Engebretsen AH, Ly TV, Johansen S, Wentorf FA, Engebretsen L. The anatomy of the medial part of the knee. *J Bone Joint Surg Am*. 2007;89:2000-2010. http://dx.doi.org/10.2106/JBJS.F.01176
15. LaPrade RF, Terry GC. Injuries to the posterolateral aspect of the knee. Association of anatomic injury patterns with clinical instability. *Am J Sports Med*. 1997;25:433-438.
16. Lind M, Jakobsen BW, Lund B, Hansen MS, Abdallah O, Christiansen SE. Anatomical reconstruction of the medial collateral ligament and posteromedial corner of the knee in patients with chronic medial collateral ligament instability. *Am J Sports Med*. 2009;37:1116-1122. http://dx.doi.org/10.1177/0363546509332498
17. Lorentzon R, Wedren H, Pietila T. Incidence, nature, and causes of ice hockey injuries. A three-year prospective study of a Swedish elite ice hockey team. *Am J Sports Med*. 1988;16:392-396.
18. Miller MD, Osborne JR, Gordon WT, Hinkin DT, Brinker MR. The natural history of bone bruises. A prospective study of magnetic resonance imaging-detected trabecular microfractures in patients with isolated medial collateral ligament injuries. *Am J Sports Med*. 1998;26:15-19.
19. Pedowitz RA, O'Connor JJ, Akeson WH. *Daniel's Knee Injuries: Ligament and Cartilage Structure, Function, Injury, and Repair*. 2nd ed. Philadelphia, PA: Lippincott Williams & Wilkins; 2003.
20. Peterson L, Junge A, Chomiak J, Graf-Baumann T, Dvorak J. Incidence of football injuries and complaints in different age groups and skill-level groups. *Am J Sports Med*. 2000;28:S51-57.
21. Phisitkul P, James SL, Wolf BR, Amendola A. MCL injuries of the knee: current concepts review. *Iowa Orthop J*. 2006;26:77-90.
22. Quarles JD, Hosey RG. Medial and lateral collateral injuries: prognosis and treatment. *Prim Care*. 2004;31:957-975. http://dx.doi.org/10.1016/j.pop.2004.07.005
23. Reider B, Sathy MR, Talkington J, Blyznak N, Kollias S. Treatment of isolated medial collateral ligament injuries in athletes with early functional rehabilitation. A five-year follow-up study. *Am J Sports Med*. 1994;22:470-477.
24. Robinson JR, Bull AM, Thomas RR, Amis AA. The role of the medial collateral ligament and posteromedial capsule in controlling knee laxity. *Am J Sports Med*. 2006;34:1815-1823. http://dx.doi.org/10.1177/0363546506289433
25. Warme WJ, Feagin JA, Jr., King P, Lambert KL, Cunningham RR. Ski injury statistics, 1982 to 1993, Jackson Hole Ski Resort. *Am J Sports Med*. 1995;23:597-600.
26. Wijdicks CA, Griffith CJ, Johansen S, Engebretsen L, LaPrade RF. Injuries to the medial collateral ligament and associated medial structures of the knee. *J Bone Joint Surg Am*. 2010;92:1266-1280. http://dx.doi.org/10.2106/JBJS.I.01229
27. Wijdicks CA, Griffith CJ, LaPrade RF, et al. Medial knee injury: part 2, load sharing between the posterior oblique ligament and superficial medial collateral ligament. *Am J Sports Med*. 2009;37:1771-1776. http://dx.doi.org/10.1177/0363546509335191
28. Yao L, Dungan D, Seeger LL. MR imaging of tibial collateral ligament injury: comparison with clinical examination. *Skeletal Radiol*. 1994;23:521-524.

APPENDIX A

NONOPERATIVE TREATMENT OF ACUTE GRADE III MEDIAL KNEE INJURIES

Goals for All Phases
- Early, pain-free full range of motion of the knee
- Minimal loss of quadriceps strength
- Healing of injured ligament complex with little to no residual instability

Phase 1: 1 to 2 Weeks

Ice:
- Ice knee as tolerated and as needed based on symptoms

Weight bearing:
- Use crutches and apply touchdown to partial weight bearing and progress as tolerated. Progress to 1 crutch (on opposite side), then discontinue crutches only when normal gait is possible

Brace:
- Hinged knee brace set from 0° to 90° of knee flexion

Range of motion:
- Emphasize full extension
- Progress flexion as tolerated

Therapeutic exercises:
- Quadriceps sets: 30 repetitions, 10 times a day
- Straight leg raises. No weights. The knee must be held in full extension (no sag). If not, exercise is performed with brace locked in full extension
- Range-of-motion exercises as tolerated
- Sitting hip flexion, 10 sets of 10 repetitions daily
- Sidelying hip abduction, 10 sets of 10 repetitions daily
- Standing hip extension, 10 sets of 10 repetitions daily
- Standing hamstring curls, as tolerated; if painful, discontinue
- Bike, as comfortable, 10 to 20 minutes, low resistance, start as soon as possible
- No limits on upper extremity workouts that do not affect the injured knee

Phase 2: 3 to 4 Weeks

Weight bearing:
- As tolerated with hinged brace

Range of motion:
- Full extension
- Progressive flexion as tolerated

Therapeutic exercises:
- Progress above exercises as tolerated to 5 to 10 lb (2-4 kg)
- Progress to 20 minutes of exercise biking daily; increase resistance as tolerated. This is the key exercise to promote healing, rebuild strength, and maintain aerobic conditioning
- Progress to weight-room exercises. Limit the injured knee's range of motion to between 0° and 90° of knee flexion when lifting weights (in the brace)
- Hamstring curls
- Leg presses: double-leg press and single-leg press on injured side
- Progress isokinetics
- Step-ups

Precaution:
- Examination by physician is necessary at approximately 3 weeks to verify ligament healing

Phase 3: 5 Weeks

Weight bearing:
- Gait in hinged knee brace through 6 weeks, as comfortable

Brace:
- Gradually open fully per quadriceps control
- Discontinue use when ambulating with full weight bearing and no gait deviation

Range of motion:
- Full, symmetrical

Therapeutic exercises:
- Continue at least 20 minutes of daily exercise bike program. Resistance should be progressively increased at each session
- Progress to weight-room exercises. Limit motion to 30° to 90° of knee flexion while performing leg presses, squats, etc
- Hamstring curls
- Leg presses: double-leg press and single-leg press
- Progress isokinetics
- Step-ups
- Progress walk-to-run, as tolerated, once cleared by surgeon
- Progress agilities from balanced to unilateral exercises (single-leg hopscotch jumps, etc)

Precautions:
- Verify healing by physician at 5 to 6 weeks to progress to next level
- Verify with stress radiographs as needed

Phase 4: 6 Weeks

Brace:
- Discontinue brace with gait, wear for competition through competitive season or for at least 3 months
- Protective use when out of home, hinged brace open per quadriceps control

Range of motion:
- Full, symmetrical

Therapeutic exercises:
- Continue daily exercise bike use through 12 weeks after injury (at least 20 minutes per day)
- Progress sport-specific exercises

Precaution:
- Return to competition once full motion and strength return and the patient passes a sport functional test and is cleared by the physician

APPENDIX B

POSTOPERATIVE REHABILITATION PRINCIPLES FOR ANATOMIC MEDIAL KNEE RECONSTRUCTION

Phase 1: 0 to 2 Weeks

Goals
- Control effusion and pain
- Flexion range of motion (within safe zone) to 90° of knee flexion
- Maintain full extension
- Reactivate quadriceps muscle
- Straight leg raises with no knee extension lag
- Patellofemoral mobility

Weight bearing:
- Non–weight bearing

Brace:
- Wear brace at full extension at all times, except for passive motion for therapy

Range of motion:
- Emphasize full extension
- Knee flexion from 0° to 90°

Therapeutic exercises:
- Cryotherapy for edema control
- Range-of-motion exercises
- Quadriceps and hamstring strengthening

Precaution:
- Avoid valgus and internal and external rotation through the knee joint

Phase 2: 2 to 6 Weeks

Goals
- Effusion resolved
- Knee flexion range of motion ⩾115°
- Preserve full knee extension
- Quadriceps and straight leg raises with no extension lag

Weight bearing:
- Non–weight bearing

Brace:
- Wear brace when up and about and while sleeping
- Hinged brace open into flexion per quadriceps functional control

Range of motion:
- Full extension
- Progressive flexion as tolerated

Therapeutic exercises:
- Continue per phase 1
- Initiate upright stationary bike at week 4 with no resistance
- Progress to intermediate core and proximal hip strengthening exercises
- Initiate prone or standing hamstring curls (active flexion, passive extension)

Precaution:
- Continue to avoid valgus and internal and external rotation strain through the knee joint

Phase 3: 6 to 8 Weeks

Goals
- Range of motion with no knee extension lag
- Quadriceps girth returning
- Normal gait mechanics performed

Weight bearing:
- As tolerated with bilateral crutches
- Progress to full weight bearing per quadriceps control with no gait deviation

Brace:
- Gradually open fully per quadriceps control
- Discontinue use when ambulating with full weight bearing and no gait deviation

Range of motion:
- Full, symmetrical

Therapeutic exercises:
- Initiate closed-kinetic-chain strengthening in bilateral support (⩽70° of knee flexion)
- Continue to progress to intermediate core and proximal hip strengthening exercises
- Initiate basic lower extremity proprioception and balance drills with bilateral support

Precautions:
- Limit bilateral squats to ⩽70° of knee flexion
- No pivoting on a planted foot
- Observe and correct for knee/hip alignment with closed-kinetic-chain drills
- Observe for continued effusion, pain with weight bearing, and home exercise program progression

Phase 4: 8 to 12 Weeks

Goals
- Restore normal gait mechanics with closed-kinetic-chain lower extremity activities
- Resume normal stair climbing
- Normalization of walking speed and distance
- Able to perform single-leg squat ⩾45° of knee flexion with normal mechanics

Weight bearing:
- Full weight bearing, no restrictions

Brace:
- Protective use for dynamic activities when out of home, hinged brace open per quadriceps control

Range of motion:
- Full, symmetrical

Therapeutic exercises:
- Progress closed-kinetic-chain strength drills to single-leg

APPENDIX B

- Progress lower extremity proprioception and balance drills to single-leg
- Initiate light cardiovascular exercise with bike
- Add bilateral support for large muscle group weight training

Precautions:

- Continue to observe for proper lower extremity alignment and mechanics with closed-kinetic-chain exercise
- No use of knee extension machine

Phase 5: 12 to 16 Weeks

Goal

- Able to perform single-leg squat ⩾60° of knee flexion with normal mechanics

Weight bearing:

- Full weight bearing, no restrictions

Brace:

- No brace

Range of motion:

- Full, symmetrical

Therapeutic exercises:

- Continue per phase 4
- Progress cardiovascular activity with bike, elliptical, walking, and flutter-kick swimming
- Progress weight training to single-leg
- Progress lower extremity proprioception and balance drills with surface challenge: BOSU (BOSU, Canton, OH), Airex (Airex AG, Sins, Switzerland), and DynaDisc (Exertools Inc, Petaluma, CA)

Precautions:

- Patient demonstrates good control in concentric and eccentric phases with weight-training exercises
- Able to preserve proper lower extremity alignment with proprioception, balance, and closed-kinetic-chain drills

Phase 6: 16 to 20 Weeks

Goal

- Patient demonstrates good self-awareness of proper lower extremity alignment with closed-kinetic-chain and impact drills

Weight bearing:

- Full weight bearing, no restrictions

Brace:

- No brace except for dynamic activities

Range of motion:

- Full, symmetrical

Therapeutic exercises:

- Directional lunging
- Interval jogging (straight line, no hills)
- Initiate basic agility/footwork drills
- Initiate basic double-leg plyometric drills
- Dynamic and directional challenge to lower extremity proprioception and balance drills

Precautions:

- Continue to observe for proper lower extremity alignment and mechanics with closed kinetic chain
- Observe for continued effusion and pain control with initiation of impact activity

Phase 7: 20+ Weeks

Goals

- Patient to become independent with exercise program and demonstrate good self-awareness of proper lower extremity alignment during high-level drills
- Return to sport once strength returns and clinical/objective stability is verified

Weight bearing:

- Full weight bearing, no restrictions

Brace:

- No brace except for sports

Range of motion:

- Full, symmetrical

Therapeutic exercises:

- Continue with weight-room strength training
- Progress plyometric drills
- Progress speed/intensity of agility drills
- Initiate acceleration/deceleration drills
- Initiate cutting drills
- Initiate sport-specific drills

Precaution:

- Avoid functional valgus at knee with deceleration, cutting, and jumping drills